

1-1-2007

An Unusual Presentation of Extrapulmonary Tuberculosis in an Adolescent: Isolated Unilateral Inguinal Lymphadenitis

EKREM GÜLER

SELMA GÜLER

HASAN UÇMAK

CANAN EREN DAĞLI

MEHMET DAVUTOĞLU

Follow this and additional works at: <https://journals.tubitak.gov.tr/medical>



Part of the [Medical Sciences Commons](#)

Recommended Citation

GÜLER, EKREM; GÜLER, SELMA; UÇMAK, HASAN; DAĞLI, CANAN EREN; and DAVUTOĞLU, MEHMET (2007) "An Unusual Presentation of Extrapulmonary Tuberculosis in an Adolescent: Isolated Unilateral Inguinal Lymphadenitis," *Turkish Journal of Medical Sciences*: Vol. 37: No. 6, Article 11. Available at: <https://journals.tubitak.gov.tr/medical/vol37/iss6/11>

This Article is brought to you for free and open access by TÜBİTAK Academic Journals. It has been accepted for inclusion in Turkish Journal of Medical Sciences by an authorized editor of TÜBİTAK Academic Journals. For more information, please contact academic.publications@tubitak.gov.tr.

An Unusual Presentation of Extrapulmonary Tuberculosis in an Adolescent: Isolated Unilateral Inguinal Lymphadenitis

Ekrem GÜLER¹
Selma GÜLER²
Hasan UÇMAK³
Canan EREN DAĞLI⁴
Mehmet DAVUTOĞLU¹

Abstract: Isolated tuberculous inguinal lymphadenitis is a rare entity and is usually bilateral. A 16-year-old male presented with anorexia, nocturnal sweating and painless soft right inguinal lymph nodes. The patient underwent excision of lymph nodes and a Ziehl-Neelsen stain revealed the presence of acid-fast bacilli, but cultures of the lymph nodes were negative. Histological sections showed the presence of caseous necrosis and epithelioid cell granuloma. He had a positive tuberculin skin test (Mantoux) with 22 mm diameter. The patient was diagnosed as tuberculous lymphadenitis with these findings. Tuberculosis should be included in the differential diagnosis in any case of isolated chronic unilateral inguinal lymphadenitis, especially in developing countries.

Key Words: Tuberculosis, unilateral inguinal lymphadenopathy

Bir Adelosanda Akciğer Dışı Tüberkülozun Nadir Bir Görünümü: İzole Tek Tarafli Inguinal Lenfadenit

Özet: İzole inguinal tüberküloz lenfadenit son derece nadir ve genellikle bilateral görülen bir durumdur. İştahsızlık, gece terlemesi ve ağrısız-yumuşak sağ inguinal lenf bezi şişliği nedeniyle başvuran 16 yaşındaki erkek hastaya eksizyonel biyopsisi yapıldı. Biyopsi materyalinin Ziehl-Nielsen boyamasında aside dirençli bakteri görüldü ancak kültüründe bakteri üretilmedi. Biyopsi materyalinin histolojik değerlendirilmesinde kazeoz nekroz ve epitelioid granülom vardı. Tüberkülin deri testi (Mantoux) 22 mm çapında pozitif. Bu bulgularla hasta tüberküloz lenfadenit olarak değerlendirildi. Özellikle gelişmekte olan ülkelerde izole, kronik ve tek tarafli inguinal lenfadenitin ayırıcı teşhisinde tüberkülozda düşünülmalıdır.

Anahtar Sözcükler: Tek tarafli inguinal lenfadenopati, tüberküloz.

Introduction

The majority of tuberculous bacilli (95%) enter the body via the respiratory system. Cervical and supraclavicular lymph nodes are the most affected sites after lung and pleura (1). Tuberculous lymphadenitis is the main form of extrapulmonary tuberculosis. Cervical lymph nodes are most frequently involved, followed by axillary lymph nodes (1,2). Isolated tuberculous inguinal lymphadenitis is a rare entity and is usually bilateral (1,3). In this report, we present a very rare case of unilateral isolated inguinal tuberculous lymphadenitis in a 16-year-old male patient.

Case Report

A 16-year-old male presented with anorexia, nocturnal sweating and painless right inguinal lymph nodes for the past two months. The patient was not sexually active and there was no history of fever, cough, dysuria or urethral discharge. On his physical examination, temperature was 37.5 °C and he had two right soft and non-tender inguinal lymph nodes with a diameter of 2.5 cm. Ultrasonography confirmed the presence of two enlarged reactive right inguinal lymph nodes with a diameter greater

¹ Department of Pediatrics,
Faculty of Medicine,
Kahramanmaraş Sütçü İmam
University,
Kahramanmaraş - TURKEY

² Department of Infectious Diseases,
Kahramanmaraş Yenisehir Hospital,
Kahramanmaraş - TURKEY

³ Department of Infectious Diseases,
Faculty of Medicine,
Kahramanmaraş Sütçü İmam
University,
Kahramanmaraş - TURKEY

⁴ Department of Chest Diseases,
Faculty of Medicine,
Kahramanmaraş Sütçü İmam
University,
Kahramanmaraş - TURKEY

Received: July 13, 2007
Accepted: November 15, 2007

Correspondence

Ekrem GÜLER
Department of Pediatrics,
Faculty of Medicine,
Kahramanmaraş Sütçü İmam
University, (TR-46050)
Kahramanmaraş - TURKEY

ekremguler@hotmail.com

than 2.5 cm while the contralateral inguinal lymph nodes were normal. In abdominal ultrasonographic evaluation, there was no evidence of hepatosplenomegaly or of intra-abdominal lymphadenopathy. Chest radiograph was normal. Hemoglobin was 14.2 g/dl and white blood cell count 12 900/mm³ with 44% neutrophils, 50% lymphocytes, and 6% monocytes. The erythrocyte sedimentation rate was 74 mm/1st hour and C-reactive protein was 46 mg/L (normal <5 mg/L). A tuberculin skin test (Mantoux) was positive with 22 mm diameter. Urine analysis and serum chemistry were normal. Antistreptolysin titer and serology for cytomegalovirus, Epstein-Barr virus, Toxoplasma, hepatitis B and C virus, and herpes virus were all negative. Lymph nodes were removed surgically (Figure 1). The patient underwent excision of lymph nodes; Ziehl-Neelsen stain revealed the presence of acid-fast bacilli and culture of the lymph nodes was negative. Histological sections showed the presence of extensive central caseous necrosis and multiple epithelioid cell granulomas (Figure 2). An extensive workup did not reveal any other foci of tuberculosis. Examination revealed no symptoms or signs of active tuberculosis in any members of his household. The patient was treated with a standard anti-tuberculous regimen consisting of isoniazid and rifampicin for nine months and pyrazinamide for the first two months. Two months after the initiation of treatment, the symptoms had resolved.

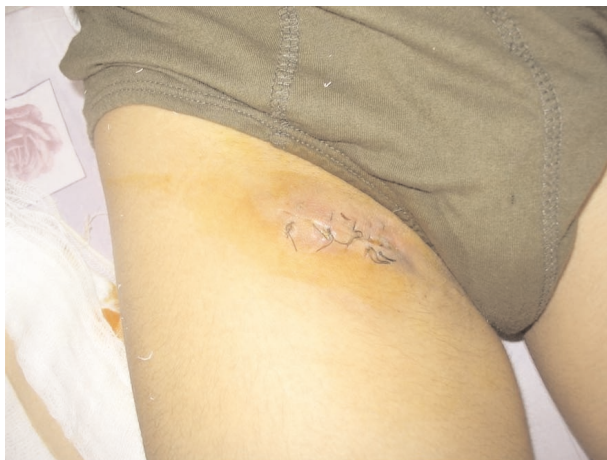

Figure 1. The patient seen after surgical removal of inguinal lymph nodes.

Discussion

Chronic lymphadenitis with caseous necrosis may occur in mycobacterial or fungal lymphadenitis (1-4). Thus, tuberculosis was considered as an initial diagnosis in our patient and was confirmed by histological examination, smear and tuberculin test. Peripheral tuberculous lymphadenitis is seen mainly in endemic areas like Turkey (4).

Isolated inguinal tuberculous lymphadenitis is a rare condition in developed countries. Characteristically, in a series of 67 cases from the United Kingdom with peripheral tuberculous lymphadenitis, inguinal involvement was observed in only three patients (4). Cases described in the English report had bilateral primary inguinal tuberculous lymphadenitis. In developing countries, peripheral tuberculous lymphadenitis represents approximately 22% of all types of extrapulmonary tuberculosis and is the main cause of peripheral lymphadenopathy (2). Classically, the disease affects children and generally involves the lymph nodes draining the head and neck. There are only two reports from India and Greece involving male patients who presented with isolated unilateral tuberculous lymphadenitis (3,5).

The pathogenesis of isolated tuberculous inguinal lymphadenitis may be explained by local reactivation of a dormant infection, resulting from hematogenous spread

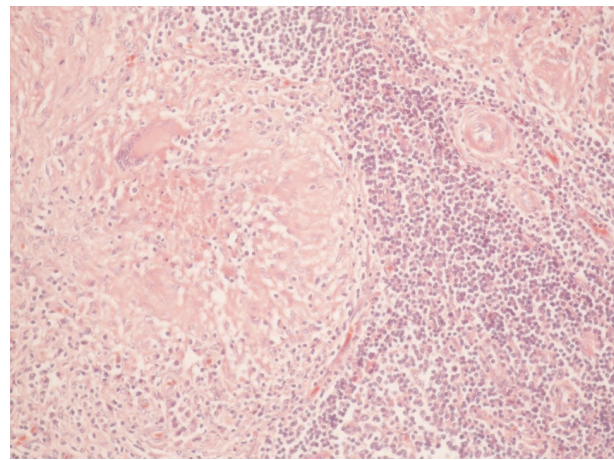


Figure 2. Histological sections show presence of extensive central caseous necrosis and multiple epithelioid cell granulomas.

of *Mycobacterium* from a subclinical primary pulmonary focus. Our patient had a history of tuberculous signs and symptoms and laboratory findings, but his chest radiograph did not reveal signs of primary pulmonary tuberculosis, and household contacts had no active infection.

In conclusion, we suggest that tuberculosis should be included in the differential diagnosis in any case of isolated chronic unilateral inguinal lymphadenitis,

especially in developing countries. The unilateral aspect in our case is also of importance.

Acknowledgements

This report was presented as a poster in the First International Congress of Central Asia Infectious Diseases, Bishkek, Kyrgyzstan, 30 October - 2 November 2006.

References

1. Aksel N, Tavusbay NA, Özsöz A. Our cases with tuberculous lymphadenitis. *Arch Lung* 2005; 1: 30–3.
2. Marais BJ, Wright CA, Schaaf HS, Gie RP, Hesselning AC, Enarson DA et al. Tuberculous lymphadenitis as a cause of persistent cervical lymphadenopathy in children from a tuberculosis-endemic area. *Pediatr Infect Dis J* 2006; 25: 142–6.
3. Loukeris D, Zormpala A, Chatzikonstantinou K, Androulaki A, Sipsas NV. Primary unilateral tuberculous inguinal lymphadenitis. *Eur J Intern Med* 2000; 16: 531–3.
4. Thompson MM, Underwood MJ, Sayers RD, Dookeran KA, Bell PR. Peripheral tuberculous lymphadenopathy: a review of 67 cases. *Br J Surg* 1992; 79: 763–4.
5. Thami GP, Kaur S, Kanwar AJ, Bhalla M. Isolated inguinal tuberculous lymphadenitis. *J Eur Acad Dermatol Venereol* 2002; 16: 297–8.