

1-1-2008

## A Rare Cause of Intestinal Obstruction: Meckel's Diverticulitis

OSKAY KAYA

MÜNEVVER MORAN

FATİH ÖZDEMİR

SÜLEYMAN ÇETİNKUNAR

Follow this and additional works at: <https://journals.tubitak.gov.tr/medical>



Part of the [Medical Sciences Commons](#)

---

### Recommended Citation

KAYA, OSKAY; MORAN, MÜNEVVER; ÖZDEMİR, FATİH; and ÇETİNKUNAR, SÜLEYMAN (2008) "A Rare Cause of Intestinal Obstruction: Meckel's Diverticulitis," *Turkish Journal of Medical Sciences*: Vol. 38: No. 3, Article 16. Available at: <https://journals.tubitak.gov.tr/medical/vol38/iss3/16>

This Article is brought to you for free and open access by TÜBİTAK Academic Journals. It has been accepted for inclusion in Turkish Journal of Medical Sciences by an authorized editor of TÜBİTAK Academic Journals. For more information, please contact [academic.publications@tubitak.gov.tr](mailto:academic.publications@tubitak.gov.tr).

## A Rare Cause of Intestinal Obstruction: Meckel's Diverticulitis

Oskay KAYA

Münevver MORAN

Fatih ÖZDEMİR

Süleyman ÇETİNKUNAR

**Abstract:** Small bowel obstruction is a rare complication of Meckel's diverticulitis. Our purpose is to present a case of a 16-year-old boy with a 3 days history of abdominal pain, recurrent vomiting, and absence of stool discharge. He had appendectomy 3 years ago. Upon laparotomy, we observed small bowel obstruction due to an adhesion between the tip of the inflamed Meckel's diverticulum and anterior abdominal wall. Although postoperative abdominal adhesions account for the most frequent cause of intestinal obstruction, Meckel's diverticulitis should also be kept in mind.

**Key Words:** Meckel's diverticulitis, intestinal obstruction

### Barsak Tıkanmasının Ender Bir Sebebi: Meckel Divertiküliti

**Özet:** İnce barsak tıkanıklığı Meckel divertikülitinin ender rastlanan bir komplikasyonudur. Anamnezinde üç günlük karın ağrısı, tekrarlayan kusma ve gaita yapamama yakınması olan 16 yaşında bir erkek hastayı sunmayı amaçladık. Hastaya 3 yıl önce apandektomi yapılmıştı. Laparotomide iltihaplı Meckel divertikülü ucu ile batın ön duvarı arasında oluşmuş yapışıklığa bağlı ince barsak tıkanıklığı vardı. İnce barsak tıkanıklığının en sık sebebi ameliyat sonrası batın içinde oluşmuş yapışıklıklar olmasına rağmen Meckel divertiküliti de akılda bulundurulmalıdır.

**Anahtar Sözcükler:** Meckel divertiküliti, barsak tıkanıklığı

Department of Surgery,  
Ankara Dışkapı Teaching and  
Research Hospital,  
Ankara - TURKEY

### Introduction

Meckel's diverticulum is a rare clinical entity that only occurs in 2% of healthy people and 4% of patients with Meckel's diverticulum develop complications like bleeding, perforation, inflammation, or obstruction (1). We report the case of a 16-year-old boy with clinical features and laboratory findings of small bowel obstruction without specific etiology; an exploratory laparotomy revealed a small bowel obstruction resulting from Meckel's diverticulitis.

### Case Report

The patient had a sharp, constant, severe periumbilical pain for the last 3 days. Previous medical history revealed that the patient had several abdominal pain, fever, and vomiting episodes, with similar clinical features, resolving in 1–2 days. Besides, the patient had undergone appendectomy 3 years ago. The remainder of the examination of the patient was unremarkable and social and family history was noncontributory. On examination, the temperature was 38 °C; blood pressure, 125/80 mmHg; heart rate, 90/min; and respiratory rate, 20/min. Abdominal examination revealed periumbilical tenderness with guarding and rebound but no rigidity. Bowel sounds were present but of diminished intensity. Mc Burney incision scar was present. Routine laboratory tests were in normal range except mild leukocytosis (16,300 white blood cells/mm<sup>3</sup>). The initial plain abdominal X-ray revealed gas-fluid levels and showed a few loops of slightly dilated, gas-filled small bowel (Figure 1). Abdominal computed tomography (CT) demonstrated multiple fluid-filled, dilated loops of the middle and distal small bowel with collapsed distal ileum 12 h after admission. No masses or focal bowel wall thickening were identified (Figure 2). We decided to operate the patient with the

Received: September 12, 2007

Accepted: March 07, 2008

#### Correspondence

Oskay KAYA

8. Cadde, Mercan Sitesi,

B Blok No: 119/17,

Çayyolu, Ankara - TURKEY

oskaykaya@superonline.com

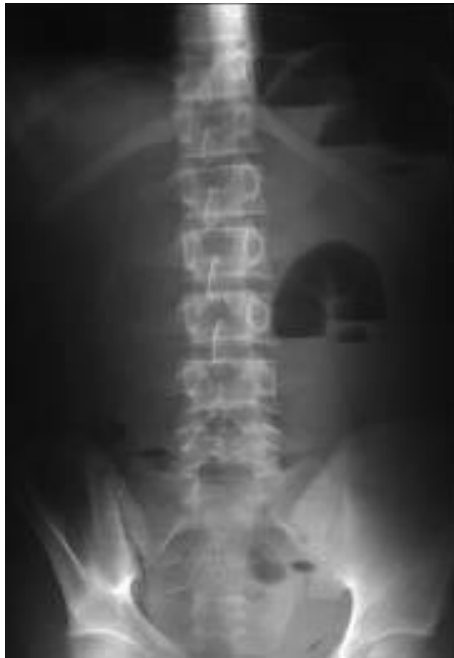

Figure 1. Plain abdominal X-ray shows small bowel obstruction.

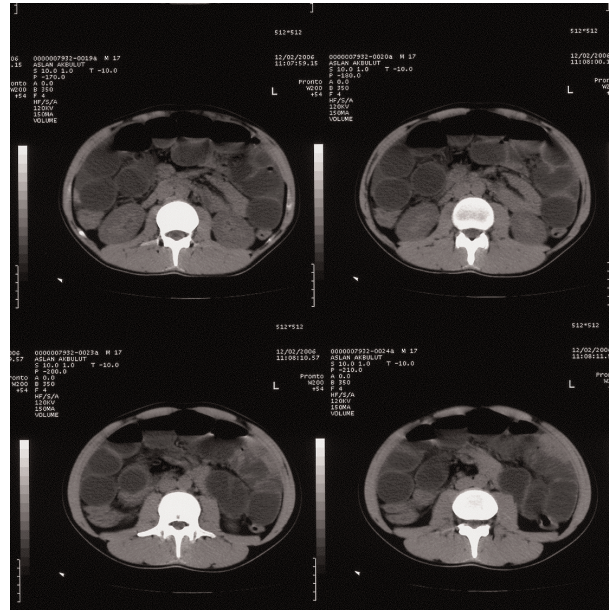


Figure 2. Abdominal CT scan revealing multiple dilated, fluid-filled loops of small bowel but no mass.

prediagnoses of intestinal obstruction due to peritoneal adhesion, intestinal invagination or probable intestinal mass. At laparotomy, the apex of the inflammatory Meckel's diverticulum was stuck to the omentum and anterior abdominal wall. This adhesion created an obstructed fold in the adjacent small intestine (Figure 3 and 4). Bowel loops proximal to this obstruction were

dilated and the terminal ileum and right colon were collapsed. The adhesive band was released, a diverticulectomy was performed; histological examination revealed glandular dysplastic enteric mucosa. The patient was discharged without complication 4 days after surgery.

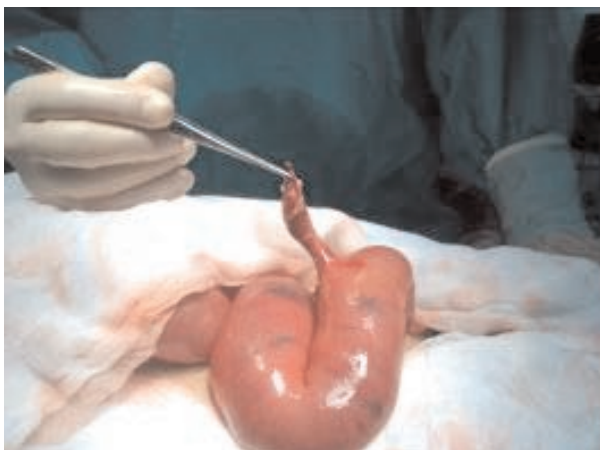

Figure 3. Inflamed Meckel's diverticulum after separation of adhesion from the anterior abdominal wall.

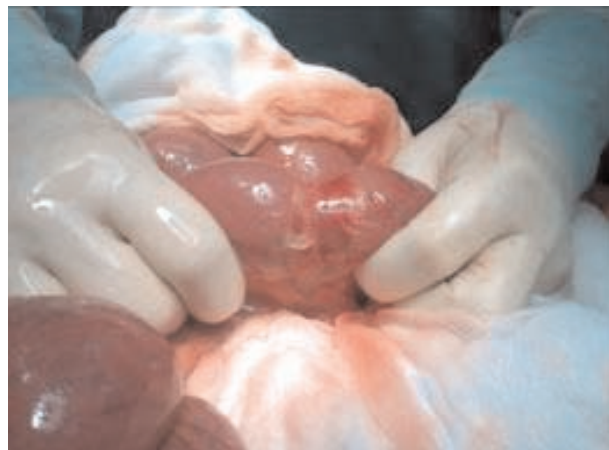

Figure 4. Obstructed intestinal segment with finding of compression.

## Discussion

Meckel's diverticulum is the most commonly encountered congenital anomaly of the small intestine occurring in approximately 2% of the population (1). The risk of complications in patients with a Meckel's diverticulum is 4% (2). Complications, 40% of which occur in children younger than 10, usually present with gastrointestinal bleeding (3). Adults develop obstruction or, less frequently, symptoms of inflammation. In adults, hemorrhage is much less common and is usually the result of heterotopic gastric or pancreatic mucosa causing ulceration. Small bowel obstruction due to Meckel's diverticulitis may be caused by entangled loop of small bowel around a fibrous cord, entrapping an ileal loop within a mesodiverticular band, intussusception, volvulus, or incarceration within a hernia sac (4). Small bowel obstruction is usually demonstrable on plain films of the abdomen. Also the cause of the small bowel obstruction might be shown by CT (5). Although barium studies of the small bowel are relatively insensitive for the detection of Meckel's diverticulum, enteroclysis demonstrated a Meckel's diverticulum in 11 of 13 patients with

gastrointestinal bleeding in a cohort (6). Arteriography and technetium pertechnetate scanning are useful only if there is significant bleeding or ectopic gastric mucosa (7). In this case we diagnosed the patient, who has undergone appendectomy 3 years ago, by exploratory laparotomy. As the patient's condition, and also technical difficulties, did not permit us to obtain enteroclysis and examine the patient further, we could only obtain abdominal computed noncontrast tomography with routine laboratory blood tests and plain radiograms. When a patient is diagnosed with intestinal obstruction due to Meckel's diverticulum, treatment should be made by excision.

In conclusion, Meckel's diverticulum and its complications must be kept in mind in patients with small bowel obstruction.

## Acknowledgement

We would like to thank the head of our department, Assoc. Prof M. Mahir OZMEN, for his help for the operation and the management of this patient.

## References

1. Evers BM. Small bowel. in: Courtney M. Townsend jr., editor. Sabiston Textbook of Surgery. Philadelphia, Pennsylvania. W.B. Saunders 2001; pp.: 873-916.
2. Whang EE, Ashley SW, Zimmer MJ. Small intestine. In: F.Charles Brunicaudi, editor. Schwartz's Principles of Surgery. McGraw-Hill 2005; pp.:1017-1054
3. St-Vil D, Brandt ML, Panic S, Bensoussan AL, Branchard H. Meckel's diverticulum in children: A 20-year review. Journal of Pediatric Surgery 1991; 26: 1289-1292.
4. Martin JP, Connor PD, Charles, K. Meckel's diverticulum. Am Fam Physician 2000; 61: 1037-1042.
5. Ikard RW. Diagnosis of Meckel's diverticulum by computerized tomography. Tenn Med 1996; 5: 164-5.
6. Maglinte DD, Elmore M, Isenberg M, Dolan PA. Meckel's diverticulum: Radiologic demonstration by enteroclysis. AJR Am J Roentgenol 1980; 134: 925-32.
7. Rossi P, Gourtsoyiannis N, Bezzi M, Raptopoulos V, Massa R Capanna et al. Meckel's diverticulum: Imaging diagnosis. AJR Am J Roentgenol 1996; 166: 567-73.