

1-1-2008

## Mixed Medullary-Follicular Thyroid Carcinoma : A Report of Two Cases

ÖZGE HAN

TUBA ÜNAL

SELDA SEÇKİN

SEZER KULAÇOĞLU

Follow this and additional works at: <https://journals.tubitak.gov.tr/medical>



Part of the [Medical Sciences Commons](#)

---

### Recommended Citation

HAN, ÖZGE; ÜNAL, TUBA; SEÇKİN, SELDA; and KULAÇOĞLU, SEZER (2008) "Mixed Medullary-Follicular Thyroid Carcinoma : A Report of Two Cases," *Turkish Journal of Medical Sciences*: Vol. 38: No. 4, Article 12. Available at: <https://journals.tubitak.gov.tr/medical/vol38/iss4/12>

This Article is brought to you for free and open access by TÜBİTAK Academic Journals. It has been accepted for inclusion in Turkish Journal of Medical Sciences by an authorized editor of TÜBİTAK Academic Journals. For more information, please contact [academic.publications@tubitak.gov.tr](mailto:academic.publications@tubitak.gov.tr).

## Mixed Medullary-Follicular Thyroid Carcinoma : A Report of Two Cases

Özge HAN  
Tuba ÜNAL  
Selda SEÇKİN  
Sezer KULAÇOĞLU

**Abstract:** Mixed medullary-follicular carcinoma is an uncommon tumor of the thyroid. It is characterized by histological and immunohistochemical features of both follicular and parafollicular C cells. We report two female patients, aged 26 and 78 years, with mixed medullary-follicular carcinoma. Histologically, the tumors are composed of follicular carcinoma areas and solid nests of polygonal cells consistent with medullary carcinoma. Immunohistochemically, thyroglobulin and calcitonin positivity was detected. Precise diagnosis of mixed medullary-follicular carcinoma is essential for accurate treatment and follow-up.

**Key Words:** Thyroid, Mixed medullary-follicular carcinoma

### Mikst Medüller - Folliküler Tiroid Karsinomu : İki Olgu Sunumu

Department of Pathology,  
Ankara Numune Teaching and  
Research Hospital, Ankara - TURKEY

**Özet:** Mikst medüller – folliküler karsinoma tiroidin nadir görülen bir tümördür. Histolojik ve immünhistokimyasal olarak folliküler ve parafolliküler C hücrelerinin özelliklerini içerir. Bu yazıda mikst medüller – folliküler tiroid karsinomu tanısı almış 26 ve 78 yaşlarındaki iki kadın olgu sunulmaktadır. Histolojik olarak her iki tümör de folliküler karsinoma alanları ve medüller karsinoma ile uyumlu poligonal şekilli hücrelerden oluşan solid adalar içermekte idi. İmmünhistokimyasal olarak tiroglobulin ve kalsitonin pozitivitesi saptandı. Mikst medüller – folliküler karsinoma tanısının doğru konması uygun tedavi ve izlem açısından önem taşır.

**Anahtar Sözcükler:** Tiroid, Mikst medüller-folliküler karsinoma

### Introduction

Mixed medullary-follicular carcinoma is an uncommon tumor of the thyroid and consists of both follicular and parafollicular cells. Medullary carcinoma areas arising from parafollicular cells show calcitonin immune reactivity, whereas follicular cell foci exhibit thyroglobulin immunoreactivity (1). Their morphological, histochemical and immunohistochemical features were defined in the early 1980's (2).

### Case Reports

#### Case 1

A 26-year-old woman was diagnosed as medullary carcinoma by fine needle aspiration cytology (FNAC) through the nodule in the right lobe of the thyroid. Her blood calcitonin level was remarkably high (111 µg/µl). Total thyroidectomy, bilateral neck dissections and central lymph node dissection were performed.

Macroscopically, a white colored nodule 1.5 cm in diameter on the right lobe was detected. No remarkable changes were noted in the left lobe sections. The right neck dissection material was 8.5 × 3.5 × 1.5 cm and 10 lymph nodes were detected, the largest of which was 1 cm, while the left neck dissection material was 9 × 3 × 3 cm and 9 lymph nodes were detected, the largest of which was 1 cm in diameter. On the other hand, central lymph node material was 5 × 3 × 0.5 cm and 2 lymph nodes were detected, with the largest being 0.6 cm.

Received: November 23, 2007  
Accepted: May 05, 2008

#### Correspondence

Selda SEÇKİN  
Department of Pathology  
Ankara Numune Teaching and  
Research Hospital  
Ankara - TURKEY

seldaseckin@yahoo.com

Microscopically, on cut section of the nodule in the thyroid right lobe, a tumor separated by a thin fibrous capsule from the peripheral thyroid tissue was observed. The tumor was centrally hyalinized and there were follicular structures at the periphery (Figure 1A). The follicular structures in the tumor contained scanty amount of colloid compared to the follicular structures in surrounding thyroid tissue. The tumor cells forming follicles had oval or round, vesicular ground glass nuclei

and scanty cytoplasm. However, not all of the nuclear features necessary for diagnosis of papillary carcinoma were present. Scattered psammoma bodies were noticed in the tumor. The hyalinized area at the center of the tumor was 0.7 cm in diameter, and contained islets and trabeculae formed by oval, polygonal or spindle cells consistent with medullary carcinoma (Figure 2A). Histochemically, there was no evidence of amyloid by using crystal violet.

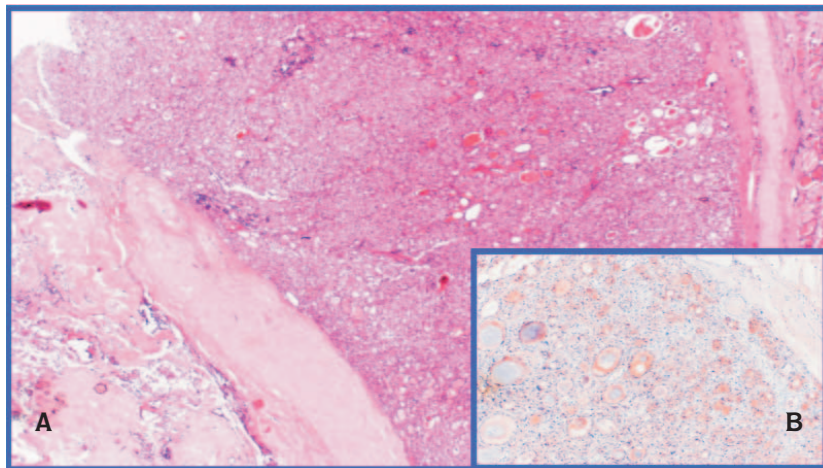


Figure 1. A-The tumor separated from the peripheral thyroid tissue by a thin fibrous capsule (hematoxylin and eosin,  $\times 20$ ).

B-Thyroglobulin positivity in tumor cells ( $\times 40$ ).

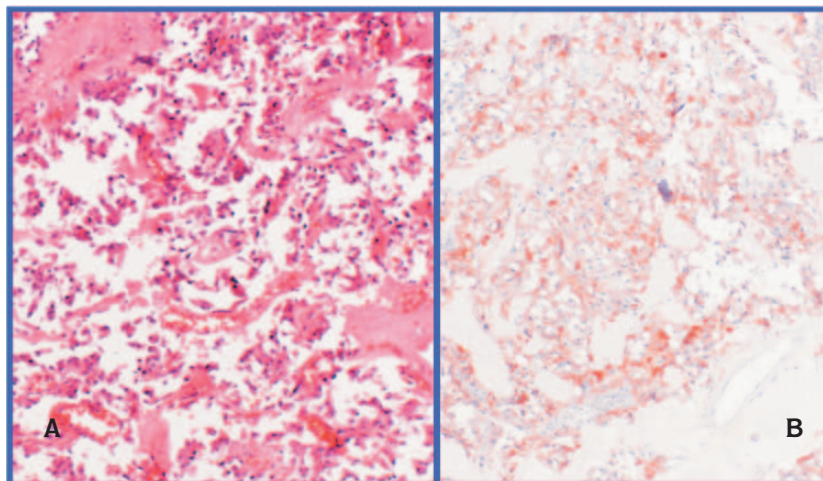


Figure 2. A-The tumor cells in medullary carcinoma area (hematoxylin and eosin,  $\times 100$ ).

B-Calcitonin positivity in these cells ( $\times 100$ ).

Immunohistochemically, widespread staining with thyroglobulin was detected in tumor cells forming neoplastic follicular structures under the capsule (Figure 1B). Some of these cells were stained with calcitonin. Furthermore, the tumor cells consistent with medullary carcinoma were observed expressing calcitonin (Figure 2B), chromogranin, NSE and synaptophysin at the center of the tumor. Increased number of C cells among the follicular structures in the adjacent thyroid tissue was remarkable and these cells also expressed calcitonin, chromogranin, NSE, and synaptophysin. Histologically, no remarkable features were seen in the left lobe sections. The case was diagnosed as mixed medullary-follicular carcinoma in which the follicular component of the tumor showed characteristically well-differentiated follicular carcinoma.

A total of 24 lymph nodes were dissected from the right and left neck dissections and central lymph node material, all of which showed no metastasis.

#### Case 2

A 78-year-old female patient was hospitalized with a complaint of swelling on her neck. The patient was being followed due to goiter and was under hypertension treatment. Initially white colored tissue measuring 1.2 × 0.5 × 0.3 cm from the right thyroid lobe was received for frozen section. Histological examination of the tissue was

consistent with medullary carcinoma. Subsequently, bilateral total thyroidectomy was performed. On gross examination, the right lobe was 10 × 6 × 5 cm, pyramidal lobe was 5 × 4 × 3 cm, and left lobe was 6 × 3.5 × 3 cm. Cut sections revealed several white nodules, the largest and smallest of which were 3 cm and 0.4 cm in diameter, respectively. On the pyramidal lobe, two nodules were detected (largest: 3.5 cm; smallest: 2 cm). One yellow colored nodule of 5 cm was present in left lobe sections.

Histologically, a tumor with infiltrative pattern composed of solid, trabecular and follicular structures was seen throughout the whole sections of the nodules. The tumor cells were oval, polygonal and spindle-shaped and some of them had granular, eosinophilic cytoplasm (Figure 3A). Clear cells were noted. Squamous differentiation foci were prominent particularly around necrosis. Extensive vascular invasion was detected. Histochemically, amyloid was not present using crystal violet. The tumor cells composing follicular structures were oval- or round-shaped with vesicular nuclei and eosinophilic cytoplasm (Figure 3B). Those cells were stained by thyroglobulin. In the foci consistent with medullary carcinoma, the cells were reactive for calcitonin (Figure 4A) and chromogranin diffusely and for NSE focally. It was remarkable that some of the tumor cells were stained with both calcitonin and thyroglobulin (Figure 4B).

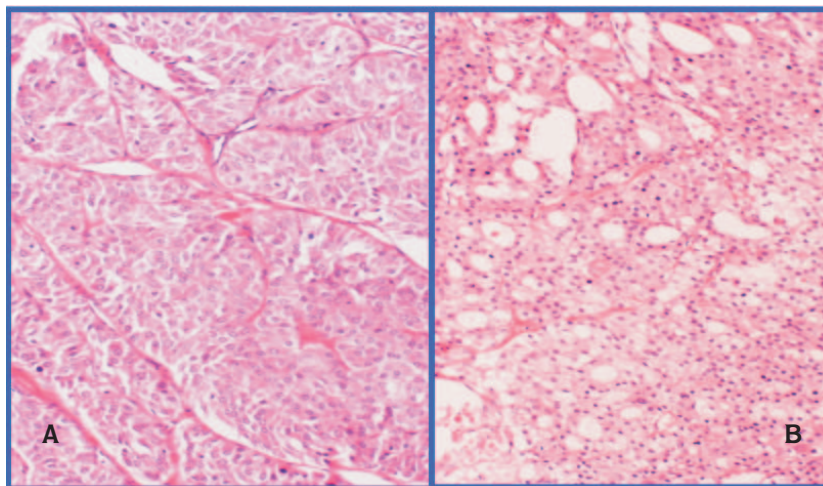


Figure 3. A-The oval, polygonal shaped tumor cells with granular, eosinophilic cytoplasm representing medullary carcinoma (hematoxylin and eosin, ×100).

B-The tumor cells composing follicular structures in follicular carcinoma area (hematoxylin and eosin, ×100).

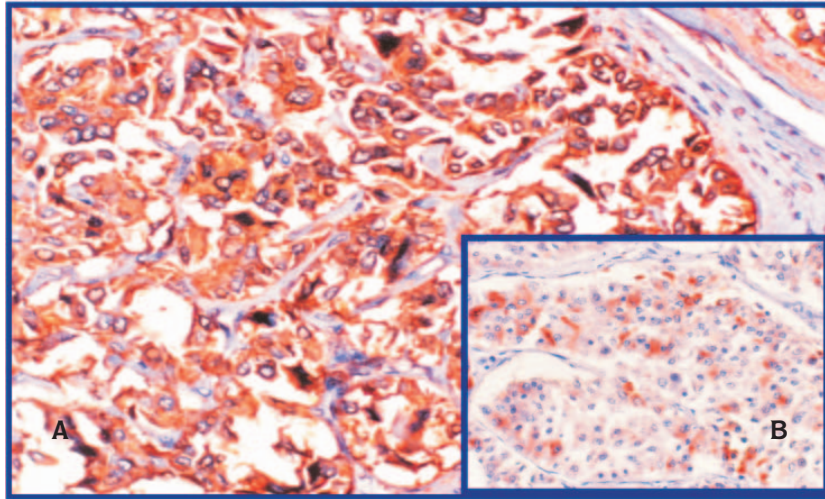


Figure 4. A-Calcitonin reactivity in medullary carcinoma cells (x200).

B-Thyroglobulin positivity in some of these cells in the same focus (x100).

The case was diagnosed as mixed medullary-follicular carcinoma. Five months later, the patient presented with a swelling in her neck. Cervical mass excision and neck dissection were performed. The sections revealed the tumor of 6 × 4 × 3 cm and 23 lymph nodes, the largest of which was 3 cm. Histology showed the similar tumor morphology. There were two metastatic lymph nodes and the rest exhibited reactive pattern.

## Discussion

It is known that medullary carcinoma of the thyroid was described by Hazard et al. in 1959 as a different clinical and pathological entity showing solid, non-follicular pattern (3,4). In 1982, Hales et al. (2) reported a thyroid carcinoma case exhibiting mixed medullary-follicular pattern. Mixed medullary-follicular carcinoma was described as a distinct entity under the malignant epithelial tumor groups of the 1988 World Health Organization (WHO) classification. The morphological features of medullary carcinoma with calcitonin positivity and the diagnostic characteristics of follicular carcinoma with thyroglobulin positivity are mandatory for diagnosis (1,4-6). In such description, there is no difference between the follicular or papillary characteristics of the follicular cell tumor (1). The cellular origin of the mixed medullary-follicular carcinoma is not exactly established, yet one of the hypotheses shows that the tumor might

arise from the multipotent stem cells and that ultimobranchial rests might have a role. An alternative hypothesis presumes that a common oncogenic stimulus that affects both follicular and parafollicular cells might play a role (1,4). In certain studies, it has been thought that the RET proto-oncogene mutation might be effective (6,7).

To our knowledge, the number of reported cases in the English literature is nearly 50. This tumor is particularly seen in middle-aged patients, and a swelling on the neck is generally the initial symptom. Serum calcitonin level was high in the previous cases, as in our first case. The level of thyroglobulin may sometimes also be high. The size of the tumor might vary between 1 and 5.5 cm. The tumor might involve both lobes and isthmus. It is generally unifocal, as observed in our first case, while multifocal tumors are particularly associated with MEN Type IIA.

In most of the cases, lymph node metastasis is detected at the time of diagnosis (5). In our second case, the tumor was multifocal and lymph node metastases were observed. However, in this case, we could not ascertain relevant information regarding the level of serum calcitonin and the relation with MEN Type IIA. In both cases, foci consistent with medullary carcinoma were observed and in these foci immunohistochemical findings supporting the medullary carcinoma were

detected. As thyroglobulin immunoreactivity was shown in tumor cells forming the follicular structures, mixed medullary-follicular carcinoma diagnosis was facilitated. It is noteworthy to emphasize the co-expression of calcitonin and thyroglobulin in some of the tumor cells.

In the differential diagnosis, the follicular variant of the medullary carcinoma should be considered. Since the cells forming the follicular structures in the follicular variant of the medullary carcinoma are similar to the cells in typical medullary carcinoma foci, their staining with calcitonin instead of thyroglobulin is important in distinguishing them. Normal thyroid follicles entrapped in

medullary carcinoma foci should also be considered in the differential diagnosis (1,4-6). The main method in the treatment of mixed medullary-follicular carcinoma cases is total thyroidectomy and radioactive iodine treatment; chemotherapy might also be considered (4). In the follow-up of the patient's blood, calcitonin and thyroglobulin levels might be helpful. Distant metastasis can be observed frequently in lungs, liver, mediastinum and bones, and the patients might die within 10 years after the diagnosis due to tumor (4,5). Diagnosis of the mixed medullary-follicular carcinoma is essential for appropriate follow-up and treatment.

## References

1. Papotti M, Negro F, Carney JA, Bussolati G, Lloyd RV. Mixed medullary-follicular carcinoma of the thyroid. A morphological, immunohistochemical and in situ hybridization analysis of 11 cases. *Virchows Arch* 1997; 430: 397-405.
2. Hales M, Rosenau W, Okerlund MD, Galante M. Carcinoma of the thyroid with a mixed medullary and follicular pattern: morphologic, immunohistochemical and clinical laboratory studies. *Cancer* 1982; 50: 1352-9.
3. Pfaltz M, Hedinger CE, Mühlethaler JP. Mixed medullary and follicular carcinoma of the thyroid. *Virchows Arch* 1983; 400: 53-9.
4. Rosai J, Carcangiu ML, DeLellis RA. *Tumors of the thyroid gland*. Washington: AFIP, third series; 1992. pp. 207-45.
5. Kostoglou-Athanassiou I, Athanassiou P, Vecchini G, Gogou L, Kaldrymides P. Mixed medullary-follicular thyroid carcinoma. Report of a case and review of the literature. *Horm Res* 2004; 61: 300-4.
6. Luboshitzky R, Dharan M. Mixed follicular-medullary thyroid carcinoma: a case report. *Diagn Cytopathol* 2004; 30: 122-4.
7. Dusková J, Janotová D, Svobodová E, Novák Z, Tretiník P. Fine needle aspiration biopsy of mixed medullary-follicular thyroid carcinoma. A report of two cases. *Acta Cytol* 2003; 47: 71-7.