

1-1-2008

An Unusual Cause of Dysphagia: Hypopharyngeal Inflammatory Pseudotumor

BARAN ACAR

MEHMET ALİ BABADEMEZ

HAYRİYE KARABULUT

SELAHATTİN GENÇ

R. MURAT KARAŞEN

Follow this and additional works at: <https://journals.tubitak.gov.tr/medical>



Part of the [Medical Sciences Commons](#)

Recommended Citation

ACAR, BARAN; BABADEMEZ, MEHMET ALİ; KARABULUT, HAYRİYE; GENÇ, SELAHATTİN; and KARAŞEN, R. MURAT (2008) "An Unusual Cause of Dysphagia: Hypopharyngeal Inflammatory Pseudotumor," *Turkish Journal of Medical Sciences*: Vol. 38: No. 6, Article 20. Available at: <https://journals.tubitak.gov.tr/medical/vol38/iss6/20>

This Article is brought to you for free and open access by TÜBİTAK Academic Journals. It has been accepted for inclusion in Turkish Journal of Medical Sciences by an authorized editor of TÜBİTAK Academic Journals. For more information, please contact academic.publications@tubitak.gov.tr.

An Unusual Cause of Dysphagia: Hypopharyngeal Inflammatory Pseudotumor

Baran ACAR

Mehmet Ali BABADEMEZ

Hayriye KARABULUT

Selahattin GENÇ

R. Murat KARAŞEN

Abstract: Inflammatory pseudotumor (IP) is a rare pseudoneoplastic and lymphoproliferative disorder. The etiology of IP is still unclear. A 46-year-old male patient presented with a six-month history of dysphagia and diplophonia. Endoscopic examination of the larynx and hypopharynx revealed a 15 × 20 mm smooth-surfaced mass involving the right side of the hypopharynx. Computerized tomography (CT) scans of the neck showed a mass 3 cm in diameter at the level of the hyoid bone. The mass obliterated the pharyngeal lumen. Pathology after incisional biopsy was consistent with pseudotumor. The mass regressed dramatically after corticosteroid treatment and afterwards the patient underwent surgical treatment. Postoperative course of the patient was uneventful. Follow-up of six months showed no recurrence. We report a very rare case of IP originating in the hypopharynx. To our knowledge, hypopharyngeal IP presenting with dysphagia and diplophonia has not been described in the literature thus far.

Key Words: Inflammatory pseudotumor, dysphagia, diplophonia, hypopharynx

Department of Otorhinolaryngology,
Keçioren Training and
Research Hospital,
Ankara - TURKEY

Alışılmadık Bir Disfaji Nedeni: Hipofaringeal İnflamatuar Psödötümör

Özet: İnflamatuar psödötümör etyolojisi tam olarak aydınlatılmamış psödoneoplastik ve lenfoproliferatif bir patolojidir. 46 yaşındaki erkek hasta disfaji ve diplofoni şikayeti ile başvurdu. Endoskopik muayenesinde sağ hipofaringeal bölgeden kaynaklanan 15 × 20 mm düzgün yüzeyli faringeal lümene protrüze olan kitle izlendi. Bilgisayarlı tomografide hyoid kemik seviyesinde 3 cm çapında kitle izlendi. Bilgisayarlı Tomografi (BT) kesitlerinde kitlenin faringeal lümene protrüze olduğu görüldü. İnsizyonel biyopsi ile elde edilen patoloji sonucu psödötümör olarak geldi. Sistemik steroid sonrası belirgin olarak küçülen kitle boyuna eksternal yaklaşım ile çıkartıldı. Postop dönemde sorunsuz olan hastanın 6 ay sonraki kontrolünde nüks izlenmedi. Hipofarinksten köken alan nadir rastlanan bir inflammatuar psödötümör vakası bildiriyoruz. Bilgimize göre literatürde şimdiye kadar disfaji ve diplofoni şikayeti ile başvuran hipofaringeal inflammatuar psödötümör vakası yoktur.

Anahtar Sözcükler: İnflamatuar psödötümör, disfaji, diplofoni, hipofarinksten

Introduction

Inflammatory pseudotumor (IP) is a rare pseudoneoplastic and lymphoproliferative disorder (1). IP is a clinicopathologic term. The etiology of the disorder is still unknown. The lesion presents as a progressive space-occupying mass, which may be found in a variety of locations. IP has been reported to occur in various sites of the head and neck including mouth, oropharynx, nasopharynx, parapharyngeal space, paranasal sinuses, pterygomaxillary space, major salivary glands, larynx, trachea, thyroid, lacrimal gland, orbit, central nervous system, meninges, and temporal bone (2-4). The characteristic histological elements of the lesions are histiocytes, myofibroblasts, plasma cells and lymphocytes. The surgical excision of IP appears to be curative. The effect of steroid treatment on the primary process has not been proven. In some cases, corticosteroids can be used when the surgical treatment will be too aggressive (2). We present a case of hypopharyngeal IP. To our knowledge, this is the first case of IP originating from the hypopharynx.

Case Report

A 46-year-old man was admitted with dysphagia and diplophonia that had been present for six months. The patient was otherwise healthy. He had no history of neck

Received: March 10, 2008
Accepted: September 03, 2008

Correspondence

Baran ACAR

Keçiören Training and
Research Hospital

Department of

Otorhinolaryngology

Pınarbaşı Mahallesi Sanatoryum

Caddesi Ardahan Sok. No: 1

06310 Keçiören,

Ankara - TURKEY

drbaranacar@gmail.com

infections, or of tobacco or alcohol consumption. There was no fever, pain or weight loss. He denied antecedent neck trauma, history of neck mass, constitutional symptoms, insect bites, and known exposure to tuberculosis. His travel history was unremarkable. Endoscopic examination of the larynx and the hypopharynx revealed a 15x20 mm smooth-surfaced mass involving the right side of the hypopharynx displacing the right pyriform fossa and aryepiglottic fold to the midline. Head and neck examination revealed no palpable neck masses, and the remainder of the otorhinolaryngologic examination was normal. Computerized tomography (CT) scans of the neck showed a mass 3 cm in diameter restricted in the right pyriform fossa, and there was an asymmetry in the pharyngeal lumen (Figure 1). CT scans revealed no invasion to the surrounding structures. In addition, there was no pathologic lymph node in the CT scans of the neck.

Afterwards, an endolaryngeal endoscopic incisional biopsy was performed under general anesthesia. Endoscopic examination of the larynx and hypopharynx revealed a 15x20 mm smooth-surfaced mass involving the right side of the hypopharynx. Histopathological examination showed a fibrohistiocytic infiltrate, mostly

composed of lymphocytes, plasma cells and fibrous background (Figure 2). The patient was hospitalized, and 2 mg/kg/day methylprednisolone was administered intravenously for 10 days in order to diminish the size of the mass. The mass regressed dramatically and became surgically removable in 10 days. The patient subsequently underwent a total conservative surgical excision of the residual tumor via external cervical approach. Pathology was consistent with IP. Surgery was performed under general anesthesia with the patient in the supine position. It was observed that the lesion was localized between the superior corn of the thyroid cartilage and right arytenoid cartilage. A 2x2 cm solitary, white-colored mass without invasion of the surrounding structures was encountered.

The histopathological examination was consistent with the previous one. Postoperative course of the patient was uneventful and there were no complications. The patient received antibiotic treatment for seven days. There was no recurrence during the six-month follow-up.

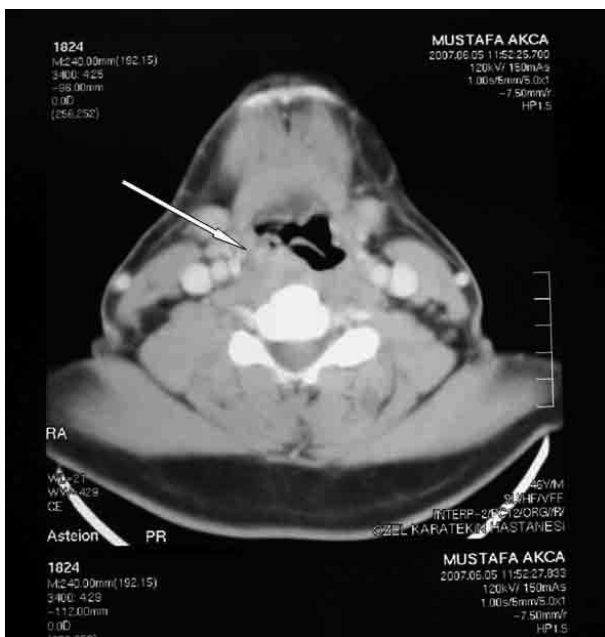

Figure 1. Computerized tomography (CT) scans of the neck showed a mass in the right pyriform fossa and there was an asymmetry in the pharyngeal lumen.

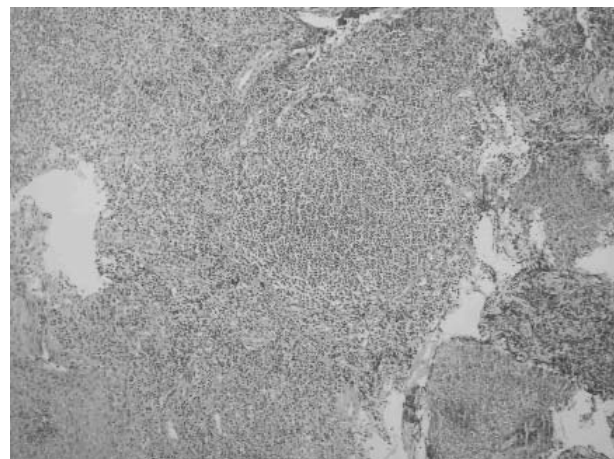


Figure 2. Histopathology slide of the inflammatory pseudotumor, mostly composed of lymphocytes, plasma cells and fibrous background.

Discussion

Inflammatory pseudotumor was first described in 1939 by Brunn (5). It is a clinicopathologic term used to describe a rare benign lymphoproliferative disorder with characteristic histopathological features. This rare pathology has been described in various locations in the human body. The exact etiology of this disorder and how it should be classified are not well known. The different terms that have been used for these types of lesions show the poor understanding of the subject, IP has also been

called fibrous histiocytoma, fibrous xanthoma, inflammatory myofibroblastic tumor, inflammatory myofibrohistiocytic tumor, myofibroblastoma, and plasma cell granuloma, etc. All these terms are based on the histological examination of the lesions (5).

Inflammatory pseudotumor clinically presents as a progressive space-occupying mass, and symptomatology depends on the site of the pathology. The lung is the most frequently affected organ (6). IPs rarely present primarily in the head and neck region; consequently, it is often not considered in the differential diagnosis of primary lesions of the head and neck. Head and neck involvement of the IP may present with palpable neck mass, hoarseness, stridor or airway obstruction. Most of the cases described until now involved the parotid gland (7). In addition, maxillary sinus, nasopharynx, thyroid gland or salivary gland can be affected in the head and neck region. IP affected the hypopharynx in the present case. To our knowledge, hypopharyngeal involvement of IP presenting with dysphagia and diplophonia has not been described thus far in the literature.

The exact diagnosis is difficult and it is often made by exclusion. As a result, it has sometimes required more than one biopsy or the surgical removal of the lesion in order to confirm the absence of neoplasm or infection and to establish the diagnosis of IP, as in this case. CT scans usually show a well-circumscribed apparently inflammatory lesion that can present central necrosis. Bone erosion is rare but possible (8).

Histologically, the lesions consist of four main components, including myofibroblasts, fibroblasts, histiocytes, and accompanying inflammatory infiltrate by histological, immunohistochemical, and ultrastructural characterization. The results of immunohistochemical studies show a population of cells of two types: 1) myofibroblasts and 2) histiocytes revealing positivity for actin, vimentin and KP1 (CD3). These findings support the theory that the IP is a lesion of a fibroinflammatory nature. In 1978, Somersén described three histopathological types of IPs (5), although most lesions contain elements of all types. These are a) histiocytic type, called xanthogranuloma, b) plasma cell type, called plasma cell granuloma and c) the sclerotic or sclerosing granulomatous type. The IP may mimic a malignancy but atypical features such as mitotic figures are not found (3,4). In the present case, a mononuclear infiltrate, mostly composed of lymphocytes, plasma cells and fibroblasts, was detected.

There is no unanimous agreement on the most appropriate treatment for IP. Most patients are cured by surgical excision. The type of surgery depends on the location and extent of the disease, but in general a complete removal of the space-occupying mass is carried out. Other therapeutic procedures include radiotherapy, chemotherapy, azathioprine, indomethacin and steroids (7,8). Steroids rapidly reduce the symptoms caused by the edema, but their effect on the primary process has not been proven. An infective cause can be demonstrated in some cases of IP, and occasional cases have been resolved after antibiotic therapy, but the role of this treatment is uncertain. Because of the favorable results reported in IP in other locations, corticosteroid treatment seems to be the best if a conservative surgical treatment is impossible (2). When resistance to corticosteroids appears, a treatment of a few weeks or months can be successful.

Recurrence can occur, at less than 5% for pulmonary IP and approximately 25% for extrapulmonary lesions. It has been suggested that an intraabdominal location, proximity to vital structures, a multinodular, ill-defined gross appearance, increased cellular atypia, prominent fascicular growth, and DNA aneuploidy may represent potential predictors for an increased risk of recurrence (1). Prognosis is generally good, but despite being a benign lesion histologically, there are some cases of aggressive behavior and local invasion (9). The potential mortality of IP is well established; in the series described by Coffin et al. (1), patients died of the disease, 1 with persistent tumor and sarcomatoid transformation and the other with local recurrence at eight months and bowel obstruction. Four patients survived with the disease (1). In the series described by Ramachandra et al. (4), 2 patients died postoperatively and 1 survived with the disease. In this particular case, we preferred surgical intervention with complete removal of the mass, and an accurate diagnosis was achieved by histopathological examination. There was no recurrence in the six-month follow-up.

In conclusion, although IPs have never been reported in the hypopharynx previously, they do occur. When evaluating dysphagia and diplophonia as symptoms in otherwise young, healthy patients, IP - though rare in the cervical area - should be considered on the list of entities in this important and often challenging differential diagnosis.

References

1. Coffin CM, Watterson J, Priest JR, Dehner LP. Extrapulmonary inflammatory myofibroblastic tumor (inflammatory pseudotumor). A clinicopathologic and immunohistochemical study of 84 cases. *Am J Pathol* 1995; 19: 859-72.
2. Hytioglou P, Brandwein MS, Strauchen JA, Mirante JP, Urken ML, Biller HF. Inflammatory pseudotumor of the parapharyngeal space: case report and review of the literature. *Head Neck* 1992; 14: 230-4.
3. Williams SB, Foss RD, Ellis GL. Inflammatory pseudotumors of the major salivary glands. Clinicopathologic and immunohistochemical analysis of six cases. *Am J Surg Pathol* 1992; 16: 896-902.
4. Ramachandra S, Hollowood K, Bisceglia M, Fletcher CD. Inflammatory pseudotumor of soft tissues: a clinicopathological and immunohistochemical analysis of 18 cases. *Histopathology* 1995; 27: 313-23.
5. Thawley SE, Panje WR, Batsakis JG, Lindberg RD. Granulomatous and lymphoproliferative diseases of the head and neck. In: Thawley SE, Panje WR, Batsakis JG, Lindberg RD, editors. *Comprehensive Management of Head and Neck Tumors*. Philadelphia: WB Saunders Company; 1999. pp. 1163-5.
6. Amedee RG, Dhurandhar NR. Fine-needle aspiration biopsy. *Laryngoscope* 2001; 111: 1551-7.
7. Fernández Villar A, Mosteiro Añon M, Corbacho Abelaira D, Acuña Fernández A, Piñeiro Amigo L. Pseudotumor inflamatorio pulmonar: presentación de dos casos y revisión de la literatura. *Anales de Medicina Interna* 1997; 14: 469-72.
8. Calleja Subirán C, Sesma Lamarque J, Aramendi T, Serrano Heranz R. Pseudotumor inflamatorio: presentación de dos casos. *Revista Clínica Española* 2001; 205: 290-2.
9. Takimoto T, Kathoh T, Kamide M, Nishimura T, Umeda R. Inflammatory pseudotumor of the maxillary sinus mimicking malignancy. *Rhinology* 1990; 28: 123-7.