

1-1-2008

Second-Hand Tobacco Smoke and Acute Eosinophilic Pneumonia

ZEKAİ AVCI

BÜLENT ALİOĞLU

EMEL ÖZYÜREK

NAMIK ÖZBEK

Follow this and additional works at: <https://journals.tubitak.gov.tr/medical>



Part of the [Medical Sciences Commons](#)

Recommended Citation

AVCI, ZEKAİ; ALİOĞLU, BÜLENT; ÖZYÜREK, EMEL; and ÖZBEK, NAMIK (2008) "Second-Hand Tobacco Smoke and Acute Eosinophilic Pneumonia," *Turkish Journal of Medical Sciences*: Vol. 38: No. 6, Article 17. Available at: <https://journals.tubitak.gov.tr/medical/vol38/iss6/17>

This Article is brought to you for free and open access by TÜBİTAK Academic Journals. It has been accepted for inclusion in Turkish Journal of Medical Sciences by an authorized editor of TÜBİTAK Academic Journals. For more information, please contact academic.publications@tubitak.gov.tr.

Second-Hand Tobacco Smoke and Acute Eosinophilic Pneumonia

Zekai AVCI

Bülent ALİOĞLU

Emel ÖZYÜREK

Namık ÖZBEK

Abstract: We present the case reports of two children with a parasitic infestation associated with hypereosinophilia. One of those patients, who had been exposed to excessive second-hand tobacco smoke, was diagnosed as having acute eosinophilic pneumonia. The second patient had neither a history of exposure to second-hand smoke nor a prior diagnosis of acute eosinophilic pneumonia. We suggest that passive smoking may trigger acute eosinophilic pneumonia, a condition that develops frequently in children living in countries in which parasitic infestations and tobacco smoking are prevalent.

Key Words: Acute eosinophilic pneumonia, smoking, hypereosinophilia

Pasif Sigara İçiciliği ve Akut Eozinofilik Pnömoni

Department of Pediatric Hematology,
Faculty of Medicine,
Başkent University,
Ankara - TURKEY

Özet: Burada parazit infestasyonu ve şiddetli eozinofilisi olan iki çocuk vaka sunulmuştur. Vakalardan biri aşırı sigara dumanına maruz kalmış ve bu hastada akut eozinofilik pnömoni gelişmiştir. Diğer hastada ise sigara maruziyeti olmamış ve akut eozinofilik pnömoni gelişmemiştir. Akut eozinofilik pnömoninin, parazit infestasyonlarının ve sigara içiciliğinin yaygın olduğu toplumlarda sık görülebileceğini ve pasif sigara içiciliğinin akut eozinofilik pnömonide tetiği çeken önemli bir faktör olduğunu düşünmekteyiz.

Anahtar Sözcükler: Akut eozinofilik pnömoni, sigara, hipereozinofili

Introduction

Acute eosinophilic pneumonia (AEP) is characterized by acute severe respiratory failure, hypoxia associated with diffuse lung infiltrates that are visible on chest radiographs, and pulmonary eosinophilia (1,2). AEP may be mistaken for infectious pneumonia, especially when eosinophilia is not identified in blood analysis at the time of the patient's presentation. Intervention with corticosteroids results in a rapid reversal of respiratory failure and complete recovery without recurrence of disease (2). We present the case reports of two children with hypereosinophilia. One of those patients, who had been exposed to excessive passive tobacco smoke, was diagnosed as having AEP. The second patient had neither a history of passive smoking nor a prior diagnosis of AEP.

Received: April 03, 2008
Accepted: September 03, 2008

Case Reports

Case 1

A 3.5-year-old male patient with a six-hour history of fever, cough, and progressive dyspnea was admitted to our emergency department. He was the second child born to second-degree consanguineous parents in a poor socioeconomic environment. There was no tobacco smoker in the family. However, one day before his admission to the hospital, there had been many guests at his home, and he had been exposed to heavy cigarette smoke. There was no previous history of foreign-body aspiration, bronchial asthma, or atopic dermatitis. He had a history of recurrent pruritus, the cause of which was determined to be an insect bite six months earlier, for which he had been treated with antihistaminic drugs during the six months before his admission to our hospital.

Correspondence

Zekai AVCI

Department of Pediatric
Hematology,

Faculty of Medicine,

Başkent University,

6. Cad. No: 72/3

06490 Bahçelievler,

Ankara - TURKEY

zekaiavci@yahoo.com

The patient exhibited peroral cyanosis and moderate respiratory distress at the time of admission. His axillary body temperature was 38.1°C, heart rate 128 bpm, and respiratory rate 48 breaths per minute. Intercostal and subcostal retractions were noted. Auscultation of the chest revealed bilateral wheezes and crackles in the bases of the lungs. During dermatologic examination, pleomorphic lesions with excoriations, scars, and small papules all over the trunk and lower extremities were identified. The rest of the physical examination was normal. The patient's transcutaneous oxygen saturation was 85%.

The initial complete blood count revealed the following values: hemoglobin, 11.4 g/dl; hematocrit, 34.4%; platelet count, $381 \times 10^9/L$; and white blood cell (WBC) count, $35.7 \times 10^9/L$, with a differential of 60% eosinophils (absolute eosinophil count [AEC], $21.4 \times 10^9/L$), 24% neutrophils, and 16% lymphocytes. C-reactive protein level was 8 mg/L (normal range, 0-6 mg/L). The results of serum biochemical studies and urinalysis were within the normal range. Serum immunoglobulin E level was 554.7 IU/ml (normal range, 32-128 IU/ml). Bone marrow examination showed marked eosinophilia (46%) without atypical cells. Radiographic and computerized tomographic studies of the chest revealed bilateral peripheral nodules and a ground-glass appearance in the parenchyma of the lungs (Figure). We performed repeated microscopic

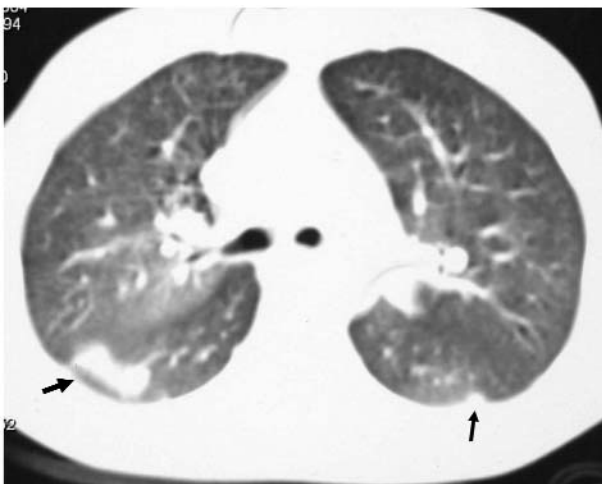


Figure. Computed tomographic scan of the chest shows bilateral peripheral nodules and a ground-glass appearance in the lung parenchyma.

examinations of the patient's feces. In the fourth fecal smear, *Ascaris lumbricoides* eggs were identified, and AEP associated with ascariasis was diagnosed.

The patient was treated with nasal oxygen and intravenously administered methylprednisolone 2 mg/kg/d in three divided doses. A rapid clinical improvement was noted; after 12 hours of corticosteroid treatment, his respiratory rate was 34 breaths per minute, and the retractions and symptoms noted during auscultation had resolved. On the second day of the patient's hospitalization, his transcutaneous oxygen saturation value was 98%, and treatment with nasal oxygen was terminated. Oral albendazole 400 mg administered once daily was added to the treatment regimen. On the sixth day, WBC count decreased to $15.1 \times 10^9/L$ with 18% eosinophils (AEC, $2.7 \times 10^9/L$). The patient was discharged seven days after his admission, and the dosage of methylprednisolone was reduced daily until it was terminated. At the follow-up visit 15 days after discharge from the hospital, his leukocytosis and hypereosinophilia had resolved completely (WBC count, $6.7 \times 10^9/L$; AEC, $0.26 \times 10^9/L$), and corticosteroid treatment was stopped. During the one-year follow-up, no symptoms had recurred.

Case 2

A 4.5-year-old male patient with fever and leukocytosis was referred to our hospital. He had no history of allergic disease, cough, dyspnea, exposure to cigarette smoke, or treatment with any medication. His body temperature was 37.5°C. Physical examination results of all systems were within normal limits. Laboratory analyses revealed the following values: hemoglobin, 11.5 g/dl; hematocrit, 35.2%; platelet count, $313 \times 10^9/L$; and WBC count, $64.2 \times 10^9/L$, with a differential of 77% eosinophils (AEC, $49.4 \times 10^9/L$), 14% lymphocytes, 7% neutrophils, and 2% monocytes. C-reactive protein was 7 mg/L. Bone marrow examination showed marked eosinophilia (47%) without atypical cells. Chest radiography, abdominal ultrasonography and cardiac echocardiography were normal. Tests for markers of infection, including those for hepatitis A, B, and C, cytomegalovirus, Epstein-Barr virus, toxoplasma, salmonella, and brucella, were negative. Microscopic examination of the patient's feces revealed *Giardia lamblia*

cysts and trophozoites. His eosinophilia was thought to be associated with his giardial infection. He was treated with metronidazole 30 mg/kg/d in three divided doses and oral methylprednisolone 1 mg/kg/d once daily. On the third day of that treatment, his WBC count had decreased to $12.2 \times 10^9/L$, the eosinophil percentage had decreased to 24% (AEC, $2.9 \times 10^9/L$), and corticosteroid therapy was terminated. After 10 days of treatment with metronidazole, his eosinophil percentage decreased to 16% (AEC, $1.7 \times 10^9/L$), and at the time of his two-month follow-up examination, that value was 7% (AEC, $0.52 \times 10^9/L$). During the eight months of follow up, no symptoms had recurred.

Discussion

Acute eosinophilic pneumonia is characterized by eosinophilic infiltration of the lung, respiratory distress, fever, a rapid response to corticosteroid therapy, and absence of recurrent disease. Leukocytosis is common; however, peripheral blood eosinophilia is often absent. The radiographic manifestations of AEP include diffuse bilateral infiltrates, pleural effusion, peripheral ground-glass attenuation, defined nodules, smooth interlobular septal thickening (Kerley B lines), and absence of cardiac enlargement (3). Blood eosinophilia with radiologic features is sufficient for the diagnosis of AEP. If blood eosinophilia is absent, eosinophilia exhibited in bronchoalveolar lavage (BAL) fluid or lung biopsy may help in the diagnosis. Case 1 demonstrated fever, progressive respiratory distress, and significant eosinophilia in smears of peripheral blood and bone marrow. Signs of AEP were evident in computed tomographic studies of the chest. His response to steroid treatment was characteristically excellent, and no recurrence of disease was identified at the one-year follow-up examination.

The causes of hypereosinophilia and eosinophilic pneumonia, which are many and varied, include infections (parasitic [e.g., ascariasis, strongyloidiasis], fungal, and those caused by micro-organisms such as *Pneumocystis carinii*), inhaled agents (e.g., tobacco smoke, gasoline, tear gas), drugs such as minocycline, systemic vasculitis, hematologic malignancies, Churg-Strauss syndrome, and

systemic idiopathic eosinophilic disorders. In our patients, we identified infection with *Ascaris* or *Giardia* as the cause of hypereosinophilia. Case 1 was also exposed to heavy cigarette smoke one day before his admission to the hospital. His recent six-month history of recurrent pruritus and the allergic rash noted during his physical examination suggested that his ascariasis had existed for a long time. However, the pneumonia developed on the day after this patient was exposed to heavy cigarette smoke. Case 2 did not exhibit lung infiltration, despite having higher AECs than those found in Case 1. We suggest that the exposure to cigarette smoke triggered AEP in the first patient.

The relation between cigarette smoke and AEP has been reported in the literature. AEP developed two days after cigarette smoking in an 18-year-old patient and two weeks after smoking in a 15-year-old patient (4,5). In a study by Nakajima et al. (6), AEP secondary to smoking was demonstrated by a challenge test. Those authors described a 23-year-old patient in whom pneumonia developed three weeks after the initiation of smoking and resolved after the patient stopped smoking. The challenge test also showed that smoking causes significant eosinophilia that is revealed in peripheral blood smears and that eosinophilia improves when the smoking habit is given up. Taniguchi et al. (7) reported a 21-year-old Japanese female patient whose symptoms of AEP developed one week after she began smoking. However, lymphocytic activation and an increased level of interleukin-5 (IL-5) were detected in the BAL fluid of that patient. In a study described by Godding et al. (8), a 14-year-old patient with AEP had started smoking tobacco two weeks before the onset of symptoms. In that patient, increased levels of eosinophil cationic protein, IL-5, and granulocyte-macrophage colony-stimulating factor were detected in the BAL fluid and pleural fluid. Although Case 1 in the current report did not smoke cigarettes, he had been exposed to heavy smoke one day before the onset of symptoms.

In summary, we suggest that passive smoking may trigger AEP, and that this response to second-hand smoke may occur frequently in children living in a country in which parasitic infections and tobacco smoking are prevalent.

References

1. Allen JN, Pacht ER, Gadek JE, Davis WB. Acute eosinophilic pneumonia as a reversible cause of noninfectious respiratory failure. *N Engl J Med* 1989; 321: 569-74.
2. Pope-Harman AL, Davis WB, Allen ED, Christoforidis AJ, Allen JN. Acute eosinophilic pneumonia. A summary of 15 cases and review of the literature. *Medicine (Baltimore)* 1996; 75: 334-42.
3. Johkoh T, Müller NL, Akira M, Ichikado K, Suga M, Ando M et al. Eosinophilic lung diseases: diagnostic accuracy of thin-section CT in 111 patients. *Radiology* 2000; 216: 773-80.
4. Sasaki T, Nakajima M, Kawabata S, Miyashita N, Kobashi Y, Niki Y et al. Acute eosinophilic pneumonia induced by cigarette smoke. *Nihon Kyobu Shikkan Gakkai Zasshi* 1997; 35: 89-94. [English abstract]
5. Sakamoto Y, Kuriwaka R, Tohjima A, Miura S. Acute eosinophilic pneumonia induced by cigarette smoking—a challenge test utilizing another brand of cigarette. *Nihon Kokyuki Gakkai Zasshi* 2000; 38: 466-70. [English abstract]
6. Nakajima M, Yoshida K, Miyashita N, Niki Y, Matsushima T. Eosinophilia and cough induced by resumption of cigarette smoking in a beginning smoker recovering from acute respiratory failure. *Nihon Kokyuki Gakkai Zasshi* 1999; 37: 543-8. [English abstract]
7. Taniguchi H, Kadota J, Fujii T, Matsubara Y, Katoh S, Mukae H et al. Activation of lymphocytes and increased interleukin-5 levels in bronchoalveolar lavage fluid in acute eosinophilic pneumonia. *Eur Respir J* 1999; 13: 217-20.
8. Godding V, Bodart E, Delos M, Sibille Y, Galanti L, De Coster P et al. Mechanisms of acute eosinophilic inflammation in a case of acute eosinophilic pneumonia in a 14-year-old girl. *Clin Exp Allergy* 1998; 28: 504-9.