

1-1-2008

Is Cervicotomy Enough for Removal of Retrosternal Goiters?

BERKANT ÖZPOLAT

OKTAY BÜYÜKAŞIK

CELAL GÖKHAN OSMANOĞLU

SÜHEYLA DOĞAN

HÜLAGÜ KARGICI

Follow this and additional works at: <https://journals.tubitak.gov.tr/medical>



Part of the [Medical Sciences Commons](#)

Recommended Citation

ÖZPOLAT, BERKANT; BÜYÜKAŞIK, OKTAY; OSMANOĞLU, CELAL GÖKHAN; DOĞAN, SÜHEYLA; and KARGICI, HÜLAGÜ (2008) "Is Cervicotomy Enough for Removal of Retrosternal Goiters?," *Turkish Journal of Medical Sciences*: Vol. 38: No. 6, Article 10. Available at: <https://journals.tubitak.gov.tr/medical/vol38/iss6/10>

This Article is brought to you for free and open access by TÜBİTAK Academic Journals. It has been accepted for inclusion in Turkish Journal of Medical Sciences by an authorized editor of TÜBİTAK Academic Journals. For more information, please contact academic.publications@tubitak.gov.tr.

Is Cervicotomy Enough for Removal of Retrosternal Goiters?

Berkant ÖZPOLAT¹
Oktay BÜYÜKAŞIK²
Celal Gökhan OSMANOĞLU³
Süheyla DOĞAN⁴
Hülagü KARGICI²

Aim: The aim of this study was to evaluate the surgical approaches in retrosternal goiters.

Materials and Methods: We reviewed 23 patients operated with the diagnosis of retrosternal goiter. Twelve (52%) of the cases were female and 11 (48%) were male. Mean age was 53.8±10.9 years. Shortness of breath was seen in 12 (52%) of the patients as the most frequent preoperative symptom. On the chest posteroanterior radiography, 18 (78%) cases were found to have tracheal compression. CT images demonstrated retrosternal extension to the level of the aortic arch in all patients. All 23 patients were prepared for a thoracic approach.

Results: Among 448 cases operated with the diagnosis of goiter, 23 patients (5.1%) had evidence of retrosternal goiter. Of those 23 patients, only 10 had deep retrosternal extension of the goiter that actually required a thoracic approach, which accounted for 2.2% of all thyroidectomies performed. Total median sternotomy in seven cases, partial sternotomy in two cases and right thoracotomy in one case were performed. Hypoparathyroidism was not detected postoperatively and no hospital mortality occurred.

Conclusions: Goiters extending to the mediastinum can be excised successfully by cervical incision. Thoracic approach has an excellent outcome, achieving a safe resection and relieving all symptoms, especially in large or recurrent goiters extending to the mediastinum and with close relation to mediastinal structures.

Key Words: Goiter, intrathoracic, thyroid disease

¹ Department of Thoracic Surgery,
Faculty of Medicine,
Kırıkkale University,
Kırıkkale - TURKEY

² Department of General Surgery,
Dışkapı Yıldırım Beyazıt Training
and Research Hospital,
Ankara - TURKEY

³ Department of General Surgery,
Faculty of Medicine,
Kırıkkale University,
Kırıkkale - TURKEY

⁴ Department of Cardiovascular Surgery,
Dışkapı Yıldırım Beyazıt Training
and Research Hospital,
Ankara - TURKEY

Retrosternal Guatrların Çıkarılmasında Servikotomi Yeterli midir?

Amaç: Bu araştırmada retrosternal guatrlarda, cerrahi girişim yöntemlerinin değerlendirilmesi amaçlandı.

Yöntem ve Gereç: Retrosternal guatr tanısıyla opere edilen 23 hasta retrospektif olarak incelendi. Olguların 12'si kadın (% 52) ve 11'i (% 48) erkekti. Yaşları 28 ile 70 arasında değişmekte olup ortalaması 53.87±10.94 idi. En sık preoperatif semptom 12 olguda (% 52) nefes darlığı idi. En sık tespit edilen radyolojik bulgu 18 olguda (% 78) trakeaya bası idi. Akciğer bilgisayarlı tomografisi tüm hastalarda tiroid dokusunun arkus aortaya kadar uzandığını gösterdi. Tüm hastalar torasik yaklaşım yapılabilecek şekilde hazırlandı.

Bulgular: Guatr nedeniyle opere edilen 448 vakanın 23'ünde (% 5,1) retrosternal guatr saptandı. Bu 23 vakanın derin retrosternal yerleşim gösteren 10'unda (2,2%) torasik yaklaşım gerekti. Olguların 7'sinde servikal insizyonla birlikte total median sternotomi, 2'sinde parsiyel sternotomi ve birinde sağ torakotomi gerekti. Hipoparatiroidizm ve mortalite gelişmedi.

Sonuç: Mediastinal uzanım gösteren guatrlar servikal insizyonla başarılı bir şekilde çıkarılabilir. Mediastinal önemli yapılara komşuluk gösteren büyük ve rekürren mediastinal guatrlarda torasik yaklaşım, rezeksiyon güvenliği, tüm semptomların düzelmesi ile mükemmel sonuçlar sağlamıştır.

Anahtar Sözcükler: Guatr, intratorasik, tiroid hastalıkları

Received: March 05, 2008
Accepted: September 03, 2008

Introduction

A retrosternal goiter is defined as the situation in which at least 50% of the gland is located in the mediastinum as detected by computed tomography (CT) and operative findings (1,2). The incidence of this pathology ranges from 1.7% to 30%. Retrosternal goiters respond poorly to medical treatment and can cause acute airway symptoms. Surgical treatment should be considered in most cases (1,3).

Although extirpation of the gland is performed exclusively via a collar incision, the surgeon should be prepared for a thoracic approach especially in recurrent and/or huge

Correspondence

Berkant ÖZPOLAT
Department of Thoracic Surgery,
Faculty of Medicine,
Kırıkkale University,
Kırıkkale - TURKEY

berkantozpolat@yahoo.com

mediastinal thyroid masses, where removal is very difficult or risky (4-7). There is no clear distinction for determining the cases that require a thoracic approach. The aim of this study was to analyze the features of 23 patients with retrosternal goiter, in 10 of whom thoracic approach was added to cervical incision. This may present a pitfall for surgeons dealing with goiter in some regional hospitals.

Materials and Methods

Data charts of 448 patients undergoing thyroidectomy from October 2000 to December 2004 were reviewed, and 23 patients with retrosternal goiter were included in this study.

Their mean age was 53.8 ± 10.9 years (range: 28-70 years). Twelve (52%) were female and 11 (48%) were male.

Clinical features of patients are listed in Table 1. Five (22%) patients had wheezing and had been treated as bronchial asthma. Three (13%) had a previous thyroid surgery via cervical approach. Two (7%) of the 23 patients were operated after becoming euthyroid with antithyroid treatment. Postoperatively, all patients received thyroid replacement treatment for hypothyroidism.

Posteroanterior chest radiography, thyroid ultrasonography, CT of chest and neck, thyroid scintigraphy, and thyroid function tests were included in the preoperative workup of all 23 patients. In two cases, magnetic resonance imaging (MRI) was performed. The preoperative spirometric tests were repeated at the end of the first month. The presenting complaints, operative findings, pathologic diagnosis and postoperative

complications were analyzed. The Ethical Review Committee and Institutional Review Boards approved the study and all patients provided written informed consent.

One day before the operation, all 23 patients were prepared for a thoracic approach and a sternotomy set was provided in the operating theater; this is not available in all operating theaters in our country's hospitals. The operative procedure was started with cervical incision. Contrary to classical procedure, the medial portion of the gland was first dissected from the trachea. The sternocleidomastoid muscles were cut in most cases. Superior pole was ligated and cut, and medial and superior dissection was completed. Upward delivery of the gland was done by fingers and the gland was detached from all sides to reach the lower edge. If the gland could not be delivered by other blunt maneuvers, uncontrolled traction was avoided and median sternotomy performed.

Results

Among 448 patients, 23 (5.1%) presented with retrosternal extension of goiter. Of those 23 patients, only 10 had deep retrosternal extension of goiter that actually required a thoracic approach, which accounted for 2.2% of all thyroidectomies performed. In 13/23 patients, cervicotomy was used for removal of the retrosternal portion of the gland, 7/23 patients required total sternotomy, 2/23 required a partial sternotomy, and right posterolateral thoracotomy was performed in 1/23.

Preoperative posteroanterior chest radiography demonstrated tracheal compression and/or deviation in all the patients who underwent sternotomy or thoracotomy (Figure 1). CT images demonstrated retrosternal extension to the level of the aortic arch in all patients in this group as well (Figure 2). Thyroid scintigraphy demonstrated retrosternal extension in only four (17%) of the patients. Radiological characteristics of the patients are shown in Table 2. MRI demonstrated the close relationship to mediastinal structures in two patients (Figure 3).

Spirometry demonstrated medium obstructive and restrictive impairment in 15 (65%) patients, with significant improvement in the first postoperative month.

Histological examination revealed simple colloid goiter in all patients.

Table 1. Clinical features of patients (patients may have more than one clinical feature).

Clinical feature	No. of patients
Dyspnea	12 (52%)
Cough	5 (21%)
Dysphagia	1 (4%)
Visible upper chest veins	4 (16%)
Plethora	4 (16%)
Asymptomatic	3 (12%)

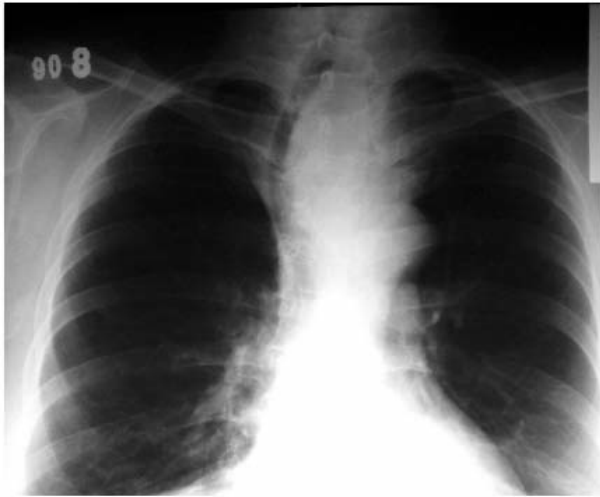

Figure 1. Posteroanterior chest radiography in a patient with tracheal deviation.

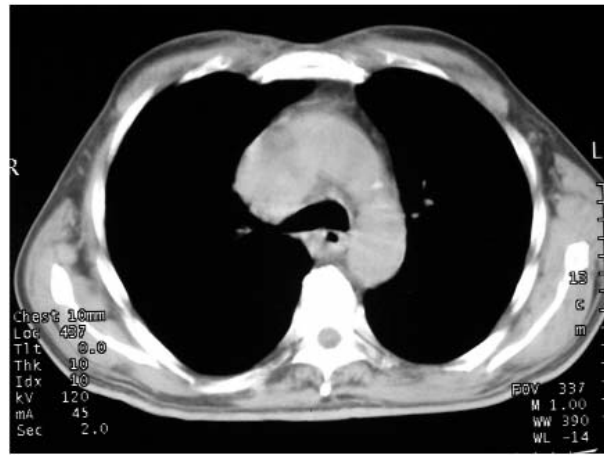

Figure 2. Computed tomography shows mediastinal extension of the gland.

Table 2. Radiological characteristics of the patients.

	Cervical incision alone	Sternotomy or thoracotomy
Tracheal compression and/or deviation (PA)	8	10 (100%)
Retrosternal extension to the level of aortic arch (CT)	none	10 (100%)
Scintigraphy demonstrating retrosternal extension	none	4 (40%)

One patient in whom only cervical incision was used was reoperated due to hematoma. Right recurrent nerve paralysis was seen in the patient who underwent thoracotomy. There was no mortality or significant morbidity in patients who underwent sternotomy.

Discussion

The management of a retrosternal goiter has challenged surgeons since its first description in 1749. The majority are large, benign masses found in the superior and anterior mediastinum, although from 3 to 15% can be malignant in nature (8).

The presenting symptoms are related to the compressive nature of the mass on nearby structures. Fifty to ninety percent of patients have some form of respiratory symptoms in association with these masses (8,9). In some cases, the diagnosis was bronchial asthma,

which is an initial false and long-lasting one (10). In our series, cough and dyspnea were seen in 73% of the patients, and significant improvement was obtained in the first month after surgery. Five patients whose initial diagnosis was asthma were free of all symptoms postoperatively. The decompression on the airway tract is important for most of the patients. Sternotomy may be considered as a simple and easy means to achieve this goal. In addition, the surrounding vascular structures and neovascularized capsule can be visualized without any difficulty.

CT and MRI are the techniques for detecting the presence and extent of retrosternal goiters and their relation to adjacent structures in the neck and chest and for determining if mediastinal masses are thyroidal in origin (11). In our series, CT of the neck and chest was routinely used for diagnosis, which was also helpful in decision-making, with operative findings, regarding

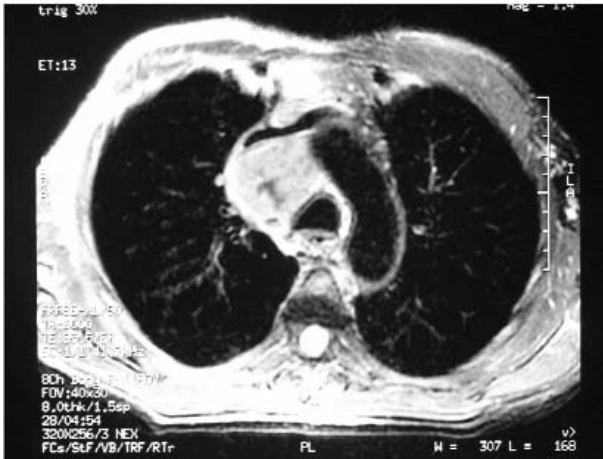


Figure 3. MRI demonstrating the close relationship to mediastinal structures.

thoracotomy and whether sternotomy should be partial or total. In two patients, partial sternotomy was sufficient for removal. MR similarly helped delineation of impingement on adjacent structures in two patients in whom the gland was located below the level of the aortic arch and posterior mediastinum.

Thyroid scans often fail to show the intrathoracic goiter (9). Retrosternal extension was demonstrated in only four (17%) patients in this series.

In the literature, the rate of sternotomy is reported up to 3.4% accounting for overall thyroidectomies performed (12). The rate of thoracic approach reported in this series was 2.2% (10/448). Most of these patients were referred to our hospital from places where thoracic approach was not possible. In the literature, in one report, despite the large size of goiters and the significant involvement of the major mediastinal structures, approach through the transcervical incision alone and in another, cervicotomy, with rare exceptions were reported to be sufficient without any major complications (13,14). As retrosternal goiters are supplied by vascular pedicles arising from the inferior thyroid artery, significant mediastinal bleeding is difficult to control from a cervical incision and sternotomy or even thoracotomy is essential (15). The mediastinal goiter is sometimes so

giant a mass that, despite the cervico-sternotomic approach, the mediastinal structures are distorted and the strong adherence between the anomalous neovascularized capsule of the mass and the surrounding structures may complicate the surgical dissection (16). In our series, there was no solid criteria for selecting patients who would likely require thoracic approach, and among 23 patients, 10 required a thoracic approach. Thoracic approach is important to minimize the bleeding due to vascular damage. The fact that one of the patients with retrosternal goiter in whom cervicotomy alone was preferred required reoperation due to bleeding is particularly noteworthy.

Despite the clinical and radiological features of retrosternal goiters that suggest the need for thoracic approach, a cervicotomy may be enough in most of the patients. A highly selected group of patients with strong indications for thoracic approach, i.e. extension to the aortic arch, huge and recurrent goiters, extension to the posterior mediastinum, and demonstrated tracheal compression and/or deviation, should be identified preoperatively, and a sternotomy set should be kept ready in the operating theater.

The difficulties in retrosternal goiter surgery have been explained in the literature. Attention should be paid to some essential steps of general anesthesia such as intubation period, patient position and monitoring (17). In our series, smaller size endotracheal tubes were preferred in patients with respiratory symptoms. No difficulties during intubation were observed. Sudden or progressive development of retrosternal goiters often leads to compression of the trachea and, although rare, tracheomalacia needs to be watched for postoperatively (8). We did not diagnose tracheomalacia in any of the patients.

In conclusion, patients with huge and recurrent goiters extending to the level of the aortic arch may require thoracic approach to achieve a safe resection and decompression of some adjacent structures with minimal morbidity. Surgeons should be aware of the situations in which there is increased likelihood of the need for a thoracic approach.

References

1. Singh B, Lucente FE, Shaha AR. Substernal goiter: a clinical review. *Am J Otolaryngol* 1994; 15(6): 409-16.
2. Monchik JM, Materazzi G. The necessity for a thoracic approach in thyroid surgery. *Arch Surg* 2000; 135(4): 467-71.

3. Porzio S, Marocco M, Oddi A, Lombardi V, Porzio O, Calvelli C et al. Endothoracic goitre: anatomoclinical and therapeutic considerations. *Chir Ital* 2001; 53(4): 453-60.
4. Mussi A, Ambrogi MC, Iacconi P, Spinelli C, Miccoli P, Angeletti CA. Mediastinal goitres: when the transthoracic approach? *Acta Chir Belg* 2000; 100(6): 259-63.
5. Sianesi M, Del Rio P, Arcuri MF, Soliani P, Rusca M. Cervico-mediastinal goiter. *Chir Ital* 2002; 54(1): 15-8.
6. Katlic MR, Wang CA, Grillo HC. Substernal goiter. *Ann Thorac Surg* 1985; 39(4): 391-9.
7. Latteri S, Saita S, Potenza E. Intrathoracic goiter: experience with 61 surgically treated cases. *Chir Ital* 2000; 52(2): 139-45.
8. Newman E, Shaha AR. Substernal goiter. *J Surg Oncol* 1995; 60(3): 207-12.
9. Sanders LE, Rossi RL, Shahian DM, Williamson WA. Mediastinal goiters. The need for an aggressive approach. *Arch Surg* 1992; 127(5): 609-13.
10. Vadasz P, Kotsis L. Surgical aspects of 175 mediastinal goiters. *Eur J Cardiothorac Surg* 1998; 14(4): 393-7.
11. Jennings A. Evaluation of substernal goiters using computed tomography and MR imaging. *Endocrinol Metab Clin North Am* 2001; 30(2): 401-14.
12. Ahmed ME, Ahmed EO, Mahadi SI. Retrosternal goiter: the need for median sternotomy. *World J Surg* 2006; 30(11): 1945-8.
13. Netterville JL, Coleman SC, Smith JC, Smith MM, Day TA, Burkey BB. Management of substernal goiter. *Laryngoscope* 1998; 108(11 Pt 1): 1611-7.
14. Hedayati N, McHenry CR. The clinical presentation and operative management of nodular and diffuse substernal thyroid disease. *Am Surg* 2002; 68(3): 245-51.
15. Kaya S, Tastepe I, Kaptanoğlu M, Yuksel M, Topcu S, Cetin G. Management of intrathoracic goitre. *Scand J Thorac Cardiovasc Surg* 1994; 28(2): 85-9.
16. Veronesi G, Leo F, Solli PG, D'Aiuto M, D'Ovidio F, Mazzarol G et al. Life-threatening giant mediastinal goiter: a surgical challenge. *J Cardiovasc Surg (Torino)* 2001; 42(3): 429-30.
17. Ercolani E, Pecetta C. Anesthesiology problems in the surgery of cervico-mediastinal goiter. Our clinical experience. *Minerva Anestesiol* 1992; 58(4): 159-63.