

1-1-2008

Is CD117 Expression Related with Plasma Cell Differentiation, IRF4/MUM1 and CD38 Expressions in Lymphoid Neoplasms?

GÜLŞAH KAYGUSUZ

İŞINSU KUZU

SABA KİREMİTÇİ

DUYGU KANKAYA

ZEYNEP BIYIKLI

Follow this and additional works at: <https://journals.tubitak.gov.tr/medical>



Part of the [Medical Sciences Commons](#)

Recommended Citation

KAYGUSUZ, GÜLŞAH; KUZU, İŞINSU; KİREMİTÇİ, SABA; KANKAYA, DUYGU; and BIYIKLI, ZEYNEP (2008) "Is CD117 Expression Related with Plasma Cell Differentiation, IRF4/MUM1 and CD38 Expressions in Lymphoid Neoplasms?," *Turkish Journal of Medical Sciences*: Vol. 38: No. 6, Article 2. Available at: <https://journals.tubitak.gov.tr/medical/vol38/iss6/2>

This Article is brought to you for free and open access by TÜBİTAK Academic Journals. It has been accepted for inclusion in Turkish Journal of Medical Sciences by an authorized editor of TÜBİTAK Academic Journals. For more information, please contact academic.publications@tubitak.gov.tr.

Is CD117 Expression Related with Plasma Cell Differentiation, IRF4/MUM1 and CD38 Expressions in Lymphoid Neoplasms?

Gülşah KAYGUSUZ¹

Işınso KUZU¹

Saba KİREMİTÇİ¹

Duygu KANKAYA¹

Zeynep BIYIKLI²

Aim: In this study, we aimed to assess the expression of CD117 in a large series of both Hodgkin's and non-Hodgkin's lymphoma, and to investigate the association between the expression patterns of CD117, IRF4/MUM1, and CD38.

Materials and Methods: A total of 237 lymphoma cases were selected and examined within six tissue microarray paraffin blocks. Immunohistochemistry was performed using antibodies against CD117, IRF4/MUM1 and CD38.

Results: CD117 and IRF4/MUM1 immunoreactivity were seen in a subset of high-grade and low-grade B-cell lymphomas, as well as T-cell lymphomas and classical type Hodgkin's lymphomas. CD38 positivity was only detected in 1% of diffuse large B-cell lymphoma and 66% of precursor B-lymphoblastic lymphoma, in addition to myeloma cases. CD117 expression was not correlated with IRF4/MUM1 expression ($P > 0.05$). Two of three CD38- positive cases were positive for CD117.

Conclusions: These results suggest that CD117 expression can be seen in a subset of T- or B- cell lymphoid neoplasms and plasma cell myelomas. It seems that there is no relation between the expression of CD117 and plasma cell differentiation markers in lymphomas.

Key Words: CD117 expression, lymphoma, CD38 reactivity, plasma cell differentiation, IRF4/MUM1 expression

¹ Department of Pathology,
School of Medicine,
Ankara University,
Ankara - TURKEY

² Department of Biostatistics,
School of Medicine,
Ankara University,
Ankara - TURKEY

Lenfoid Neoplazmlarda CD117 Ekspresyonu, Plazma Hücre Diferansiyasyonu, IRF4/MUM1 ve CD38 Ekspresyonları ile İlişkili midir?

Amaç: Biz bu çalışmada, geniş bir Hodgkin ve non-Hodgkin lenfoma serisinde CD117 ekspresyonunu değerlendirmeyi; CD117, IRF4/MUM1 ve CD38 ekspresyon patternleri arasındaki ilişkiyi araştırmayı amaçladık.

Yöntem ve Gereç: Toplam 237 lenfoma vakası seçildi ve bu vakalardan 6 adet doku mikroarray paraffin bloğu hazırlandı. CD117, IRF4/MUM1 ve CD38 antikorları kullanılarak immunohistokimyasal inceleme yapıldı.

Bulgular: CD117 ve IRF4/MUM1 ekspresyonu bir grup düşük ve yüksek dereceli B hücreli lenfomalar yanında; T hücreli lenfomalar ve Hodgkin lenfomalarda da gözlemlendi. CD38 pozitifliği, myeloma vakaları yanında diffüz büyük B hücreli lenfoma'ların yalnızca % 1'inde ve prekürsör B lenfoblastik lenfoma'ların % 66'ında görüldü. CD117 ekspresyonu, IRF4/MUM1 ekspresyonu ile korele bulunmadı ($P > 0.05$). CD38 pozitif 3 vakanın 2'sinde CD117 pozitif bulundu.

Sonuç: Bu bulgular, CD117 ekspresyonunun bir grup T veya B hücreli lenfoid neoplazmlarda ve plazma hücreli myelomalarda görülebileceğini düşündürmektedir. Lenfomalarda, CD117 ekspresyonu ve plazma hücre diferansiyasyonu belirleyicileri arasında bir ilişki bulunmamıştır.

Anahtar Sözcükler: CD117 ekspresyonu, lenfoma, CD38 reaktivitesi, plazma hücre diferansiyasyonu, IRF4/MUM1 ekspresyonu

Received: July 28, 2008
Accepted: October 21, 2008

Correspondence

Gülşah KAYGUSUZ

Department of Pathology,
School of Medicine,
Ankara University,
Ankara - TURKEY

gulsah@gmail.com

Introduction

The c-kit proto-oncogene (KIT, CD117) is a transmembrane tyrosine kinase that is expressed in various cell types, including hematopoietic stem cells, germ cells, mast cells, melanocytes and the interstitial cells of Cajal (1). CD117 expression has been documented in a variety of neoplasms, including gastrointestinal stromal tumors (GIST), germ cell tumors, mast cell neoplasms, and a variety of solid tumors. CD117 expression

in malignant tumors is an important target for an innovative therapeutical approach enrolling the kinase inhibitor STI571. Mature B- and T-cells do not express CD117, whereas a subset of mature natural killer cells do (2). CD117 is expressed in a variety of hematopoietic neoplasms, including acute and chronic myeloid leukemias (1), granulocytic sarcomas (3), systemic mastocytosis (4), T-cell acute lymphoblastic leukemia (5), and multiple myeloma (6). However, there are contradicting results with different antibodies regarding its expression in lymphomas. To date, very rare cases of CD117-positive diffuse large B-cell lymphoma with no activating mutations of the *c-kit* gene have been reported. Similarly controversial results have been obtained with Hodgkin's lymphoma, ranging from 0% to 52% (7). CD117 expression has also been reported in rare cases of follicular lymphoma (8) and of mantle cell lymphoma (9,10).

The determination of plasma cell differentiation in B-cell lymphomas is important for classification and prediction of biologic behavior. IRF4/MUM1, as a marker for a fraction of germinal center-B cells and plasma cells, can be expressed on especially postgerminal center B-cell lymphomas. Several lymphoid neoplasms may express plasma cell-associated markers such as CD38, CD138 or IRF4/MUM1.

The aims of our study were to assess the expression of CD117 in a series of both classical type of Hodgkin's and non-Hodgkin's lymphoma (NHL) using tissue microarray (TMA) technology and to investigate the association between the expression of CD117 and plasma cell-associated markers, such as IRF4/MUM1 and CD38.

Materials and Methods

Patients

A total of 237 cases diagnosed according to the World Health Organization (WHO) classification (11) were: diffuse large B-cell lymphoma (DLBCL) ($n = 104$); chronic lymphocytic leukemia/small lymphocytic lymphoma (CLL/SLL) ($n = 15$); follicular lymphoma (FL) ($n = 18$); mantle cell lymphoma (MCL) ($n = 11$); nodal marginal zone lymphoma (MZL) ($n = 7$); Burkitt's lymphoma (BL) ($n = 6$); precursor B-lymphoblastic lymphoma ($n = 3$); precursor T-lymphoblastic lymphoma ($n = 4$); peripheral T-cell lymphoma ($n = 13$); mycosis fungoides (MF) ($n = 8$); classical type of Hodgkin's lymphoma (CHL) ($n = 45$);

and anaplastic large cell lymphoma (ALCL) ($n = 3$). Six cases of plasma cell myeloma (PCM) were also included.

Immunohistochemistry

Surgical specimens were fixed in neutral buffered formalin and embedded in paraffin. 4-5 μm thick tissue sections stained with routine hematoxylin and eosin (H&E) were reviewed. The six TMA paraffin blocks containing 237 well-documented cases of CHL and NHL were constructed using an instrument (Beecher Instruments, Silver Spring, MD, USA). Tissue cores of 0.6 mm were punched.

Immunohistochemistry was performed using antibodies against CD117 (Novocastra, T595, 1:50) that recognize an epitope on the extracellular domain of CD117, IRF4/MUM1 (DAKO, Mum1p, 1:50), and CD38 (Neomarkers, Labvision, 38CO3, 1:100) with either Zymed ABC Px Kit or Ventana Benchmark automated immunostainer for secondary visualization. Negative control was performed for each experiment. The cytoplasmic expressions of CD117 and CD38 were scored as positive or negative. IRF4/MUM1 expression was seen in nuclear pattern and scored as positive or negative.

Data Analysis

The results were evaluated by the Chi-square test. P values less than 0.05 were considered significant.

Results

CD117, IRF4/MUM1 and CD38 expression profile of the cases is demonstrated in Table 1. CD117 immunoreactivity was seen in 12 of 104 DLBCLs (11%) (Figure 1A,C,D,F), 3 of 28 T-cell lymphomas (19%) (1 with ALCL, 2 with peripheral T-cell lymphoma) (Figure 2D,F), and 3 of 45 CHLs (7%) (Figure 2A,C). Other B-cell NHLs showed different CD117 reactivity (2 of 15 SLL/CLLs, 4 of 18 FLs, 2 of 11 MCLs, 1 of 7 nodal MZLs, 2 of 6 BLs, 2 of 3 precursor B-lymphoblastic lymphomas). Four of 6 PCM cases were positive for CD117 (Figure 3A,C). All precursor T-lymphoblastic lymphoma and MF cases were negative for CD117.

IRF4/MUM1 expression was seen in 40 of 104 DLBCLs (38%) (Figure 1B,E), 35 of 45 CHLs (78%) (Figure 2B), 2 of 18 FLs (11%), 1 of 11 MCLs (9%), 1 of 7 nodal MZLs (14%), 6 of 13 peripheral T-cell lymphomas (46%), and 2 of 3 ALCLs (67%) (Figure 2E). Six cases of PCM showed IRF4/MUM1 expression (Figure 3B).

Table 1. CD117, MUM1 and CD38 expression status of the cases.

Lymphoma	Punches (n) (n)	Evaluable cases (n)	CD117 (+) (n,%)	MUM1 (+) (n,%)	CD38 (+) (n,%)
DLBCL	198	104	12 (11%)	40 (38%)	1 (1%)
FL	35	18	4 (22%)	2 (11%)	0
CHL	96	45	3 (7%)	35 (78%)	0
PTCL,NOS	31	13	2 (15%)	6 (46%)	0
SLL/CLL	28	15	2 (13%)	0	0
BL	13	6	2 (33%)	0	0
PBLBL	6	3	2 (66%)	0	2 (67%)
PTLBL	9	4	0	0	0
MCL	21	11	2 (18%)	1 (9%)	0
Nodal MZL	13	7	1 (14%)	1 (14%)	0
ALCL	8	3	1 (33%)	2 (67%)	0
MF	21	8	0	0	0
Total	527	237	35 (14%)	87 (36%)	3 (1%)

DLBCL: diffuse large B-cell lymphoma; FL: follicular lymphoma; CHL: classical type of Hodgkin's lymphoma; PTCL, NOS: peripheral T-cell lymphoma, unspecified; SLL/CLL: small lymphocytic lymphoma/chronic lymphocytic leukemia; BL: Burkitt's lymphoma; PBLBL: precursor B-lymphoblastic lymphoma; PTLBL: precursor T-lymphoblastic lymphoma; MCL: mantle cell lymphoma; MZL: marginal zone lymphoma; ALCL: anaplastic large cell lymphoma; MF: mycosis fungoides.

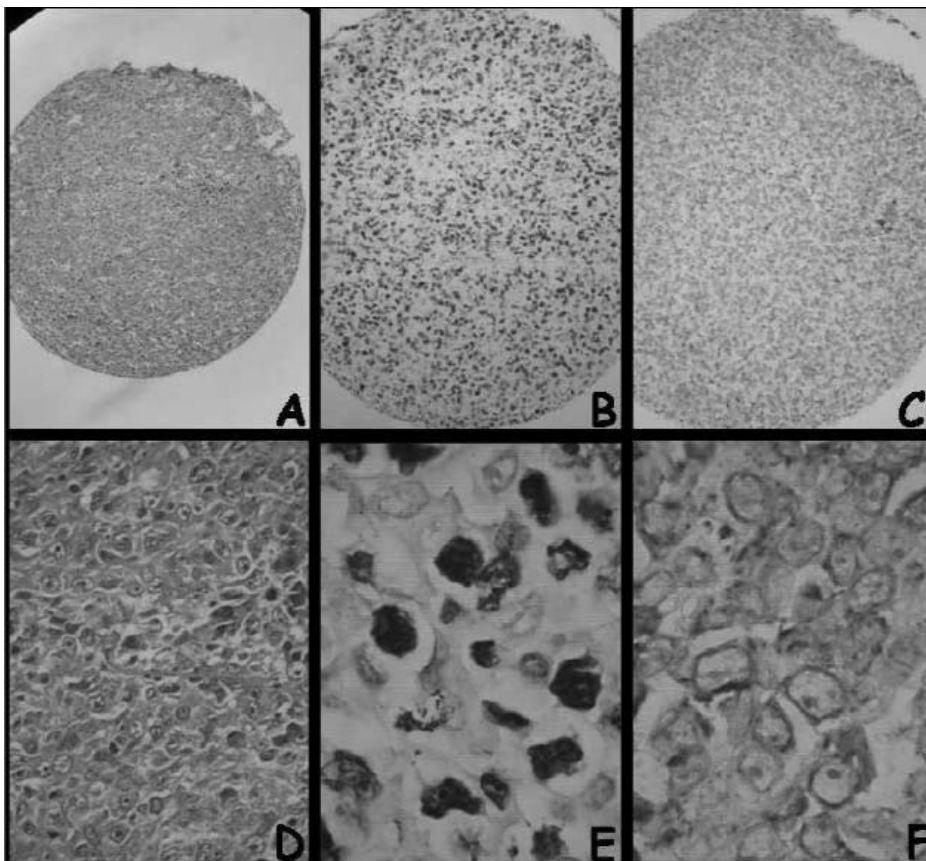


Figure 1. A case of diffuse large B-cell lymphoma. (A, D): Hematoxylin and eosin (H&E) staining ($\times 100$, $\times 400$). CD117 (C, F) and MUM1 (B, E) positivity of the tumor cells ($\times 200$, $\times 1000$).

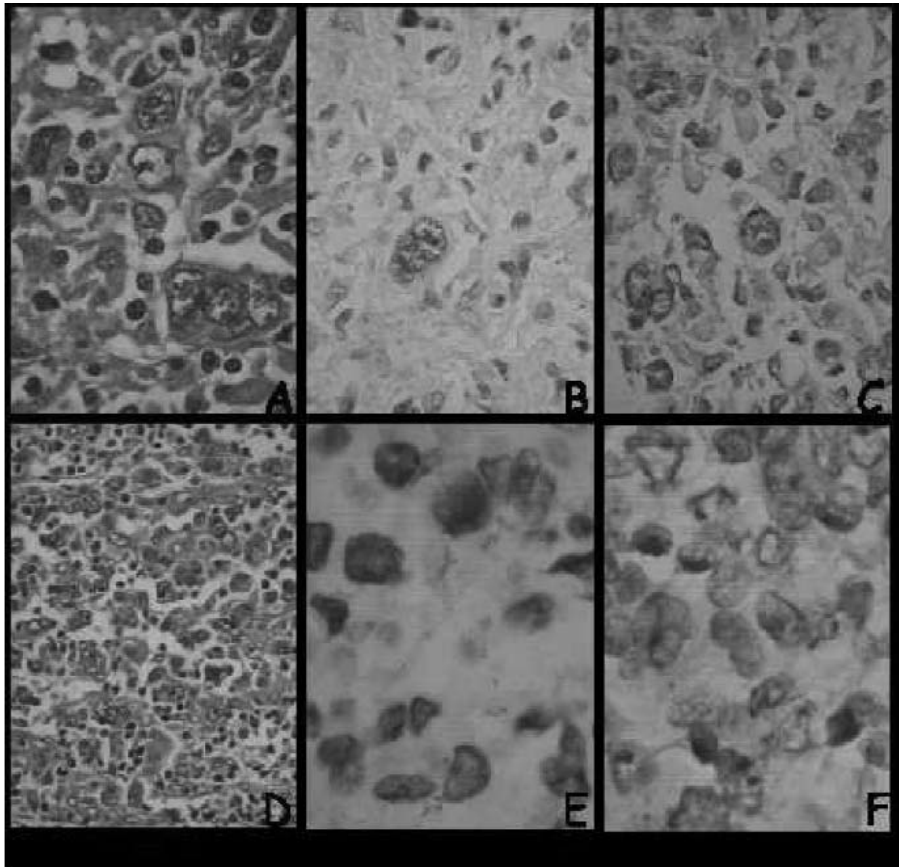


Figure 2. Atypical Reed-Sternberg cells in classical type of Hodgkin's lymphoma (H&E, $\times 400$) (A), expressing IRF4/MUM1 ($\times 400$) (B) and CD117 ($\times 400$) (C). Neoplastic cells in an anaplastic large cell lymphoma case (H&E, $\times 200$) (D), expressing IRF4/MUM1 ($\times 1000$) (E) and CD117 ($\times 1000$) (F).

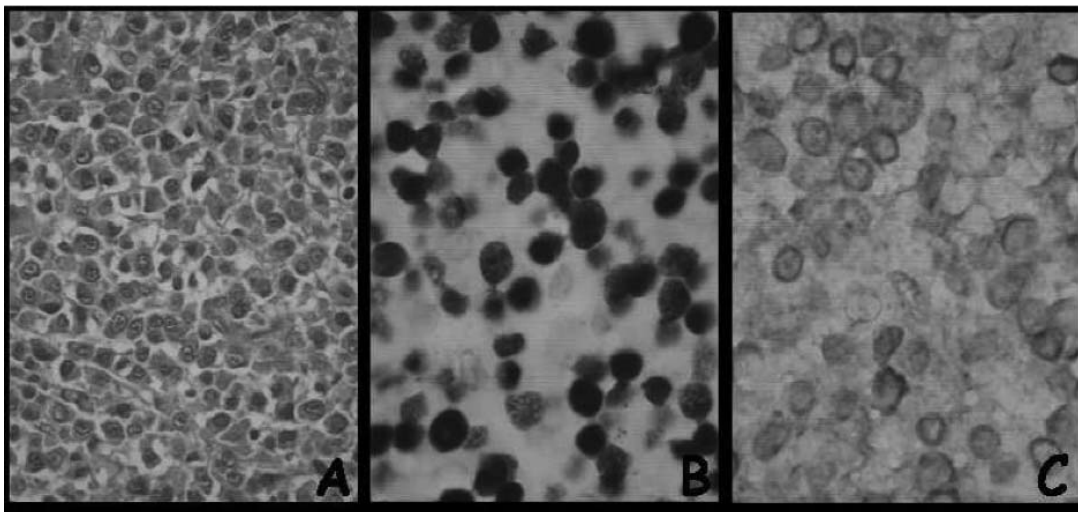


Figure 3. Neoplastic plasma cells (H&E, $\times 400$) (A), stained with IRF4/MUM1 ($\times 1000$) (B) and CD117 ($\times 1000$) (C).

Only 3 cases, 1 with DLBCL and 2 with precursor B-lymphoblastic lymphoma, showed CD38 expression in addition to myeloma cases.

CD117 expression was not correlated with IRF4/MUM1 expression ($P > 0.05$). Two of 3 CD38-positive cases were positive for CD117 ($P = 0.006$, kappa value = 0.099).

Discussion

Although there are a limited number of studies, controversial results with different antibodies for CD117 have been obtained with CHLs and NHLs. CD117 immunoreactivity in CHLs has been reported, ranging from 0-52% (2,7,12). Our results confirm the previous reports of the rarity of CD117 expression in CHLs (7%).

CD117 expression seems to be rare in DLBCL. Recently, Zimpfer et al. (2) and Vakiani et al. (10) reported a lack of CD117 expression by using A4502 antibody in 385 and 74 cases of DLBCL, respectively, whereas Vakiani et al. found 21 CD117-positive cases by using Ab-1 antibody in the same study. We identified 12 cases of CD117-positive DLBCL (11%) with monoclonal T595 antibody in our series.

Only rare cases of CD117-positive low-grade B-cell NHL have been reported. CD117 reactivity was determined in rare cases of MCL (9), a single case of FL with t(14:18) (8), and 2 cases of CLL and 1 with MZL (1). In our series, we found 2 cases of CLL/SLL, 4 cases of FL, 2 cases of MCL, and 1 case of nodal MZL expressing CD117. In another study, 11 of 16 ALCLs (69%) and 1 of 7 (14%) BLs were positive for CD117 (7), while Tomeczkowski et al. (14) reported 7 CD117-negative BLs. We determined that 1 case of ALCL and 2 cases of BL were CD117-positive. It seems that the main explanation for the different results on CD117 immunohistochemistry in lymphomas is the use of different antibodies for CD117.

To date, there is no reported case of CD117-positive precursor B-lymphoblastic lymphoma. In our study, CD117 expression was found in 2 of 3 precursor B-lymphoblastic lymphomas. It has been reported that a subset of peripheral T-cell lymphomas can express CD117, by carrying c-kit mutations in exon 11 and 13 (1). Brauns et al. (16) reported that primary cutaneous CD30-positive ALCLs, primary cutaneous T-cell lymphomas and MF cases may express CD117 as well. In

the current study, CD117 positivity was seen in 2 of 13 cases of peripheral T-cell lymphomas and 1 case of ALCL, consistent with the previous findings.

There are a few studies in the literature addressing CD117 expression in PCM. The clinical implications of CD117 expression in PCM have not been reported thus far. CD117 immunoreactivity has been reported in PCM, ranging from 3-35%, by immunohistochemistry (17-19). We found that 4 of 6 PCM cases showed CD117 immunoreactivity.

Hematolymphoid neoplasms showing plasma cell differentiation range from low-grade B-cell lymphomas to PCM. Previous studies have also suggested that plasma cell differentiation may occur in CHL (20). The determination of plasma cell differentiation in B-cell lymphomas is important for classification and prediction of biologic behavior. The markers generally used for detecting plasma cell differentiation are CD38, CD138, and VS38. IRF4/MUM1, as a marker for a fraction of germinal center-B cells and plasma cells, can be expressed on especially postgerminal center B-cell lymphomas and activated T-cells (21). There are studies in the literature examining the prognostic impact of IRF4/MUM1 expression in CHL, CLL/SLL and DLBCL (24-26). IRF4/MUM1 is expressed in most of the CHLs (22,23). In this study, IRF4/MUM1 expression was found in 78% of CHLs and 38% of DLBCLs, consistent with the other reports. In agreement with our findings, a limited number of studies have demonstrated IRF4/MUM1 expression in several T-cell lymphomas, including ALCL and some peripheral T-cell types, in addition to PCMs (27,28). To date, there is no study examining the relation between CD117 expression, plasma cell differentiation and IRF4/MUM1 expression by immunohistochemistry in lymphomas. In the current study, CD117 expression was not correlated with IRF4/MUM1 expression in lymphomas ($P > 0.05$). CD38 and CD117 double expression was seen in only 2 of 3 CD38-positive cases ($P = 0.006$, kappa value = 0.099). Even if this result was statistically significant, it is difficult to interpret this finding as suggestive for a significant relation between these two markers. Although CD38 and IRF4/MUM1 are expressed in a certain type of B cells and related malignancies, the number of CD38-positive cases in this series is not enough to build such a relation.

We confirm that CD117 expression can be seen in a subset of T- or B-cell lymphoid neoplasms and PCMs. The significance of CD117 expression in these cases is unclear.

In our series, since the quantification of CD117 mRNA levels was not done due to the lack of frozen tissue, we could not compare the results of immunohistochemistry and mRNA levels. The contradicting results published regarding CD117 expression on paraffin-embedded tissues in lymphomas might be explained by: (i) using different commercial antibodies for CD117, (ii) using

different tissues, such as bone marrow and lymph node, and (iii) using different methods for comparisons of results, such as flow cytometry, etc.

Most of the CHLs and some of the T- and B-cell lymphomas may show IRF4/MUM1 expression. Our results suggest that CD117 expression is not associated with IRF4/MUM1 expression in lymphoid neoplasms.

References

1. Escribano L, Ocqueteau M, Almeida J, Orfao A, San Miguel JF. Expression of the c-kit (CD117) molecule in normal and malignant hematopoiesis. *Leuk Lymphoma* 1998; 30: 459-66.
2. Zimpfer A, Went P, Tzankov A, Pehrs A-C, Lugli A, Maurer R et al. Rare expression of KIT (CD117) in lymphomas: a tissue microarray study of 1166 cases. *Histopathology* 2004; 45: 398-404.
3. Chen J, Yanuck RR III, Abbondanzo SL, Chu WS, Aguilera NS. C-Kit (CD117) reactivity in extramedullary myeloid tumor/granulocytic sarcoma. *Arch Pathol Lab Med* 2001; 125: 1448-52.
4. Natkunam Y, Rouse RV. Utility of paraffin section immunohistochemistry for C-KIT (CD117) in the differential diagnosis of systemic mast cell disease involving the bone marrow. *Am J Surg Pathol* 2000; 24: 81-91.
5. Sykora KW, Tomeczkowski J, Reiter A. C-kit receptors in childhood malignant lymphoblastic cells. *Leuk Lymphoma* 1997; 25: 201-16.
6. Ocqueteau M, Orfao A, Garcia-Sanz R, Almeida J, Gonzalez M, San Miguel JF. Expression of the CD117 antigen (c-kit) on normal and myelomatous plasma cells. *Br J Haematol* 1996; 95: 489-93.
7. Pinto A, Gloghini A, Gattei V, Aldinucci D, Zagonel V, Carbone A. Expression of the c-kit receptor in human lymphomas is restricted to Hodgkin's disease and CD30+ anaplastic large cell lymphomas. *Blood* 1994; 83: 785-92.
8. Bravo P, Agustin BD, Bellas C, Gonzalez D, Camara C, Fuertes IF et al. Expression of high amounts of the CD117 molecule in a case of B-cell non-Hodgkin's lymphoma carrying the t(14;18) translocation. *Am J Hematol* 2000; 63: 226-9.
9. Potti A, Ganti AK, Kargas S, Koch M. Immunohistochemical detection of C-kit (CD117) and vascular endothelial growth factor (VEGF) overexpression in mantle cell lymphoma. *Anticancer Res* 2002; 22: 2899-901.
10. Vakiani E, Giorgio C, Colovai AI, Murty VV, Alobeid B, Bhagat G. CD117 expression in diffuse large B-cell lymphomas: fact or fiction? *Pathol Int* 2005; 55: 716-23.
11. Jaffe ES, Harris NL, Stein H, Vardiman JW. WHO Classification of Tumours, Pathology and Genetics of Tumours of Haemopoietic and Lymphoid Tissues. Lyon: IARC Press; 2001.
12. Re D, Wickenhauser C, Ahmadi T. Preclinical evaluation of the antiproliferative potential of STI571 in Hodgkin's disease. *Br J Cancer* 2002; 86: 1333-5.
13. Arber DA, Tamayo R, Weiss LM. Paraffin section detection of the c-kit gene product (CD117) in human tissues: value in the diagnosis of mast cell disorders. *Hum Pathol* 1998; 29: 498-504.
14. Tomeczkowski J, Beilken A, Frick D, Wieland B, Köniq A, Falk MH et al. Absence of c-kit receptor and absent proliferative response to stem cell factor in childhood Burkitt's lymphoma cells. *Blood* 1995; 86: 1469-80.
15. Choe YS, Kim JG, Sohn SK, Kim DH, Baek JH, Lee KB et al. c-kit expression and mutations in peripheral T cell lymphomas, except for extra-nodal NK/T cell lymphomas. *Leuk Lymphoma* 2006; 47(2): 267-70.
16. Brauns TC, Schultewolter T, Dissemond J, Maschke J, Goos M. c-kit expression in primary cutaneous T-cell lymphomas. *J Cutan Pathol* 2004; 31: 577-82.
17. Pruneri G, Ponzoni M, Ferreri AJM, Freschi M, Tresoldi M, Baldini L et al. The prevalence and clinical implications of c-kit expression in plasma cell myeloma. *Histopathology* 2006; 48: 529-35.
18. Potti A, Ganti AK, Koch M, Levitt R, Mehdi SA. Immunohistochemical identification of HER-2/neu overexpression and CD117 (c-kit) expression in multiple myeloma. *Leuk Lymphoma* 2002; 43: 2427-30.
19. Lugli A, Went P, Khanlari B, Nikolova Z, Dirnhofer S. Rare KIT (CD117) expression in multiple myeloma abrogates the usefulness of imatinib mesylate treatment. *Virchows Arch* 2004; 444: 264-8.
20. Carbone A, Gloghini A, Gaidano G, Franceschi S, Capello D, Drexler HG et al. Expression status of BCL-6 and syndecan-1 identifies distinct histogenetic subtypes of Hodgkin's disease. *Blood* 1998; 92: 2220-8.
21. Alizadeh AA, Eisen MB, Davis RE, Ma C, Lossos IS, Rosenwald A et al. Distinct types of diffuse large B-cell lymphoma identified by gene expression profiling. *Nature* 2000; 403: 503-11.
22. Bai M, Panoulas V, Papoudou-Bai A, Horianopoulos N, Kitsoulis P, Stefanaki K et al. B-cell differentiation immunophenotypes in classical Hodgkin's lymphomas. *Leuk Lymphoma* 2006; 47: 495-501.

23. Falini B, Fizzotti M, Pucciarini A, Bigerna B, Marafioti T, Gambacorta M et al. A monoclonal antibody (MUM1p) detects expression of the MUM1/IRF4 protein in a subset of germinal center B cells, plasma cells, and activated T cells. *Blood* 2000; 95: 2084-92.
24. Chang CC, Lorek J, Sabath DE, Li Y, Chitambar CR, Logan B et al. Expression of MUM1/IRF4 correlates with clinical outcome in patients with B-cell chronic lymphocytic leukemia. *Blood* 2002; 100: 4671-5.
25. Sundram U, Kim Y, Mraz-Gernhard S, Hoppe R, Natkunam Y, Kohler S. Expression of the bcl-6 and MUM1/IRF4 proteins correlate with overall and disease-specific survival in patients with primary cutaneous large B-cell lymphoma: a tissue microarray study. *J Cutan Pathol* 2005; 32: 227-34.
26. Valsami S, Pappa V, Rontogianni D, Kotsioti F, Papageorgiou E, Dervenoulas J et al. A clinicopathological study of B-cell differentiation markers and transcription factors in classical Hodgkin's lymphoma: a potential prognostic role of MUM1/IRF4. *Haematologica* 2007; 92: 1343-50.
27. Natkunam Y, Warnke RA, Montgomery K, Falini B, van De Rijn M. Analysis of MUM1/IRF4 protein expression using tissue microarrays and immunohistochemistry. *Mod Pathol* 2001; 14: 686-94.
28. Tsuboi K, Lida S, Inagaki H, Kato M, Hayami Y, Hanamura I et al. MUM1/IRF4 expression as a frequent event in mature lymphoid malignancies. *Leukemia* 2000; 14(3): 449-56.