

1-1-2009

Histopathological and Clinical Characteristics of Secretory Carcinoma of the Breast

KERİM BORA YILMAZ

IŞIN PAK

CAN ATALAY

CİHANGİR ÖZASLAN

Follow this and additional works at: <https://journals.tubitak.gov.tr/medical>



Part of the [Medical Sciences Commons](#)

Recommended Citation

YILMAZ, KERİM BORA; PAK, IŞIN; ATALAY, CAN; and ÖZASLAN, CİHANGİR (2009) "Histopathological and Clinical Characteristics of Secretory Carcinoma of the Breast," *Turkish Journal of Medical Sciences*: Vol. 39: No. 1, Article 27. <https://doi.org/10.3906/sag-0804-40>
Available at: <https://journals.tubitak.gov.tr/medical/vol39/iss1/27>

This Article is brought to you for free and open access by TÜBİTAK Academic Journals. It has been accepted for inclusion in Turkish Journal of Medical Sciences by an authorized editor of TÜBİTAK Academic Journals. For more information, please contact academic.publications@tubitak.gov.tr.

Histopathological and Clinical Characteristics of Secretory Carcinoma of the Breast

Kerim Bora YILMAZ¹
Işın PAK²
Can ATALAY¹
Cihangir ÖZASLAN¹

Abstract: Secretory breast carcinoma is a rare form of invasive breast carcinoma constituting less than 1% of all breast cancer cases. Since insufficient data have been compiled about this rare tumor, it is important to report every case of secretory breast carcinoma in an effort to better understand the histopathological and clinical characteristics of this tumor and to contemplate the most appropriate therapeutic approach. In this report, two adult female patients over 50 years of age and a 14-year-old girl were reviewed with a detailed immunohistochemical work-up to define the clinical and molecular characteristics of secretory breast carcinoma.

Key Words: Secretory breast cancer, triple negative, immunohistochemistry

Sekretuar Meme Kanserinin Histopatolojik ve Klinik Özellikleri

Özet: Sekretuar meme kanseri invaziv meme kanserinin nadir görülen bir tipidir ve tüm meme kanseri olgularının % 1'inden azını oluşturur. Bu nadir tümör hakkında yetersiz bir bilgi birikimi olduğundan, en uygun tedavi yaklaşımını planlayabilmek ve bu tümörün histopatolojik ve klinik özelliklerini daha iyi anlayabilmek için her sekretuar meme kanseri olgusunun bildirilmesi önemlidir. Bu çalışmada, sekretuar meme kanserinin klinik ve moleküler özelliklerini tanımlayabilmek için detaylı bir immünohistokimyasal inceleme ile 50 yaşın üzerinde iki erişkin kadın hasta ve 14 yaşında bir kız hasta gözden geçirilmiştir.

Anahtar Sözcükler: Sekretuar meme kanseri; triple negatif; immünohistokimya

¹ Department of General Surgery,
Ankara Oncology Hospital,
Ankara - TURKEY

² Department of Pathology,
Ankara Oncology Hospital,
Ankara - TURKEY

Received: April 30, 2008
Accepted: September 03, 2008

Correspondence

Can ATALAY
Bişkek Cad. Yeşiltepe Blokları
4. Blok No: 11
06510 Ankara - TURKEY
atalay_can@hotmail.com

Introduction

Secretory breast carcinoma (SBC) is an exceedingly rare form of invasive breast carcinoma and constitutes less than 1% of all breast cancer cases (1). The first detailed description of SBC was published in 1966 by McDivitt and Stewart. Seven cases in children were reported and the young ages of the patients led to the designation of this type of breast cancer as "juvenile carcinoma" (2). However, in the following years, SBC was reported to occur in children and adults of all ages and both sexes (3-6). SBC in children and young adults less than 20 years of age is associated with a very favorable prognosis, but in elderly women the clinical course resembles that of more common histological types of breast cancer with late recurrences and distant metastases (7). Previously, less than 10 patients older than 50 years of age were reported (3).

Since insufficient data have been compiled about the biological behavior and clinical course of this tumor, it would be logical to report every case of SBC in an effort to better understand its histopathological and clinical characteristics and contemplate the most appropriate therapeutic approach (8,9). In this report, two adult female patients over 50 years of age and a 14-year-old girl were reviewed with a detailed immunohistochemical work-up to define the clinical and molecular characteristics of SBC.

Case Reports

Case 1

A 14-year-old female patient presented with a 8x8 cm mass that had been present for four years. Physical examination revealed palpable lymph nodes in the left axilla. Incisional biopsy confirmed the diagnosis. There were no distant metastases in chest radiography, abdominal ultrasonography (USG), and bone scintigraphy. Modified radical mastectomy (MRM) was performed and none of the 30 lymph nodes dissected from the axilla was metastatic. The patient received cyclophosphamide 500 mg/m², methotrexate 50 mg/m², and 5-fluorouracil 500 mg/m² on days 1 and 8, repeated every 28 days for six cycles, due to the large tumor size. The patient is disease-free and alive 36 months after surgery.

Case 2

A 56-year-old postmenopausal patient presented with a 4x4 cm mass that was present for eight months in her left breast and palpable lymph nodes in the left axilla. Mammography revealed a high-density spiculated lesion 25 mm in diameter. Breast USG revealed a hypoechoic and irregular solid lesion measuring 25x23x14 mm. Histopathological tumor size was 5x5x3.5 cm after excisional biopsy. Abdominal USG, chest radiography, and bone scintigraphy did not reveal any distant metastases. The patient underwent left MRM. Axillary lymph node metastasis was present in one of the 26 dissected lymph nodes. It was 3.5 cm in size and showed extracapsular tumor extension. Adjuvant chemotherapy was administered as cyclophosphamide 600 mg/m², doxorubicin 60 mg/m², and 5-fluorouracil 600 mg/m², repeated every 21 days for six cycles. Radiotherapy was applied to the chest wall and the axillary region due to the large tumor size and extracapsular tumor extension in the metastatic lymph node. The patient had no evidence of local recurrence or distant metastases 30 months after surgery.

Case 3

A 54-year-old postmenopausal patient presented with a 10x10 cm mass with edematous skin in the left breast and a 5x5 cm mass in the axilla, both of which had been present for 18 months. She had a history of invasive ductal carcinoma of the right breast treated with MRM 12 years before. Previously, there were no axillary metastases and she was given six cycles of

cyclophosphamide 500 mg/m², methotrexate 50 mg/m², and 5-fluorouracil 500 mg/m² on days 1 and 8, repeated every 28 days for six cycles. Tamoxifen 10 mg bid, which she used for six months, was recommended.

Screening results for distant spread with bone scintigraphy, abdominal USG, and thorax computerized tomography were normal. The patient received three cycles of neoadjuvant cyclophosphamide 600 mg/m², doxorubicin 60 mg/m², and 5-fluorouracil 600 mg/m² chemotherapy, repeated every 21 days, and MRM was performed. Residual tumor size was 3x3x2.5 cm and 13 out of 16 lymph nodes were metastatic in the axilla. One more cycle of the previous chemotherapy was given followed by four cycles of docetaxel 100 mg/m², repeated every three weeks. Radiotherapy was administered to the chest wall and the axillary region. Hormonotherapy was given as tamoxifen 10 mg bid.

Multiple metastases were identified in bone scintigraphy two years after the diagnosis. Zoledronic acid 4 mg once a month and anastrozole 1 mg/day were given. A year later, hepatic metastases were detected on abdominal USG. Cisplatin 25 mg/m² and etoposide 100 mg/m² were applied on three consecutive days, repeated every three weeks for six cycles. The patient had stable disease 9 months after the completion of treatment and is alive 45 months after the diagnosis.

Histopathological Findings

Macroscopically, all of the tumors were well-circumscribed and had a heterogeneous appearance on their cut surface with a grayish-white to tan color. The largest tumor diameter was 7 cm (Case 1), whereas residual tumor sizes were 3 cm (Case 2) and 2 cm (Case 3) in diameter in the other two cases.

Microscopically, there were small, uniform glands filled with secretory material, which was also present extracellularly (Figure 1a, 1b). Epithelial cell nuclei were relatively monotonous and round in shape with inconspicuous nucleoli, and no sign of mitoses was observed. Epithelial tumor cells lacked significant atypia and appeared bulging due to secretory material and vacuolated with secretory droplets. Secretory material was periodic acid-Schiff (PAS)-positive and diastase-resistant in histochemical examination. In addition, Alcian blue and mucicarmine stained positive both inside and outside the tumor cells.

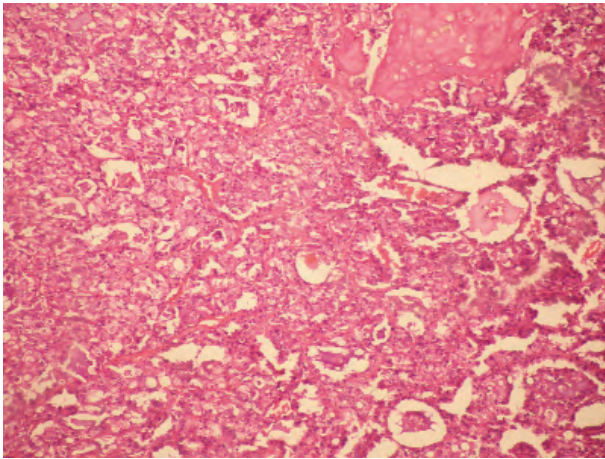


Figure 1a. Secretory carcinoma of the breast (H&E X100).

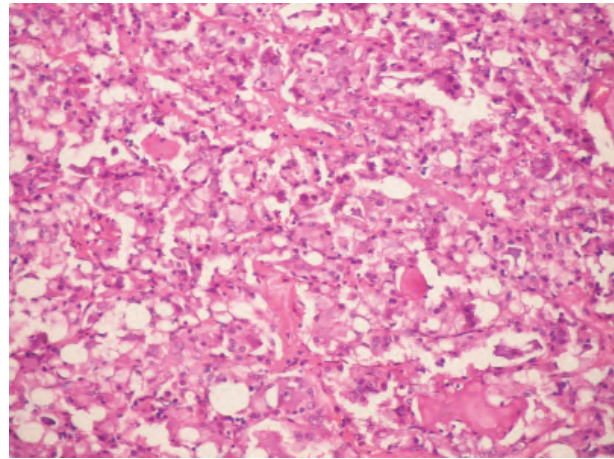


Figure 1b. Secretory carcinoma of the breast (H&E X200).

Immunohistochemistry was performed by streptavidin-biotin method using antibodies for monoclonal and polyclonal carcinoembryonic antigens (CEA) (Neomarkers, 1/400, 1/600 dilution), actin (Neomarkers, 1/200), S100 (Neomarkers, 1/2000 dilution), mammaglobulin (DAKO, 1/100 dilution), estrogen (ER) and progesterone (PR) receptors, HER2 (Neomarkers, 1/250, 1/500, 1/800 dilutions), and cytokeratin 5/6 (DAKO, 1/10 dilution).

All three cases stained negative for actin and positive for S100 and mammaglobulin. In addition, two cases were negative for monoclonal and polyclonal CEA, whereas the other case was strongly positive for both. Two cases stained negative for ER, PR, and HER2 (triple negative) (Cases 1 and 2) and the third case was ER-positive and both PR- and HER2- negative (Case 3). One of the triple-negative cases (Case 2) stained positive for cytokeratin 5/6, suggesting a basal-like breast carcinoma.

Discussion

Due to the rare occurrence of SBC, its clinical course is not fully appreciated by clinicians, resulting in discrepancies in treatment planning. SBC is not commonly diagnosed in older patients, unlike other histological types of breast cancer. It was first described as a disease of children, but later detected in all ages ranging from 3 to 87, with a median age of 25 and more than 60% of cases being older than 20 years (5,10,11). SBC usually occurs in females, but was also reported in young males (M/F=1/6). All cases were female in this study and two cases were over 50

years of age, whereas the third case was 14 years old, reflecting the heterogeneity in patient age.

Tavassoli and Norris suggested three features of SBC that indicate a favorable prognosis: (1) tumor size less than 2 cm, (2) age less than 20 years at the time of diagnosis, and (3) tumor with circumscribed margins (10). However, all three patients presented with large tumors and two patients were older than 50 years, indicating a worse outcome. Adult female patients usually present at a median age of 33. There are less than 10 patients over 50 years of age and their tumors are thought to behave like more common histological types of breast cancer (3).

Duration of symptoms in patients was reported to vary from one month to 20 years (5,7). There is usually a longer time span between the occurrence of symptoms and treatment irrespective of age and gender. Tumors generally present as hard, mobile lumps with well-defined margins, as in our cases. Depending on the duration of symptoms, tumor size may vary from <1 to 16 cm (7,10). All cases in this study had large tumors and long duration of symptoms.

Axillary and distant metastases occur less frequently compared to other types of breast cancer, and prognosis is better (3,5,6,12). Breast conserving surgery (BCS) can be an option in SBC especially in prepubertal girls in whom breast development is not yet complete. In children and males, tumor size and location may hinder this possibility. Some authors suggest mastectomy as the standard treatment due to local recurrences in two-thirds

of the patients treated with BCS (5,10). Richard et al. (13) reported the local recurrence rate as 33% in 33 adult female patients treated with BCS. Mastectomy was preferred in this study due to the large tumor size.

Axillary metastases are detected in 20-30% of SBC patients and are rare in females with tumors <2 cm (5,10). However, higher rates of axillary metastases are detected in male patients with smaller tumors (3,5,10). Complete axillary dissection has significant complications such as pain, loss of skin sensation, seroma formation, limitation of shoulder movements, increase in the frequency of lymphangitis, and lymphedema (12,14). Sentinel lymph node biopsy is an acceptable alternative to axillary dissection especially in children with a longer life expectancy, protecting the patients from unnecessary morbidity (6,15). However, axillary dissection was performed in all of our patients due to the presence of palpable lymph nodes.

Distant metastases were previously reported in only four patients (8,16). Case 3 presented with locally advanced disease and distant metastases occurred in the first two years of diagnosis. It is not possible to determine whether these distant metastases resulted from invasive ductal carcinoma or SBC. All previous metastatic patients showed disease progression while on treatment with chemotherapy (8,10,16). However, chemotherapy resulted in stable disease for the first time in our case with distant metastases.

SBC is a low-grade carcinoma with solid, microcystic, and ductal architecture composed of cells that produce large amounts of intracellular and extracellular secretions and have vacuolated or granular eosinophilic cytoplasm (10). Neoplastic cells are polygonal with minimal or absent atypia and mitotic activity with accompanying prominent nucleoli. In addition, presence of intracytoplasmic vacuoles is a key feature for accurate diagnosis (3). Secretions stain with Alcian blue and PAS with and without diastase (5,7). Immunohistochemistry generally gives positive results with cytokeratins, S100, CEA, and alpha-lactalbumin (5,7). All of our cases showed similar features. Epithelial cells had PAS- positive, diastase-resistant secretory material and were immunoreactive for mammaglobulin.

The relationship between SBC and hormone receptor status is controversial. ER and PR status varies in all age groups of male and female patients and pathogenesis of SBC may be unrelated to female sex hormones (5,7).

Based on well-differentiated nuclear features and a diploid tumor with a low S-phase fraction in flow cytometric studies, ER and PR positivity is anticipated (13,17). Contrary to this expectation, most of these tumors are hormone receptor- negative. In addition, recent studies reported triple-negative cases after the widespread assessment of HER2 status (8,15,18,19). All of our cases were PR- and HER2-negative and only one patient showed ER positivity. As a result, two patients had triple-negative tumors. However, only one of these cases stained positive with cytokeratin 5/6 and was accepted as basal-like carcinoma. There is scarce information regarding the use of hormonotherapy in young patients; however, it can be utilized in hormone receptor-positive patients.

There are many controversies regarding the adjuvant treatment of SBC. While some clinicians do not recommend adjuvant radiotherapy, some argue that this treatment must be planned according to the risk factors (6). In patients with small tumors and negative axilla, radiotherapy is not necessary after mastectomy. Adjuvant radiotherapy must follow BCS in the adult patient group in order to decrease the local recurrence rate. However, radiotherapy must be avoided in children, where it may result in impairment of coastal growth and lung complications (15). Despite the previous reports claiming that chemotherapy has no effect on disease course, various combination protocols are still widely used (4,8). Due to the large tumor size and metastases in the axilla, patients in this study received adjuvant chemotherapy. Although there is at present no sufficient evidence to recommend adjuvant chemotherapy and radiotherapy, contemporary guidelines for breast cancer management should be followed in cases with large tumor size and axillary metastases, especially in adults.

Since SBC follows an indolent clinical course, a long-term follow-up is required to reach definite conclusions about its clinical behavior. Treatment must be planned by taking into consideration the histopathological characteristics, tumor size, and axillary lymph node status and should differ between children and adult patients. Conservative surgery may be preferred in children and young adults. Radiotherapy should only be used in adult patients with risk factors such as large tumor size and axillary lymph node metastases. Chemotherapy can be used in both adults and children. Hormonotherapy should be used in hormone receptor- positive adult patients.

References

1. Kavalakat AJ, Covilakam RK, Culas TB. Secretary carcinoma of breast in a 17-year-old male. *World J Surg Oncol* 2004; 2: 17.
2. McDivitt RW, Stewart FW. Breast carcinoma in children. *JAMA* 1966; 195: 388-90.
3. Yaqoob N, Kayani N, ul Hasan SH. Painless breast lump in an elderly woman. *Arch Pathol Lab Med* 2006; 130: 1073-4.
4. Yildirim E, Turhan N, Pak I, Berberoğlu U. Secretary breast carcinoma in a boy. *Eur J Surg Oncol* 1999; 25: 98-9.
5. de Bree E, Askoxylakis J, Giannikaki E, Chroniaris N, Sanidas E, Tsiftsis DD. Secretary carcinoma of the male breast. *Ann Surg Oncol* 2002; 9: 663-7.
6. Szanto J, Andras C, Tsakiris J, Gomba S, Szentirmay Z, Banlaki S et al. Secretary breast cancer in a 7.5-year old boy. *Breast* 2004; 13: 439-42.
7. Rosen PP, Cranor ML. Secretary carcinoma of the breast. *Arch Pathol Lab Med* 1991; 115: 141-4.
8. Herz H, Cooke B, Goldstein D. Metastatic secretary breast cancer. Non-responsiveness to chemotherapy: case report and review of the literature. *Ann Oncol* 2000; 11: 1343-7.
9. Costa NM, Rodrigues H, Pereira H, Pardal F, Matos E. Secretary breast carcinoma - case report and review of the medical literature. *Breast* 2004; 13: 353-5.
10. Tavassoli FA, Norris HJ. Secretary carcinoma of the breast. *Cancer* 1980; 45: 2404-13.
11. Karl SR, Ballantine TV, Zaino R. Juvenile secretary carcinoma of the breast. *J Pediatr Surg* 1985; 20: 368-71.
12. Bond SJ, Buchino JJ, Nagaraj HS, McMasters KM. Sentinel lymph node biopsy in juvenile secretary carcinoma. *J Pediatr Surg* 2004; 39: 120-1.
13. Richard G, Hawk JC III, Baker AS Jr, Austin RM. Multicentric adult secretary breast carcinoma: DNA flow cytometric findings, prognostic features, and review of the world literature. *J Surg Oncol* 1990; 44: 238-44.
14. Ozaslan C, Kuru B. Lymphedema after treatment of breast cancer. *Am J Surg* 2004; 187: 69-72.
15. Vieni S, Cabibi D, Cipolla C, Fricano S, Graceffa G, Latteri MA. Secretary breast carcinoma with metastatic sentinel lymph node. *World J Surg Oncol* 2006; 4: 88.
16. Krausz T, Jenkins D, Grontoft O, Pollock DJ, Azzopardi JG. Secretary carcinoma of the breast in adults: emphasis on late recurrence and metastasis. *Histopathology* 1989; 14: 25-36.
17. Lamovec J, Bracko M. Secretary carcinoma of the breast: light microscopical, immunohistochemical flow cytometric study. *Mod Pathol* 1994; 7: 475-9.
18. Arce C, Cortes-Padilla D, Huntsman DG, Miller MA, Duennas-Gonzales A, Alvarado A et al. Secretary breast carcinoma of the breast containing the ETV6-NTRK3 fusion gene in a male: case report and review of the literature. *World J Surg Oncol* 2005; 3: 35.
19. Grabellus F, Worm K, Willruth A, Schmitz KJ, Otterbach F, Baba HA et al. *ETV6-NTRK3* gene fusion in a secretary carcinoma of the breast of a male-to-female transsexual. *Breast* 2005; 14: 71-4.