

1-1-2009

Giant Lobular Capillary Hemangioma of the Nasal Septum

SELAHATTİN GENÇ

Ş. SİNAN KÜRKÇÜOĞLU

HAYRİYE KARABULUT

BARAN ACAR

ÜMİT TUNÇEL

See next page for additional authors

Follow this and additional works at: <https://journals.tubitak.gov.tr/medical>

 Part of the [Medical Sciences Commons](#)

Recommended Citation

GENÇ, SELAHATTİN; KÜRKÇÜOĞLU, Ş. SİNAN; KARABULUT, HAYRİYE; ACAR, BARAN; TUNÇEL, ÜMİT; and DEĞERLİ, SEMİH (2009) "Giant Lobular Capillary Hemangioma of the Nasal Septum," *Turkish Journal of Medical Sciences*: Vol. 39: No. 2, Article 28. <https://doi.org/10.3906/sag-0803-31>
Available at: <https://journals.tubitak.gov.tr/medical/vol39/iss2/28>

This Article is brought to you for free and open access by TÜBİTAK Academic Journals. It has been accepted for inclusion in Turkish Journal of Medical Sciences by an authorized editor of TÜBİTAK Academic Journals. For more information, please contact academic.publications@tubitak.gov.tr.

Giant Lobular Capillary Hemangioma of the Nasal Septum

Authors

SELAHATTİN GENÇ, Ş. SİNAN KÜRKÇÜOĞLU, HAYRİYE KARABULUT, BARAN ACAR, ÜMİT TUNÇEL, and SEMİH DEĞERLİ

Giant Lobular Capillary Hemangioma of the Nasal Septum

Selahattin GENÇ¹
Ş. Sinan KÜRKCÜOĞLU¹
Hayriye KARABULUT¹
Baran ACAR¹
Ümit TUNÇEL¹
Semih DEĞERLİ²

Abstract: Lobular capillary hemangioma is a benign, rapidly growing lesion of the skin and mucous membranes. It may rarely present as a mass of considerable size and thus entirely fill the nasal cavity; such lesions have been termed giant lobular capillary hemangioma. Its etiology remains obscure. Although it has no predilection for age, it is more common in the third decade and in females. Lobular capillary hemangioma usually involves the gingiva, lips, tongue, and buccal mucosa. However, the nasal cavity is a rare location for this lesion. The most common symptoms are epistaxis and nasal obstruction. The treatment of choice is endoscopic surgery even for large lesions because it does not require preoperative embolization. In this report, we present a 31-year-old male patient with giant lobular capillary hemangioma presented with epistaxis and nasal obstruction. We emphasize that the rarely seen giant lobular capillary hemangioma must be kept in mind in the differential diagnosis of a rapidly growing mass of the nasal cavity, and we discuss the treatment approach.

Key Words: Giant lobular capillary hemangioma, nasal septum, nasal obstruction, epistaxis, endoscopic surgery

¹ Department of Otorhinolaryngology,
Keçioren Education and Research
Hospital, Ankara - TURKEY

² Department of Anesthesiology,
Keçioren Education and Research
Hospital, Ankara - TURKEY

Nazal Septumun Dev Lobüler Kapiller Hemanjiomu

Özet: Lobüler kapiller hemanjiom deri ve müköz membranların etiyolojisi tam olarak bilinmeyen iyi huylu, hızlı büyüyen bir lezyonudur. Lobüler kapiller hemanjiom nadiren büyük boyutlara ulaşabilir, böylece nasal kaviteyi tamamen doldurur ve bu tip lezyonlar dev kapiller hemanjiyom olarak tanımlanır. Hastalığa tüm yaşlarda rastlanabilir ancak sıklıkla 3. dekada ve bayanlarda görülür. Gingiva, dudaklar, dil ve bukkal mukoza en sık görüldüğü yerlerdir. Nazal kavitede nadiren görülür. Epistaksis ve burun tıkanıklığı en sık karşılaşılan semptomlardır. Çok büyük lezyonlarda bile preoperatif embolizasyona gerek kalmadan yapılan endoskopik rezeksiyon tercih edilen tedavi yaklaşımıdır. Biz yazımızda epistaksis ve burun tıkanıklığı şikayeti ile başvuran 31 yaşında bir erkek hastada tespit ettiğimiz dev lobüler kapiller hemanjiom olgusunu sunduk. Tedavi yaklaşımını tartışarak nadiren görülen dev lobüler kapiller hemanjiomların hızlı büyüyen nasal kavite kitlelerinin ayırıcı tanısında akılda bulundurulması gerektiğini vurguladık.

Anahtar Sözcükler: Dev lobüler kapiller hemanjiom, nazal septum, burun tıkanıklığı, epistaksis, endoskopik cerrahi

Introduction

Lobular capillary hemangioma (LCH), a benign, rapidly growing, usually solitary lesion, occurs in the skin and mucous membranes. Its etiology remains unknown. It was first described as *human botryomycosis* by Poncet and Dor in 1897 (1,2). Also known as pyogenic granuloma, LCH is a benign capillary proliferation with a microscopically distinctive lobular structure that affects the skin and mucous membranes of the oral cavity and nasal region. The oral cavity has been reported to be a common site of involvement, while it is rarely located in the nasal cavity (2). It may be pedunculated or broad-based and can vary in size from a few millimeters to several centimeters (2). The most common etiologic factors have been thought to be trauma and hormonal factors (2).

We emphasize that in the differential diagnosis of a rapidly growing mass filling the nasal cavity, the rarely seen giant LCH must be kept in mind. Our case also illustrates that even large lesions do not require preoperative embolization and can be resected with endoscopic surgery.

Received: March 03, 2008
Accepted: October 30, 2008

Correspondence
Selahattin GENÇ
Department of
Otorhinolaryngology,
Keçioren Education and Research
Hospital,
06310 Ankara - TURKEY
drsgenc@yahoo.com

Case Report

A 31-year-old male patient presented with complaints of epistaxis and nasal obstruction for the past two months. There was no known history of trauma, nasal packing, and/or irritation. During this period, he did not undergo any kind of treatment. Physical examination and nasal endoscopy revealed a large, dark reddish hemorrhagic polypoid mass in the right nasal cavity, which bled easily upon manipulation. It originated from the posterosuperior portion of the septal mucosa, extended to the nasal vestibule and completely obstructed the nasal orifice (Figure 1). The patient was otherwise healthy. Nasal and paranasal sinus magnetic resonance imaging (MRI) revealed a soft tissue mass arising from the posterosuperior portion of the nasal septum, without connection to the intracranial contents (Figure 2). There was no extension to the paranasal sinuses or contiguous tissues, and there was no bone damage. Incisional biopsy specimen of the mass was obtained. The results of histopathological examination revealed LCH. The nasal mass was excised completely with the patient under general anesthesia using an endoscopic surgery technique with no requirement of preoperative embolization or perioperative blood transfusion. This involved partial resection of the mucous septum and the perichondrium. On gross pathologic examination, a smooth-surfaced, grayish-pink polypoid mass was measured to be

approximately 35 × 35 × 30 mm in size. In histopathological examination, a polypoid mass of angiomatous tissue protruding above the surrounding mucosa was seen. Pseudostratified ciliated epithelium covered the entire lesion, and some parts were eroded. Lobules of dilated and congested capillaries were noted. There was profound inflammatory cell infiltration (Figure 3). The patient had an uneventful postoperative course, and there was no recurrence in the following year.

Discussion

Lobular capillary hemangioma is a benign lesion occurring in the skin and mucous membranes. It is a common and an acquired vascular tumor. It was once termed as pyogenic granuloma, which is thought to be a misnomer because the lesion is neither infectious nor granulomatous (3). The description of the lesion by Miller (3) as LCH was based on the histopathological findings.

Although LCH may appear in all ages, it is more common in the third decade and in females. The most common sites of mucosal LCH are the gingiva, lips, tongue, and buccal mucosa, but nasal cavity involvement is unusual, with the anterior portion of the septal mucosa and the tip of the turbinate as the most frequently involved areas in the nasal cavity (1,3). In our case, LCH was on the posterosuperior portion of the septal mucosa.

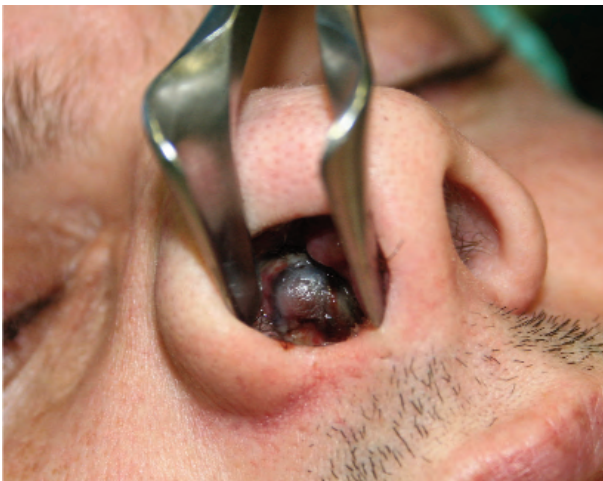

Figure 1. Giant lobular capillary hemangioma of the right nasal cavity.

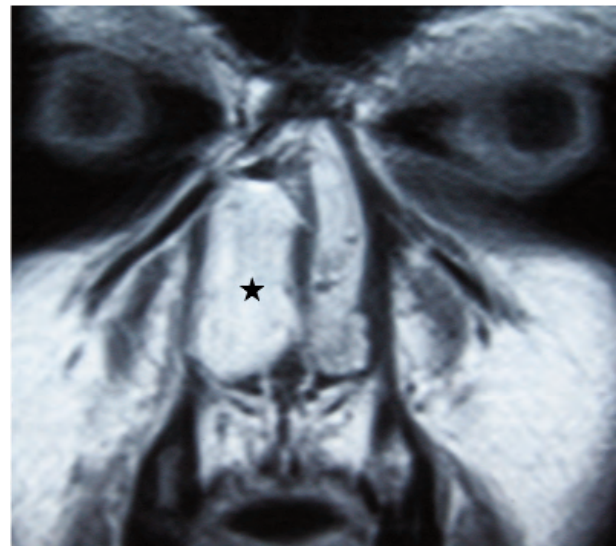


Figure 2. MRI, axial SE T2. Hyperintense lesion arising from the nasal septum is seen in the right nasal cavity.

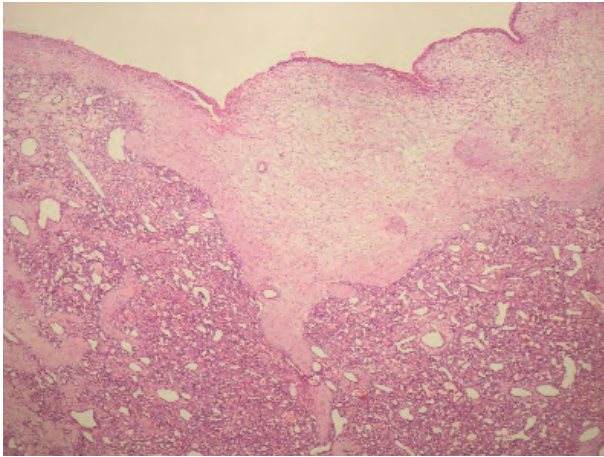


Figure 3. Histological section showing the typical lobular pattern of LCH. The capillary veins ordered in clusters within the loose stroma are observed. HE 40x.

No mechanism for the development of LCH has so far been defined. However, trauma, hormonal influences, viral oncogenes, underlying microscopic arteriovenous malformations, and the production of angiogenic growth factors have been suspected to act in the pathogenesis (4). In our patient, none of these potential etiological factors was determined.

Lobular capillary hemangioma of the nasal cavity usually presents with recurrent unilateral epistaxis, nasal obstruction, nasal discharge, and epiphora and rarely with facial pain, alteration of smell, and headache (4).

When LCH presents in its usual form as a hypervascularized small mass located in the anterior portion of the nasal cavity, the diagnosis is not difficult. On endoscopy, the lesion is usually seen as a red to purple single hypervascularized mass, less than 10 mm in diameter, with a predilection for the anterior portion of the nasal septum. On the other hand, LCH may rarely

present as a mass of considerable size and thus entirely fill the nasal cavity; such lesions have been termed as *giant LCH* (4,5). In determining any intracranial extension or connection for big lesions or lesions originating from the roof of the nasal cavity, MRI will complement nasal endoscopic examination (6).

The differential diagnosis of intranasal LCH includes nasal polyp, antrochoanal polyp, meningocele, meningoencephalocele, sarcoidosis, Wegener's granulomatosis, simple granulation tissue, papilloma, Kaposi's sarcoma, hemangiosarcoma, squamous cell carcinoma, mucosal malignant melanoma, and lymphoma (6).

Histologically, LCH has characteristics consistent with polypoid, circumscribed, exophytic and lobular proliferation of capillaries in a fibromyxoid stroma. While large vessels and surrounding aggregates of small-size capillaries form the lobules, overlying epithelium is ulcerated or atrophic (7).

Total excision of the lesion by either classical or endoscopic surgery techniques has been recommended (2,3,8). The endoscopic surgery provides better visualization of the mass and surrounding anatomy, thus allowing the surgeon to remove the mass completely without an external incision. In the very recent literature, all patients with a large lesion have been managed without preoperative embolization and none has experienced blood loss requiring transfusion (4). Recurrences are uncommon, and no malignant transformations have been reported (2,3,8).

In conclusion, giant LCH is a rare lesion of unknown etiology. It should be considered in the differential diagnosis of rapidly enlarging vascular lesions within the nasal cavity. Endoscopically guided total excision is the appropriate treatment even for extremely large lesions with no requirement of preoperative embolization or perioperative blood transfusion.

References

1. Akyol MU, Yalciner EG, Doğan AI. Pyogenic granuloma (lobular capillary hemangioma) of the tongue. *Int J Pediatr Otorhinolaryngol* 2001; 58: 239-41.
2. Ozcan C, Apa DD, Görür K. Pediatric lobular capillary hemangioma of the nasal cavity. *Eur Arch Otorhinolaryngol* 2004; 261: 449-51.
3. Miller FR, D'Agostino MA, Schlack K. Lobular capillary hemangioma of the nasal cavity. *Otolaryngol Head Neck Surg* 1999; 120: 783-4.
4. Puxeddu R, Berlucchi M, Ledda GP, Parodo G, Farina D, Nicolai P. Lobular capillary hemangioma of the nasal cavity: a retrospective study on 40 patients. *Am J Rhinol* 2006; 20: 480-4.

5. Bhattacharyya N, Wenokur RK, Goodman ML. Endoscopic excision of a giant pyogenic granuloma of the nasal cavity caused by nasal packing. *Rhinology* 1997; 35: 44–5.
6. Simo R, de Carpentier J, Rejali D, Gunawardena WJ. Pediatric pyogenic granuloma presenting as a unilateral nasal polyp. *Rhinology* 1998; 36: 136–8.
7. Kapella M, Panosetti E, Rombaux P, Delos M, Weynand B. Lobular capillary hemangioma of the nasal cavity: observation of three specific cases. *Acta Otorhinolaryngol Belg* 2001; 55: 241–6.
8. Lee HM, Lee SH, Hwang SJ. A giant pyogenic granuloma in the nasal cavity caused by nasal packing. *Eur Arch Otorhinolaryngol* 2002; 259: 231–3.