

1-1-2009

Vocal Cord Hemangioma; A Rare Localization in Adults

AYŞE İRİZ

EVİRİM DURMAZ

HALİT AKMANSU

MUHARREM DAĞLI

LEVENT ALBAYRAK

See next page for additional authors

Follow this and additional works at: <https://journals.tubitak.gov.tr/medical>

 Part of the [Medical Sciences Commons](#)

Recommended Citation

İRİZ, AYŞE; DURMAZ, EVİRİM; AKMANSU, HALİT; DAĞLI, MUHARREM; ALBAYRAK, LEVENT; and ERYILMAZ, ADİL (2009) "Vocal Cord Hemangioma; A Rare Localization in Adults," *Turkish Journal of Medical Sciences*: Vol. 39: No. 2, Article 23. <https://doi.org/10.3906/sag-0802-52>

Available at: <https://journals.tubitak.gov.tr/medical/vol39/iss2/23>

This Article is brought to you for free and open access by TÜBİTAK Academic Journals. It has been accepted for inclusion in Turkish Journal of Medical Sciences by an authorized editor of TÜBİTAK Academic Journals. For more information, please contact academic.publications@tubitak.gov.tr.

Vocal Cord Hemangioma; A Rare Localization in Adults

Authors

AYŞE İRİZ, EVRİM DURMAZ, HALİT AKMANSU, MUHARREM DAĞLI, LEVENT ALBAYRAK, and ADİL ERYILMAZ

Vocal Cord Hemangioma; A Rare Localization in Adults

Ayşe İRİZ¹
Evrım DURMAZ¹
Şefik Halit AKMAN SU¹
Muharrem DAĞLI¹
Levent ALBAYRAK²
Adil ERYILMAZ¹

Abstract: We reported of the extremely rare adult case with hemangiomas of the vocal cord. Laryngeal hemangiomas is the most common disease in infantile patients, and respiratory distress is a main symptom in this entity. But adult hemangiomas in vocal cord are very rare conditions, and hoarseness is a main symptom. A 40 years old man with hoarseness and slight difficulty in breathing was presented. Diagnostic investigation revealed a pink-purple mass which was mobile with respiration and extended from the anterior commissure to the posterior part of vocal cord. Direct laryngoscopy was performed, and it was totally excised. There was no recurrence in one year follow-up period.

Key Words: Hemangioma, Vocal cord, Adult

Vokal Kord Hemanjiyoma; Erişkinlerde Nadir Örülen Bir Lokalizasyon

Özet: Bu çalışmada erişkinlerde son derece nadir görülen bir vokal kord hemanjiyoma vakası sunulmuştur. Larengeal hemanjiyoma infantil çağ hastalarda çok sık görülür ve ana semptomu solunum sıkıntısıdır. Fakat erişkin çağda, özellikle vokal kordta çok nadirdir ve ses kısıklığı ana semptomdur. 40 yaşında erkek hasta bize ses kısıklığı ve hafif düzeyde solunum güçlüğü ile başvurdu. İncelemeler sonunda hastanın larenste, vokal kord lokalizasyonunda ön komissürden arka kömüre kadar uzanan ve solunumla hareketli, pembe-mor bir kitle tespit edildi. Kitle direkt larenoskopisi eşliğinde tamamen eksize edildi. Takip eden bir yıl içinde rekürrens izlenmedi.

Anahtar Sözcükler: Hemanjiyoma, Vokal kord, Erişkin

¹ Department of Department of Otorhinolaryngology, Numune Education and Research Hospital, Ankara - TURKEY

² Department of Pathology, Numune Education and Research Hospital, Ankara - TURKEY

Introduction

Hemangioma is one of the most common benign tumors in the head and neck region. Sixty-five percent of hemangiomas arise from the head and neck region (1). In this region, hemangiomas are usually seen in parotid gland, tongue and larynx in children. Hemangiomas of the larynx are classified into adult and infantile forms (1). Infantile hemangiomas occur usually in subglottic region and more frequent in girls. Fluctuating respiratory distress and stridor are the main symptoms. In 90% of cases, the lesions occur by first year of life (2). Adult hemangiomas are rare, and are more often of cavernous form (3). They are more frequent in males. The principal symptom is hoarseness and rarely difficulty in breathing (4). They can be seen in different locations, but they are most often in the supraglottic and glottic regions (4). In this report we presented a case with right vocal cord hemangioma.

Received: February 27, 2008
Accepted: October 30, 2008

Case Presentation

A 40-year-old man came to Otolaryngology Department of Ankara Numune Education and Research Hospital with a complaint of hoarseness and slight difficulty in breathing. There was nothing significant in medical history. The patient had no history of smoking or alcohol consumption. Otolaryngologic physical examination findings were normal otherwise laryngeal lesion. On video-laryngoscopic examination, a pink-purple mass which was mobile with respiration and extended from the anterior commissure to the vocal process of the arytenoids was seen. The lesion was originate from half of the

Correspondence

Ayşe İRİZ
Department of
Otorhinolaryngology,
Numune Education and
Research Hospital,
Ankara - TURKEY

aysecagri@mynet.com

upper surface of the right vocal cord. Direct laryngoscopy was performed and it was excised using microlaryngoscopic technique under general anesthesia (Figure 1). No difficulty was encountered during dissection of the lesion and bleeding was minimal, and was controlled by cauterization. The patient was stable in the post-operative period. The patient was discharged from hospital on the first postoperative day without any discomfort.. Histopathologic examination of the specimen indicated a cavernous hemangioma (Figure 2). There was considerable improvement in the voice of the patient postoperatively, and the vocal cords and their movements were normal.

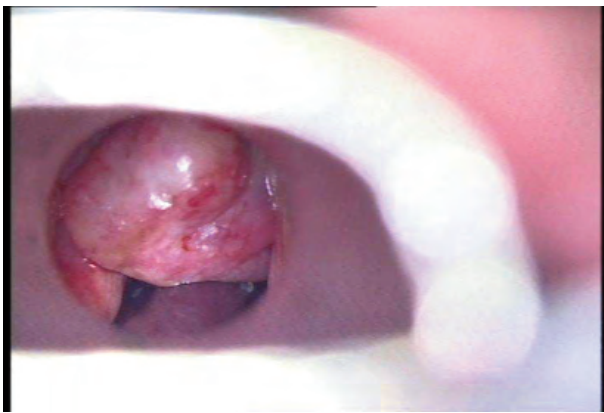


Figure 1. The photograph showing the right vocal cord hemangioma taken during suspension microlaryngoscopy.

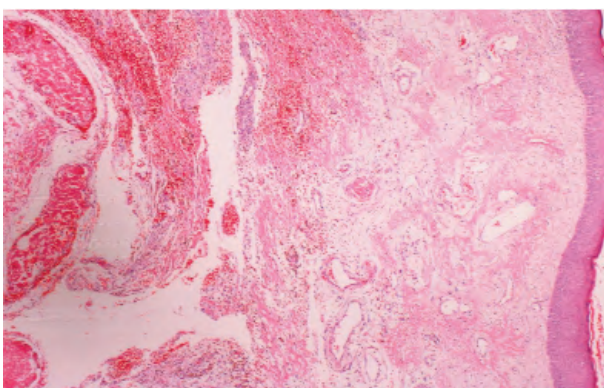


Figure 2. Lesion including erythrocytes in the lumen of vessels. These are increased number and various diameters of vessels under squamous epithelial mucosa (HE x 20).

Discussion

The first laryngeal hemangioma was described by MacKenzie in 1871 (5). In 1921, Sweetser first, differentiated subglottic hemangioma of infancy from glottic and supraglottic hemangiomas of adulthood (6). Laryngeal hemangioma is a very rare condition in adults. The etiologic factors are thought to be vocal abuse, cigarette smoking and laryngeal trauma (7). Our patient in this case report was not a cigarette smoker and he had no history of intubation and laryngeal trauma. However, he had history of vocal abuse. Respiratory distress is almost never seen in adults (7). Our patient's main complaint was hoarseness, but he also had slight difficulty in breathing with effort.

The site of origin varies, and they can be seen at or above the level of the vocal cords. Usually hemangiomas of vocal cords originate from free edges (1).

These lesions are generally of the cavernous type. When lesional are considerably enlarged, the term of cavernous hemangioma has traditionally been applied. Cavernous hemangioma differs from capillary hemangiomas, because its vascular channels are less well circumscribed and larger and usually deeper in submucosal tissues. Sluggish blood flow may result in organized or dystrophically calcified thrombi within dilated vessels. The phonation sign of Menzel, which consists of increased firmness, erection, and deepening color of the growth during phonation, and may be of diagnostic value (7).

There is no consensus about the treatment of hemangiomas. Factors influencing choice of therapy are patient's age, type, size and localization of the tumor. Infantile hemangiomas result in no significant discomfort and we can expect spontaneous regression (4). However, large hemangiomas are treated surgically and by radiotherapy. Adult hemangiomas do not show tendency of spontaneous regression. Generally, they are not very progressive tumors, and in most cases clinical observation is the best therapy. If bleeding, stenosis of respiratory tract and cosmetic problems occur, aggressive therapies are needed. Small hemangiomas can be managed conservatively. Large hemangiomas may require treatment. Systemic steroids and radiation

therapy have been used, and CO₂ laser excision of the lesions is generally accepted (2). In large lesions tracheotomy may be required, excision with microlaryngoscopic technique can be used, as we preferred in our patient.

Conclusion: Vocal cord is a very rare localization for hemangiomas in adults, and they generally cause hoarseness. Excision of the lesion with microlaryngoscopic techniques can be applied very successfully (3, 8, 9).

References

1. Shpitzer T, Noyek AM, Witterrick I, Kassel T, Ichise M, Gullane P et al. Noncutaneous cavernous hemangiomas of the head and neck. *Am J Otolaryngol* 1997;18:367-74.
2. Kawakami M, Hayashi I, Yohimura K, Ichihara K, Nishikawas S, Ichihara T. Adult giant hemangioma of the larynx. *Auris Nasus Larynx* 2006; 33(4): 479-482.
3. Yılmaz MD, Aktepe F, Altuntaş A. Cavernous hemangiomas of the left vocal cord. *Eur Arch Otorhinolaryngol* 2004; 216(6): 310-311.
4. Berkes B, Sente M. Adult laryngeal hemangioma. *Med pregl* 1998; 51(11-12): 547-50.
5. M. MacKenzie. *Essay on Growth of the Larynx*. Lindsay and Blakeston. Philadelphia 1871.
6. T.H. Sweetser. Hemangiomas of the larynx. *Laryngoscope* 1921; 31: 797-806.
7. Kimmelman CP, Sugar JO, Lowry LD. Resident's page. Pathologic quiz case 2. Hemangioma of the vocal cord. *Arch Otolaryngol* 1979; 105(8): 500-502.
8. Bielałowicz S, Stager S, Soofer S. Vocal fold hemangioma. *Ear Nose Throat* 2000; 79(4): 230.
9. Sataloff RT, Spiegel JR, Rosen DC, Hawkshaw MJ. Capillary hemangioma of the vocal cord. *Ear Nose Throat* 1995; 74(6): 390.