

1-1-2009

## A rare cause of neonatal hypocalcemia: malignant infantile osteopetrosis

HAKAN UZUN

EBRU YILMAZ KESKİN

DURSUN ALİ ŞENSES

AYHAN ERDEM

BÜNYAMİN DİKİCİ

*See next page for additional authors*

Follow this and additional works at: <https://journals.tubitak.gov.tr/medical>



Part of the [Medical Sciences Commons](#)

---

### Recommended Citation

UZUN, HAKAN; KESKİN, EBRU YILMAZ; ŞENSES, DURSUN ALİ; ERDEM, AYHAN; DİKİCİ, BÜNYAMİN; and KOCABAY, KENAN (2009) "A rare cause of neonatal hypocalcemia: malignant infantile osteopetrosis," *Turkish Journal of Medical Sciences*: Vol. 39: No. 3, Article 17. <https://doi.org/10.3906/sag-0709-20>  
Available at: <https://journals.tubitak.gov.tr/medical/vol39/iss3/17>

This Article is brought to you for free and open access by TÜBİTAK Academic Journals. It has been accepted for inclusion in Turkish Journal of Medical Sciences by an authorized editor of TÜBİTAK Academic Journals. For more information, please contact [academic.publications@tubitak.gov.tr](mailto:academic.publications@tubitak.gov.tr).

---

## A rare cause of neonatal hypocalcemia: malignant infantile osteopetrosis

### Authors

HAKAN UZUN, EBRU YILMAZ KESKİN, DURSUN ALİ ŐENSES, AYHAN ERDEM, BÜNYAMİN DİKİCİ, and  
KENAN KOCABAY

Hakan UZUN<sup>1</sup>  
Ebru YILMAZ KESKİN<sup>2</sup>  
Dursun Ali ŞENSES<sup>1</sup>  
Ayhan ERDEM<sup>1</sup>  
Bunyamin DİKİCİ<sup>1</sup>  
Kenan KOCABAY<sup>1</sup>

## A rare cause of neonatal hypocalcemia: malignant infantile osteopetrosis

**Abstract:** Malignant infantile osteopetrosis (MIOP) is a rare inherited bone disease characterized by reduced or dysregulated activity of osteoclasts, which results in generalized osteosclerosis. This leads to abnormal bone marrow cavity formation and to the clinical signs and symptoms of bone marrow failure and nerve compression. Symptoms related to early or late hypocalcemia may appear as the first presentation of MIOP in a newborn. We present a 14-day-old boy with neonatal hypocalcaemia due to MIOP.

Key Words: Malignant infantile osteopetrosis, neonatal hypocalcaemia

### Neonatal hipokalseminin nadir bir nedeni: malign infantil osteopetrozis

**Özet:** Malign infantil osteopetrozis (MIOP), osteoklast aktivitesinde azalma veya regülasyon bozukluğu sonucunda yaygın osteoskleroza yol açan nadir bir herediter hastalıktır. Bu durum anormal kemik kavitesi, bunun sonucu olarak kemik iliği yetmezliği ve sinir basısına ait klinik bulgularla kendini gösterir. MIOP ilk olarak erken veya geç neonatal hipokalsemi ile ilişkili semptomlarla kendini gösterebilir. MIOP'a bağlı neonatal hipokalsemi görülen 14 günlük bir olguyu sunduk.

Anahtar Sözcükler: Malign infantil osteopetrozis, neonatal hipokalsemi

### Introduction

Malignant infantile osteopetrosis (MIOP) is a rare autosomal recessive disorder characterized by presentation within the first few months of life, and manifestations relating to an underlying defect in osteoclastic bone resorption. In such a condition, abnormal osteoclast activity paired with normal bone formation by osteoblasts leads to the development of densely sclerotic fragile bones. Accumulation of sclerotic bone results in reduced marrow space and narrowed osseous foramina. Major consequences include marrow failure (pancytopenia), extramedullary hematopoiesis (hepatosplenomegaly), and nerve entrapment (progressive blindness and hearing loss) (1-4). Other presentations include failure to thrive and recurrent infections; excessive bruising, nasal congestion, and an abnormal craniofacial appearance are less common presentations (4). Osteoclasts are of hematopoietic origin; thus, hematopoietic stem cell transplantation is an effective treatment (1).

Hypocalcemia is a rare condition in association with MIOP. Hypocalcemia manifests in newborns as irritability, muscular twitching, jitteriness, tremors, convulsions, poor feeding, vomiting, and lethargy. MIOP remains essentially unrecognized by clinicians as a cause of neonatal hypocalcemia.

Herein we present a hypocalcemic neonate with MIOP.

<sup>1</sup> Department of Pediatrics,  
Faculty of Medicine,  
Düzce University,  
Düzce - TURKEY

<sup>2</sup> Department of Pediatric  
Hematology,  
Faculty of Medicine,  
Gazi University,  
Ankara - TURKEY

Received: September 21, 2007  
Accepted: January 08, 2009

#### Correspondence

Hakan UZUN  
Department of Pediatrics,  
Faculty of Medicine,  
Düzce University,  
81620 Konuralp,  
Düzce - TURKEY

uzunhakan2003@yahoo.com

### Case Report

A 14-day-old male newborn was admitted to our hospital due to decreased activity and sucking. He was born to a 20-year-old first-time mother and weighed 3400 g. There was no history of parental consanguinity. Physical examination revealed pale skin, decreased activity, and hepatosplenomegaly; the liver was 4 cm below and the spleen was 5 cm below the costal margin. Pale optic nerve heads were observed with funduscopic examination. Laboratory findings demonstrated thrombocytopenia (93,000/ $\mu$ l), low hemoglobin level (11.4 g/dl), and normal leukocyte count (7000/ $\mu$ l). Serum TORCH IgM titers were negative. Biochemical analysis revealed that aspartate aminotransferase (AST), alanine aminotransferase (ALT), total calcium, phosphorus, alkaline phosphatase, magnesium, 25-hydroxy vitamin D, and parathormone levels were 114 U/l (15-55 U/l), 36 U/l (5-45 U/l), 6.8 mg/dl

(8.8-10.8 mg/dl), 5 mg/dl (3.8-6.5 mg/dl), 900 U/l (145-420 U/l), 1.9 mg/dl (1.6-2.6 mg/dl), 11.2 ng/ml (1.9-33.4 ng/ml), and 435 pg/ml (9-65 pg/ml), respectively. Moderate bilateral hearing loss was noted with brain stem evoked response audiometry (BERA). Visual evoked potential (VEP) testing revealed low amplitude. Whole-body roentgenogram investigation demonstrated uniformly dense, homogeneous, and sclerotic bone, with the absence of corticomedular junctions (Figure 1 and 2). The mother's laboratory data revealed a phosphorus level of 3.9 mg/dl (2.7-4.7 mg/dl) and total calcium level of 9.4 mg/dl (8.4-10.2 mg/dl).

Hypocalcemia was treated with infusion of calcium gluconate (100 mg/kg IV). Because neonatal sepsis was suspected, empiric antibiotics were given, which included ampicillin and amikacin sulfate. Serum calcium level increased to 9.2 mg/dl and an

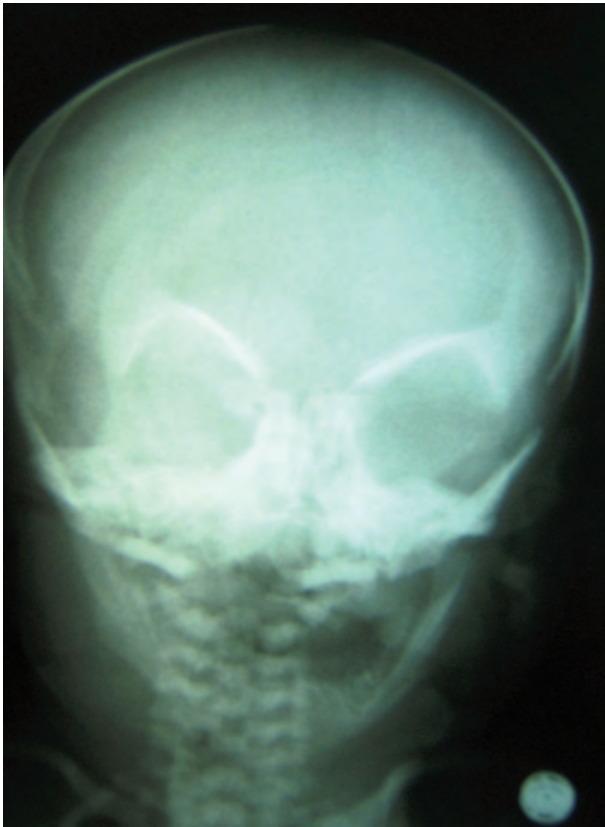


Figure 1. Frontal radiograph shows the appearance of "space alien" face.

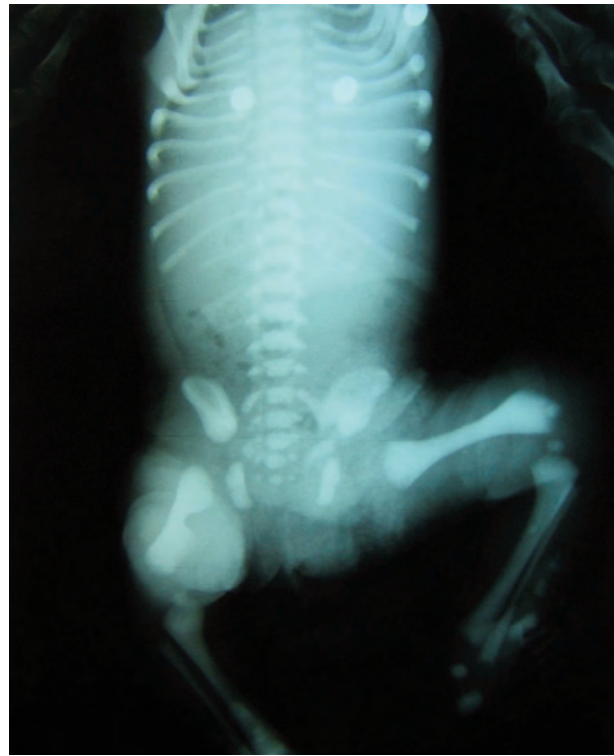


Figure 2. Typical osteopetrosis increased bone density and loss of normal corticomedular differentiation.

improvement in clinical condition was observed 2 days following the initiation of treatment. The patient was diagnosed with MIOP due to anemia and thrombocytopenia, which resulted in bone marrow failure, hepatosplenomegaly caused by extramedullary hematopoiesis, optic atrophy, hearing loss, and the accompanying radiological signs. The patient was referred to another hospital for bone marrow transplantation (BMT).

## Discussion

The primary underlying defect in all types of osteopetrosis is failure of the osteoclasts to reabsorb bone. Osteoclasts can tightly attach to the bone matrix via integrin receptors to form a sealing zone, within which a sequestered compartment is acidified. Acidification promotes solubilization of the bone mineral in the sealing zone, and various proteases—most notably cathepsin K—catalyze degradation of the matrix proteins. Additionally, actively resorbing osteoclasts release oxygen-derived radicals, in particular superoxides, which probably contribute to degradation of the bone matrix (5-7). The 3 mutations that have been linked to osteopetrosis cause defects in the acidification of bone. The most common of these, observed in 50%-60% of patients, results in defects in the A3 subunit of the osteoclast vacuolar H<sup>+</sup>-ATPase proton pump. The second most clinically significant mutation affects CLCN7, a gene encoding an osteoclast-specific chloride channel. These mutations occur in 10%-15% of patients with severe autosomal recessive osteopetrosis. Carbonic anhydrase II dysfunction is a feature of autosomal recessive osteopetrosis, but only accounts for a small proportion of patients with osteopetrosis (8).

Patients may present with growth retardation, macrocephaly, frontal bossing, delayed dental development, anemia, thrombocytopenia, hepatosplenomegaly, leukopenia, or hypocalcemic convulsions. MIOP is generally diagnosed during the first year of life, based on sclerosis in the bones and obliteration of the bone marrow. This form of the disease progresses quite rapidly, and patients usually die during the first decade of life (9). The presented case also had hepatosplenomegaly,

anemia, thrombocytopenia, and hypocalcemia at age 14 days.

Disturbances of calcium homeostasis have been well described in MIOP. The first description may have been provided by Avery et al., who described a baby born with osteopetrosis in 1956 that was a “bit twitchy” at 6 days of age (10). Srinivasan et al. reported symptomatic hypocalcemia that developed in the first month of life in 8 infants from 6 different families (11). Defective calcium metabolism was observed in several other cases of MIOP (4). Our patient’s serum calcium level was low. It was reported that patients with osteopetrosis may suffer from defective bone demineralization despite sufficient calcium and phosphorus content in their bodies, and therefore rickets may develop in these patients. This condition, which is different than osteopetrosis, has been referred to as osteopetrorickets in the literature (12-14). Parathormone and alkaline phosphatase levels were high in our patient. Increased alkaline phosphatase is a sign of defective bone mineralization, whereas a high parathormone level is caused by low serum calcium due to disturbed bone resorption by defective osteoclasts. No radiological sign supporting rickets was observed in our patient.

In MIOP, hearing loss and blindness commonly occur due to the pressure exerted on cranial nerves by sclerotic bony structures (15). In the presented case, VEP evaluation revealed bilateral vision loss, and moderate hearing loss was detected bilaterally with BERA testing.

The most effective treatment for MIOP is allogeneic BMT (1,16). When BMT cannot be performed, corticosteroids, high-dose calcitriol, erythropoietin, and interferon-gamma are among the suggested supportive treatments. High-dose steroid use has been reported to decrease bone mineral density, whereas it decreases transfusion demand at lower doses. High-dose calcitriol stimulates the bone-resorptive function of osteoclasts, while interferon-gamma slows the process by enhancing bone resorption (17-19). Among patients not transplanted, only 30% have been reported to survive until 6 years of age. Irreversible neurological signs appear as early as

infancy. When hematological defects emerge during the first 3 months of life, the prognosis is quite poor (4,20).

MIOP has an extremely poor prognosis unless treated early with hematopoietic stem cell transplantation (4). It remains essentially unrecognized as a cause of neonatal hypocalcemia,

and often results in diagnostic confusion and delay. Early diagnosis is important in the context of curative BMT, for which preservation of sight depends upon early medical intervention. MIOP should be considered in the differential diagnosis of idiopathic neonatal hypocalcemia.

## References

1. Fasth A, Porras O. Human malignant osteopetrosis: pathophysiology, management and the role of bone marrow transplantation. *Pediatr Transplant* 1999; 3: 102-7.
2. Shapiro F, Key LL, Anast C. Variable osteoclast appearance in human infantile osteopetrosis. *Calcif Tissue Int* 1988; 43: 67-76.
3. Felix R, Hofstetter W, Cecchini MG. Recent developments in the understanding of the pathophysiology of osteopetrosis. *Eur J Endocrinol* 1996; 134: 143-56.
4. Gerritsen EJA, Vossen JM, Van Loo IH, Hermans J, Helfrich MH, Griselli C et al. Autosomal recessive osteopetrosis: variability of findings at diagnosis and during the natural course. *Pediatrics* 1994; 93: 247-53.
5. Malkani K, Luxemburger MM, Rebel A. Cytoplasmic modifications at the contact zone of osteoclasts and calcified tissue in the diaphyseal growing plate of foetal guinea-pig tibia *Calcif Tissue Res* 1973; 11: 258-64.
6. Delaisse JM, Vaes G. Mechanism of mineral solubilization and matrix degradation in osteoclastic bone resorption. In: Rifkin R, Gay CV (eds). *Biology and Physiology of the Osteoclast*. London: CRC Press. 1992: 289-314.
7. Garret RI, Boyce BF, Oreffo ROC, Bonewald L, Poser J, Mundy GR. Oxygen-derived free radicals stimulate osteoclastic bone resorption in rodent bone in vitro and in vivo. *J Clin Invest* 1990; 85: 632-9.
8. Sobacchi C, Frattini A, Orchard P, Porras O, Tezcan I, Andolina M et al. The mutational spectrum of human malignant autosomal recessive osteopetrosis. *Hum Mol Genet* 2001; 10: 1767-73.
9. Abinun M, Newson T, Rowe PW, Flood TJ, Cant AJ. Importance of neurologic assessment before bone marrow transplantation for osteopetrosis. *Arch Dis Child* 1999; 80: 273-274.
10. Avery ME, Dorst JP, Walker DG. Osteopetrosis. In: Bergsma D (ed). *Clinical Delineation of Birth Defects. IV. Skeletal Dysplasia*. New York: Mosby, 1969: 305-11.
11. Srinivasan M, Abinun M, Cant AJ, Tan K, Oakhill A, Steward CG. Malignant infantile osteopetrosis presenting with neonatal hypocalcaemia. *Arch Dis Child Fetal Neonatal Ed* 2000; 83: 21-3.
12. Kaplan FS, August CS, Fallon MD, Gannon F, Haddad JG. Osteopetrorickets. The paradox of plenty. *Pathophysiology and treatment*. *Clin Orthop Relat Res* 1993; 294: 64-78.
13. Datta V, Prajapati NC, Kamble M, Pathak S. Osteopetrorickets. *Indian Pediatr* 2000; 37: 98-9.
14. Popp D, Zieger B, Schmitt-Gräff A, Nützenadel W, Schaefer F. Malignant osteopetrosis obscured by maternal vitamin D deficiency in a neonate. *Eur J Pediatr* 2000; 159: 412-415.
15. Lehman RA, Reeves JD, Wilson WB, Wesenberg RL. Neurologic complications of infantile osteopetrosis. *Ann Neurolo* 1977; 2: 378-384.
16. Dini G, Floris R, Garaventa A, Oddone M, De Stefano F, De Marco R et al. Long term follow up of two children with a variant of mild autosomal recessive osteopetrosis undergoing bone marrow transplantation. *Bone Marrow Transplant* 2000; 26: 219-224.
17. Kubo T, Tanaka H, Ono H, Moriwake T, Kanzaki S, Seino Y. Malignant osteopetrosis treated with high dose of 1- $\alpha$ -hydroxyvitamin D<sub>3</sub> and interferon gamma. *J Pediatr*. 1993; 123: 264-268.
18. Reeves JD, Huffer WE, August CS, Hathaway WE, Koerper M, Walters CE. The hematopoietic effects of prednisone therapy in four infants with osteopetrosis. *J Pediatr* 1979; 94: 210-214.
19. Del Fattore A, Peruzzi B, Rucci N, Recchia I, Cappariello A, Longo M et al. Clinical, genetic, and cellular analysis of 49 osteopetrotic patients: implications for diagnosis and treatment. *J Med Genet* 2006; 43: 315-25.
20. Coccia PF, Krivit W, Cervenka J, Clawson C, Kersey JH, Kim TH et al. Successful bone marrow transplantation for infantile malignant osteopetrosis. *N. Engl J Med* 1980; 302: 701-708.