

1-1-2009

Isolated fungal sinusitis of the sphenoid sinus

AYŞE İRİZ

MUHARREM DAĞLI

HALİT AKMANSU

ÖZGE HAN

BENĞİ ARSLAN

See next page for additional authors

Follow this and additional works at: <https://journals.tubitak.gov.tr/medical>



Part of the [Medical Sciences Commons](#)

Recommended Citation

İRİZ, AYŞE; DAĞLI, MUHARREM; AKMANSU, HALİT; HAN, ÖZGE; ARSLAN, BENĞİ; and ERYILMAZ, ADİL (2009) "Isolated fungal sinusitis of the sphenoid sinus," *Turkish Journal of Medical Sciences*: Vol. 39: No. 3, Article 16. <https://doi.org/10.3906/sag-0709-30>

Available at: <https://journals.tubitak.gov.tr/medical/vol39/iss3/16>

This Article is brought to you for free and open access by TÜBİTAK Academic Journals. It has been accepted for inclusion in Turkish Journal of Medical Sciences by an authorized editor of TÜBİTAK Academic Journals. For more information, please contact academic.publications@tubitak.gov.tr.

Isolated fungal sinusitis of the sphenoid sinus

Authors

AYŞE İRİZ, MUHARREM DAĞLI, HALİT AKMANSU, ÖZGE HAN, BENĞİ ARSLAN, and ADİL ERYILMAZ

Ayşe İRİZ¹
Muharrem DAĞLI¹
Halit AKMANSU¹
Özge HAN²
Bengi ARSLAN¹
Adil ERYILMAZ¹

Isolated fungal sinusitis of the sphenoid sinus

Abstract: Isolated fungal sphenoid sinusitis is a rare entity. Fungal sinusitis is mostly seen in immunocompromised patients and is characterized by invasive progression. We describe a immunologically competent patient with isolated aspergillosis in her sphenoid sinus.

Key Words: Isolated fungal sinusitis, sphenoid sinus, aspergillosis

Sfenoid sinüste izole fungal sinüzit

Özet: İzole fungal sinüzit son derece nadir görülür. Fungal sinüzitler genellikle immunsupresiv hastalarda invaziv seyirli olarak görülür. Bu yazıda sadece sfenoid sinüste lokalize izole aspergillozisi olan ve immun olarak sağlam bir hasta sunulmuştur.

Anahtar Sözcükler: İzole fungal sinüzit, sfenoid sinüs, aspergillozis

¹ Department of Otolaryngology,
Numune Education and
Research Hospital,
Ankara - TURKEY

² Department of Pathology,
Numune Education and
Research Hospital,
Ankara - TURKEY

Introduction

Isolated sphenoid sinus infection is rare and accounts for about 2.5% of all sinus infections (1). It is the result of the unfavorable anatomic location of the sphenoids and decreased nasal airflow in that region (2). Clinical symptoms of isolated sphenoid pathology are sometimes difficult to recognize and non-specific (1). Symptoms in these patients are variable and include headache, retro-orbital pain, diplopia, and blindness. This is due to rapidly progressive gangrenous necrosis causing early destruction of the bony walls of the sphenoid sinus, as well as involvement of the surrounding important structures (1). Aspergillosis, which is saprophytic and ubiquitous in nature, is now known to cause massive destruction of the paranasal sinuses in immunocompromised patients (3). Isolated fungal sphenoid sinusitis is very rare in immunocompetent patients (4).

Herein a case of isolated sphenoid aspergillosis is described. Surgical intervention is necessary when the sphenoid sinus is completely radio-pacified and fails to clear with medical treatment, both for diagnostic and therapeutic purposes (5).

Case Report

A 46-year-old female patient was admitted to the hospital with the complaint of headache, which began 8 months earlier. Her clinical examination was normal. Anterior and posterior rhinoscopy showed a small nasal septal deviation and slight edema of the nasal mucosa. A CT scan of the paranasal sinuses (PNS) showed an ill-defined mass in the right sphenoid sinus, with expansion to the inter-sphenoidal

Received: September 24, 2007
Accepted: December 03, 2008

Correspondence

Ayşe İRİZ
Department of Otolaryngology,
Numune Education and
Research Hospital,
Ankara - TURKEY
aysecagri@mynet.com

wall (Figure 1). Endoscopic sphenoidotomy was performed under general anesthesia. A fungating mass that was bloating the sphenoid sinus opening was removed. The ostium was widened and pus was drained (Figures 2 and 3). The surrounding sphenoid walls were normal. Biopsy and culture revealed aspergillosis of the sphenoid sinuses (Figure 4). Consequently, the patient was administered itraconazole 200 mg/day and followed-up for 2 months. The patient no longer had headache and nasal endoscopy showed that her mucosal lining was healthy. A follow-up paranasal CT scan showed that all the paranasal sinuses were normal.

Discussion

Isolated sphenoid sinusitis, in particular isolated sphenoid sinus aspergillosis, is a rare condition (3). In 1973, Wyllie et al. reported one of the earliest series (6) of isolated sphenoid lesions, which included 45 patients. In 2000, Çakmak et al. published data from 182 cases and reported 15 cases of fungal sinusitis. In another series inflammatory etiologies were responsible for 61%-80% of isolated sphenoid lesions (7). Headache is the most common presenting symptom in cases of isolated sphenoid sinus disease and is deep-seated and retro-orbital. This is due to innervation of the sphenoid sinus, via

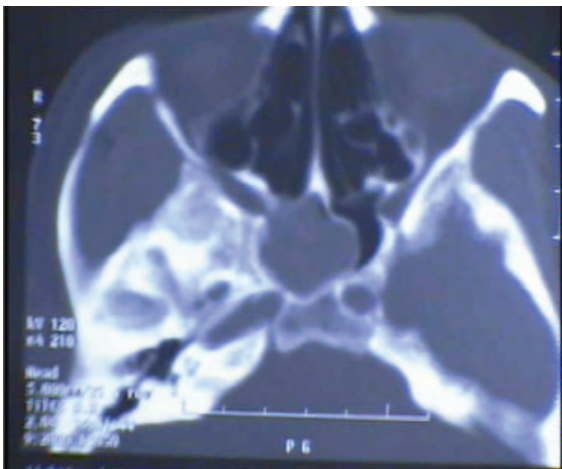


Figure 1. Axial paranasal sinus tomography shows a homogeneous increase in density filling the sphenoid sinus.

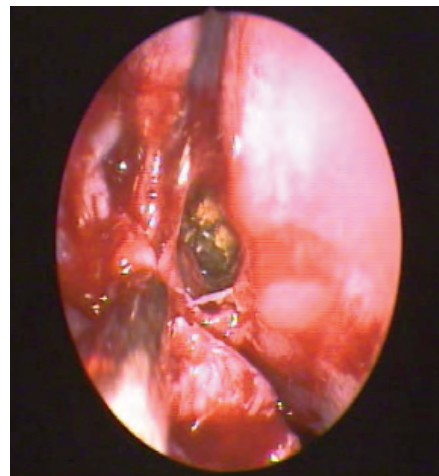


Figure 2. Mucopus in the sphenoid sinus ostium.

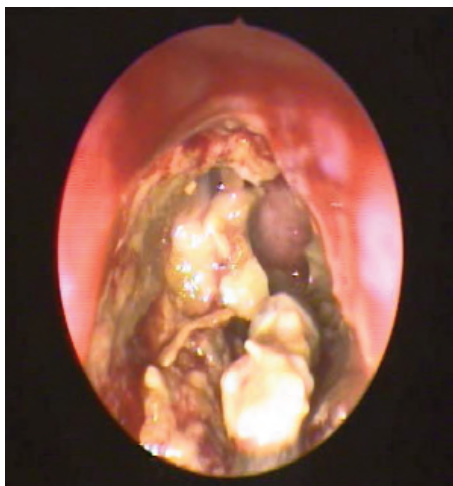


Figure 3. Yellow-green infected mucopus inside the sphenoid sinus.

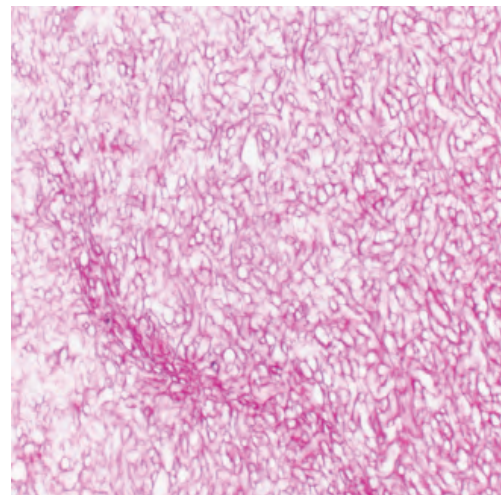


Figure 4. Histochemical staining of hyphae with PAS (400×).

both the fifth cranial nerve and afferent fibers via the sphenopalatine ganglion. Diplopia is secondary to sixth nerve palsy. Loss of vision occurs due to optic nerve palsy (8). Our patient complained of only retro-orbital headache.

Although it is almost always normal, endoscopic examination of the nasal cavities is important. Sometimes purulent secretions in the sphenoidal recess are observed (3). In our patient, endoscopic examination was normal.

Radiological diagnosis plays an important role in identifying the areas of involvement. A CT scan of the PNS showed the presence of areas of increased attenuation in the PNS and brain. This imaging technique was used to determine if there was involvement of the orbital or intracranial regions (9).

Fungal disease necessitates surgical treatment to completely remove the fungal debris. In 1973, Wyllie et al. used traditional open surgical techniques. Subsequently, other researchers reported limited series in which traditional surgical approaches were used (6). In 2000, Çakmak reported 182 cases of isolated sphenoid sinus lesions, most of which were treated via the trans-septal approach (7).

The development of rigid nasal endoscopy has significantly reduced operating time and decreased intraoperative blood loss, morbidity, and hospitalization time (10). We preferred the transnasal endoscopic approach in the presented case. Endoscopic sphenoidotomy and removal of the disease with a generous margin of healthy tissue was accomplished, ensuring ventilation of the sphenoid sinus.

In cases of aspergillosis, postoperative medical treatment is controversial. Some researchers have used only amphotericin B (11), whereas others have used only itraconazole (12). We administered 200 mg of itraconazole b.i.d. to our patient. We followed-up the patient 2 months later with a CT scan of the PNS and observed that all paranasal sinuses were normal (Figure 5).

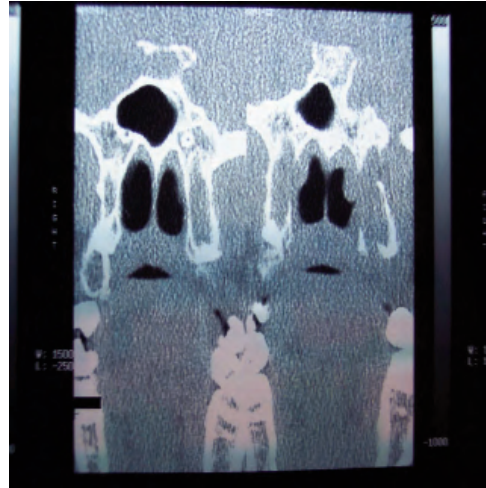


Figure 5. View of the sphenoid sinus in postoperative coronal section paranasal sinus tomography.

It is important to stress that our patient, who received medical and surgical treatment, had a symptomatic sphenoid fungal lesion necessitating endoscopic removal and postoperative antifungal treatment.

References

1. Sethi DS. Isolated sphenoid lesion: diagnosis and management. *Otolaryngol Head Neck Surg* 1999; 120: 730-736.
2. Wang ZM, Kanoh N, Dai CF, Kutler DI, Xu R, Chi FL. Isolated sphenoid sinus disease: An analysis of 122 cases. *Ann Otol Rhinol Laryngol* 2002; 111: 323-27.
3. Chopra H, Dua K, Malhotra V, Gupta RP, Puri H. Invasive fungal sinusitis of isolated sphenoid sinus in immunocompetent subjects. *Mycosis* 2006; 49: 30-36.
4. Dağlı M, Akmansu H, Goçer C, Boynueğri S, Eryılmaz A. Sphenoid Sinus Mucormycosis in an immunologically competent patient. *KBB-BBC Dergisi* 2001; 9: 48-51.
5. Kieff DA, Busaba N. Treatment of isolated sphenoid sinus inflammatory disease by endoscopic sphenoidotomy without ethmoidectomy. *Laryngoscope* 2002; 112: 2186-88.
6. Wyllie JW, Kern EB, Djalilian M. Isolated sphenoid sinus lesions. *Laryngoscope* 1973; 83: 1252-65.

7. Çakmak O, Shohet MR, Kern EB. Isolated sphenoid sinus lesions. *American Journal of Rhinology*.2000; 14: 13-19.
8. Friedman A, Batra PS, Fakhri S, Citardi MJ, Lanza DC. Isolated sphenoid sinus disease: Etiology and management. *Otolaryngol Head Neck Surgery* 2005; 133: 544-50.
9. Zinreich SJ, Kennedy DW, Malat J, Curtin HD, Epstein JJ, Huff LC. Fungal sinusitis: diagnosis with CT and MR imaging. *Radiology* 1988; 169: 439-44.
10. Castelnova P, Pagella F, Semino L, Bernardi F, Delu G. Endoscopic treatment of the isolated sphenoid sinus lesions. *Eur Arch Otorhinolaryngol* 2005; 262: 142-147.
11. Sanghvi V, Bokil K, Kelkar R. Aspergillosis of the paranasal sinuses. *Indian J Cancer* 1992; 29: 7-13.
12. Panda NK, Sharma SC, Chakrabarti A, Mann SB. Paranasal sinus mycosis in north India. *Mycosis* 1998; 41: 281-86.