

1-1-2009

## Radiological and pathological correlation in patients with bronchioloalveolar lung carcinoma

SERPİL ÖCAL

GÜLNUR ÖNDE ÜÇOLUK

BELGİN SAMURKAŞOĞLU

FUNDA DEMİRAĞ

İLKER ETİKAN

*See next page for additional authors*

Follow this and additional works at: <https://journals.tubitak.gov.tr/medical>

 Part of the [Medical Sciences Commons](#)

---

### Recommended Citation

ÖCAL, SERPİL; ÜÇOLUK, GÜLNUR ÖNDE; SAMURKAŞOĞLU, BELGİN; DEMİRAĞ, FUNDA; ETİKAN, İLKER; and BAYAZIT, PELİN (2009) "Radiological and pathological correlation in patients with bronchioloalveolar lung carcinoma," *Turkish Journal of Medical Sciences*: Vol. 39: No. 4, Article 11. <https://doi.org/10.3906/sag-0712-15>

Available at: <https://journals.tubitak.gov.tr/medical/vol39/iss4/11>

This Article is brought to you for free and open access by TÜBİTAK Academic Journals. It has been accepted for inclusion in Turkish Journal of Medical Sciences by an authorized editor of TÜBİTAK Academic Journals. For more information, please contact [academic.publications@tubitak.gov.tr](mailto:academic.publications@tubitak.gov.tr).

---

## Radiological and pathological correlation in patients with bronchioloalveolar lung carcinoma

### Authors

SERPİL ÖCAL, GÜLNUR ÖNDE ÜÇOLUK, BELGİN SAMURKAŞOĞLU, FUNDA DEMİR AĞ, İLKER ETİKAN, and PELİN BAYAZIT

Serpil ÖCAL<sup>1</sup>  
Gülnur ÖNDE ÜÇOLUK<sup>2</sup>  
Belgin SAMURKAŞOĞLU<sup>2</sup>  
Funda DEMİRRAĞ<sup>3</sup>  
İlker ETİKAN<sup>4</sup>  
Pelin BAYAZIT<sup>2</sup>

## Radiological and pathological correlation in patients with bronchioloalveolar lung carcinoma

**Aim:** To assess the correlation between pathological and radiological findings in patients with pure bronchioloalveolar carcinoma (BAC).

**Materials and Methods:** We retrospectively evaluated the pathological and radiological findings in patients with pure BAC.

**Results:** We reviewed the case records, pathological specimens, and computer files of 26 patients with a pathologic diagnosis of pure BAC during a 3-year period. There was a statistically significant relationship between pathological and radiological findings ( $X^2 = 15.143$ ,  $P = 0.004$ ). There was a correlation between mucinous pathology and diffuse pattern, as well as between non-mucinous pathology and solitary nodule/mass/cavitation. A statistically significant relationship between lymphocytic infiltration of the tumor and radiological findings was not observed ( $X^2 = 10.057$ ,  $P = 0.122$ ). A statistically significant relationship between the presence of sclerosis and radiological findings was observed ( $X^2 = 6.229$ ,  $P = 0.044$ ). In the presence of sclerosis, solitary nodule/mass/cavitation radiological findings were seen more frequently.

**Conclusions:** A diffuse radiological pattern was correlated with BAC mucinous subtype, while solitary nodule/mass/cavitation was correlated with non-mucinous pathology and the presence of sclerosis; however, we could not define a 100% relationship between them. In order to understand the biological nature of the disease, additional molecular and genetic studies are required.

**Key words:** Lung cancer, radiology of lung cancer, pathology of lung cancer, bronchioloalveolar carcinoma.

### Bronkioloalveolar akciğer karsinomlu hastalarda radyolojik ve patolojik ilişki

**Amaç:** Bu çalışmanın amacı pür bronkioloalveolar akciğer karsinomlu (BAK) hastalarda patolojik ve radyolojik bulgular arasındaki ilişkiyi değerlendirmektir.

**Yöntem ve Gereç:** Pür BAK'lı hastaların patolojik ve radyolojik bulguları retrospektif olarak incelendi.

**Bulgular:** Üç yılda pür BAK tanısı alan 26 hastanın dosyası, patolojik örnekleri ve bilgisayarlı filmleri incelendi. Müsinöz patoloji ile diffüz radyolojik patern, non-müsinöz patoloji ile soliter nodül/kitle/kaviteasyon arasında istatistiksel olarak anlamlı ilişki vardı ( $X^2 = 15,143$ ,  $P = 0,004$ ). Radyolojik lezyonla tümörün lenfositik infiltrasyonu arasında istatistiksel olarak anlamlı ilişki bulunmadı ( $X^2 = 10,057$ ,  $P = 0,122$ ). Radyolojik bulgularla ile patolojik olarak skleroz varlığı arasında istatistiksel olarak anlamlı ilişki vardı ( $X^2 = 6,229$ ,  $P = 0,044$ ). Skleroz varlığında radyolojik olarak soliter nodül/kitle/ kaviteasyon daha sık izlendi.

**Sonuç:** Çalışmamızda bronkioloalveolar karsinomun müsinöz subtipi radyolojik olarak diffüz paternle korele iken, non-müsinöz subtipi ve skleroz varlığı soliter nodül/kitle/kaviteasyonla ilişkili bulundu. Ancak aralarında yüzde yüz ilişki yoktur. Bu nedenle hastalığın biyolojik davranışını daha iyi anlamak için moleküler ve genetik çalışmalar gerekmektedir.

**Anahtar sözcükler:** Akciğer kanseri, akciğeri kanseri radyolojisi, akciğer kanseri patolojisi, bronkioloalveolar karsinoma

<sup>1</sup> Department of Chest Diseases, Faculty of Medicine, Gaziosmanpaşa University, Tokat - TURKEY

<sup>2</sup> Department of Chest Diseases, Atatürk Chest Diseases and Surgery Center, Ankara - TURKEY

<sup>3</sup> Department of Pathology, Atatürk Chest Diseases and Surgery Center, Ankara - TURKEY

<sup>4</sup> Department of Biostatistics, Faculty of Medicine, Gaziosmanpaşa University, Tokat - TURKEY

Received: December 13, 2007  
Accepted: April 21, 2009

#### Correspondence

Serpil ÖCAL  
Department of Chest Diseases,  
Faculty of Medicine,  
Gaziosmanpaşa University,  
60100 Tokat - TURKEY

drserpilgocmen@yahoo.com

## Introduction

Pulmonary adenocarcinoma is the most common histological type of lung cancer (1). According to the World Health Organization (WHO) 1999 classification, bronchioloalveolar carcinoma (BAC) is a subtype of adenocarcinoma (2). The rise in the incidence of adenocarcinoma has resulted in a significant rise in the incidence of BAC (3).

Many clinical, radiological, and histopathological features of BAC differ from those of other pulmonary carcinomas. As described by the WHO in 1999, BAC is a tumor localized to the peripheral parenchyma, without extra-pulmonary primary adenocarcinoma or central histological types of lung cancer, and extends through the alveolar structure without making any distortion in the pulmonary interstitium (lepidic growth pattern). In cases with pure BAC no stromal, vascular, or pleural invasion is observed. If there is invasion, then it is referred to as mixed-type adenocarcinoma with a BAC component (2). The WHO classification of 2004 kept the same criteria that were included in the WHO classification of 1999. BAC has a better prognosis than other adenocarcinomas (4,5). Okada et al. reported that adenocarcinomas with a greater ratio of BAC components were less aggressive (6).

A solitary pulmonary nodule/mass is the most frequent radiographic finding in BAC patients. Focal/multilobar consolidation, ground-glass opacity, multiple nodules, cavitation, and pleural fluid can also be seen (7). BAC is pathologically classified into 3 subgroups: mucinous, non-mucinous, and mixed-type (2). The relationship between radiological findings and these 3 histopathologic subgroups is still unclear. As some studies were performed before 1999, cases diagnosed according to the new criteria were not included in those studies. Moreover, except for solitary pulmonary nodules/masses, the other described radiological findings are not homogeneous to be compared (3,8). Okubo et al. reported that infiltrative radiological findings correlated with mucinous histology, and mass lesions correlated with non-mucinous histology and the presence of sclerosis; however, most tumors in their study were a mixture of BAC and adenocarcinoma, whereas a pure BAC pattern was seen in only 17 of 119 patients (9).

The biological behaviors of the subtypes of adenocarcinoma are heterogeneous. In the present study, in order to solve this heterogeneity problem we included only cases of pure BAC, not adenocarcinoma cases of BAC components. Clinical, pathological and radiological features of these cases were reviewed and the correlation between pathological and radiological findings was investigated. Moreover, smoking—whose role in BAC remains unclear—was evaluated.

## Methods

**Patients:** Patients diagnosed in our hospital with pure BAC during a 36-month period were evaluated retrospectively. The records of all patients were reviewed based on the following epidemiological and clinical characteristics: sex, age, occupational status, smoking history (packs per year), and symptoms.

**Radiological Evaluation:** Thorax computed tomography (CT) of each case was reviewed by 1 radiologist and 1 chest physician. Radiological findings were classified as follows (5, 10-12):

1. Solitary pulmonary nodule/mass;
2. Focal consolidation;
3. Diffuse pattern: Bilateral multilobar, bilateral multicentric, unilateral multicentric, unilateral multilobar;
4. Solitary cavitation.

Multicentric involvement is the presence of nodules and/or infiltration within the same lobe, whereas multilobar involvement is the presence of nodules and/or infiltration within more than 1 lobe; unilateral is involvement of 1 lung, bilateral involvement of both lungs.

**Pathologic Evaluation:** All cases of BAC were reevaluated histopathologically. Patients with pure BAC according to the 1999 WHO diagnostic criteria were included. Tumors were classified into 3 subgroups: mucinous, non-mucinous, and mixed-type (mucinous + non-mucinous). Enlargement of tumor stroma due to connective tissue proliferation was interpreted as sclerosis. Lymphocytic infiltration in tumor stroma was graded from 0 to 3 with a semi-quantitative scoring system:

Grade 0: no lymphocyte infiltration

Grade 1: mild degree of lymphocyte infiltration;

Grade 2: moderate degree of lymphocyte infiltration;

Grade 3: severe degree of lymphocyte infiltration.

**Statistical Analysis:** Acquired data were analyzed using SPSS v.11.5 for Windows. The values and data obtained from the analyses were evaluated as means ± standard deviation. In cross-tables the chi-square test (maximum ability rate) was used. As frequency distribution of the evaluated parameters was not sufficient for statistical analysis, those with a low frequency were combined with an appropriate group.

**Results**

In all, 26 cases (9 female, 34.6%) were included in the present study. Mean age of the cases patients 60.6 ± 9.6 years (range: 47-77 years). Occupational status of the patients is shown in the Figure. Fifteen of the patients (57.7%) were smokers; 1 female and 14 males had a history of smoking. The smokers averaged 22.1 ± 24.3 packs per year, with a distribution between 0 and 80. Six of the cases were asymptomatic (23.1%). Cough, dyspnea, and chest pain were the most common symptoms. Differences between the smokers and non-smokers in terms of the distribution of symptoms were not significant ( $X^2 = 8.518, P = 0.130$ ). The distribution of radiological findings is given in Table 1.

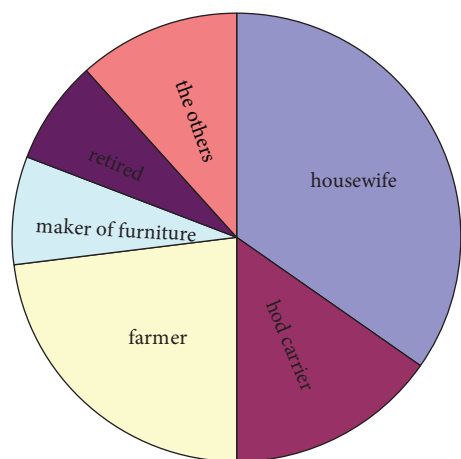


Figure. Distribution of the cases according to occupation.

Table 1. Distribution of radiological findings.

Radiological Findings		n	%
Solitary nodule/mass		11	42.3
Focal consolidation		3	11.5
Diffuse	Unilateral multilobar	2	7.7
	Unilateral multicentric	0	0.0
	Bilateral multilobar	7	26.9
	Bilateral multicentric	1	3.8
Solitary cavitation		2	7.7
<b>Total</b>	26	100.0	

The distribution of pathological subtypes was as follows: 7 cases (26.9%) were mucinous, 13 (50.0%) were non-mucinous, and 5 (19.2%) were mixed subtype. There were 7 cases (26.9%) with lymphocytic grade 0, 12 cases (46.2%) with lymphocytic grade 1, 3 cases (11.5%) with lymphocytic grade 2, and 3 cases (11.5%) with lymphocytic grade 3. Sclerosis was observed in 10 cases (38.5%). Pathological samples of 1 case could not be found. The distribution of radiological findings according to pathological subtypes is shown in Table 2.

There was a statistically significant relationship between the distribution of radiological and pathological findings ( $X^2 = 15.143, P = 0.004$ ). We grouped solitary nodule/mass and cavitation together because of the small number of patients. A diffuse radiological pattern correlated with mucinous pathology, and solitary nodule/mass/cavitation radiological findings correlated with non-mucinous pathology. The distribution of radiological findings according to lymphocytic infiltration and sclerosis is shown in Tables 3 and 4.

There was not a statistically significant relationship between lymphocytic infiltration of the tumor and radiological findings ( $X^2 = 10.057, P = 0.122$ ); however, a statistically significant relationship was observed between the presence of sclerosis and distribution of radiological findings ( $X^2 = 6.229, P = 0.044$ ). In the presence of sclerosis, solitary nodule/mass/cavitation was seen more frequently. There was not a statistically significant relationship

Table 2. Distribution of radiological findings according to pathological subtype.

Pathologic subtypes		Solitary nodule/ mass/cavitation	Focal consolidation	Diffuse pattern	Total
<b>Mucinous</b>	Number	0	2	5	7
	Pathologic subtype %	0.0%	28.6%	71.4%	100.0%
	Total %	0.0%	8.0%	20.0%	28.8%
<b>Non-mucinous</b>	Number	10	1	2	13
	Pathologic subtype %	76.9%	7.7%	15.4%	100.0%
	Total %	40.0%	4.0%	8.0%	52.0%
<b>Mixed</b>	Number	3	0	2	5
	Pathologic subtype %	60.0%	0.0%	40.0%	100.0%
	Total %	12.2%	0.0%	8.0%	20.0%
<b>Total</b>	Number	13	3	9	25
	Pathologic subtype %	52.0%	12.0%	36.0%	100.0%
	Total %	52.0%	12.0%	36.0%	100.0%

$X^2 = 15.143$ ,  $P = 0.004$ .

Table 3. Distribution of radiological findings according to lymphocytic infiltration.

Lymphocytic infiltration		Solitary nodule/ mass/cavitation	Focal consolidation	Diffuse pattern	Total
<b>0</b>	Number	3	0	4	7
	Lymphocytic infiltration %	42.9%	0.0%	57.1%	100.0%
	Total %	12.0%	0.0%	16.0%	28.0%
<b>1</b>	Number	5	2	5	12
	Lymphocytic infiltration %	41.7%	16.7%	41.7%	100.0%
	Total %	20.0%	8.0%	20.0%	48.0%
<b>2</b>	Number	2	1	0	3
	Lymphocytic infiltration %	66.0%	33.3%	0.0%	100.0%
	Total %	8.0%	4.0%	0.0%	12.0%
<b>3</b>	Number	3	0	0	3
	Lymphocytic infiltration %	100.0%	0.0%	0.0%	100.0%
	Total %	12.0%	0.0%	0.0%	12.0%
<b>Total</b>	Number	13	3	9	25
	Lymphocytic infiltration %	52.0%	12.0%	36.0%	100.0%
	Total %	52.0%	12.0%	36.0%	100.0%

$X^2 = 10.057$ ,  $P = 0.122$ .

Table 4. Distribution of radiological findings according to the presence of sclerosis.

Sclerosis		Solitary nodule/ mass/cavitation	Focal consolidation	Diffuse pattern	Total
<b>Present</b>	Number	8	1	1	10
	In sclerosis %	80.0%	10.0%	10.0%	100.0%
	Total %	32.0%	4.0%	4.0%	40.0%
<b>Absent</b>	Number	5	2	8	15
	In sclerosis %	33.3%	13.3%	53.3%	100.0%
	Total%	20.0%	8.0%	32.0%	60.0%
<b>Total</b>	Number	13	3	9	25
	In sclerosis %	52.0%	12.0%	36.0%	100.0%
	Total %	52.0%	12.0%	36.0%	100.0%

$X^2 = 6.229, P = 0.044.$

between the smoking habits of the patients and radiological findings ( $X^2 = 4.275, P = 0.118$ ).

## Discussion

Although there has been a recent increase in the incidence of BAC, not much is known about it. Some researchers reported a strong female predominance (3,9,13). In 2 of those reports, not only pure BAC cases but also mixed-type adenocarcinoma cases were included. As adenocarcinoma is more common among women, female predominance can be observed in those (3,9). Some studies, however, including the present one, observed a male predominance (4,14). While studies published before 1999 report that BAC was more common among women, those published after 1999 report that BAC is more common among men. This change can be due to revision of the WHO description of BAC, or it can be suggested that the increase in the incidence of BAC among men is greater than that in women. The change in the sex distribution of BAC during these 10 years might be important for etiological studies. In the present study mean age of the patients was 60 years; in other studies it varies between 59 and 65 years (3,9,13).

The cause of the increase in the incidence of BAC is not known. Most of our cases were of a low socioeconomic level. This situation can cause a combination of risk factors, such as air pollution, jobs

that require intense physical exertion, smoking habits, and nutritional problems. The etiologic role of smoking remains unclear. It is generally reported that BAC is more common among the non-smoking population (4,7) In the present study the mean smoking rate was 57%, whereas it was 70% in a study by Barsky et al., 77% in a study by Okubo et al., and 79% in a study by Albertine et al. (3,9,13). Those reports and their results suggest a possible relationship between BAC and smoking, but possibly not a very strong one as in squamous cell and small cell carcinomas. Thun et al. have suggested that the pathogenesis of BAC varies according to cigarette design, e.g. the smoke in filter-tip cigarettes is inhaled more deeply than smoke from previous types of cigarettes, and this deeper inhalation transports tobacco-specific carcinogens more distally toward the bronchoalveolar junction, where adenocarcinomas and BAC often arise (15). Recent evidence indicates that as the nicotine and tar content of cigarettes have dropped there has been a concomitant change in the histologic types of lung cancer (16).

Most of the patients are completely asymptomatic (17); however, the number of asymptomatic patients was much lower in the present series. The reason for this difference is unclear. The most common symptom in BAC is a cough (8,9,11,14,17). We observed no correlation between the smoking status of patients and distribution of symptoms.



In BAC cases, different lesions, such as pulmonary nodule/mass, ground glass opacity, non-well-identified patch consolidation, multiple nodules, pleural fluid, and lymph node invasion in the mediastinum can be observed alone or in combination. Unfortunately, when each is identified individually, their frequency is insufficient for statistical analysis. In all of the studies solitary pulmonary nodule/mass group is homogeneous, but the other radiological lesions have been defined differently. In the present study, we classified the diffuse pattern as bilateral multilobar, bilateral multicentric, unilateral multilobar, or unilateral multicentric. In using this classification we included multilobar consolidation in the diffuse pattern group, whereas other studies did not. Furthermore, we grouped focal consolidation separately, as it is resectable.

Solitary pulmonary nodules and masses in BAC are not different from those of other lung carcinomas, but they are typically located in the lung periphery. Frequently, solitary pulmonary nodules have pleural retraction and a central scar (17). The most common radiological finding in the present study was also solitary nodules/masses and 72.7% of those lesions were peripheral. Volpino et al. reported peripheral lesions at the rate of 82.9% (18). Solitary pulmonary nodules/masses seldom show cavitation. Only 2 of our cases had a cavitation.

Focal consolidation was seen in 11.1% of our cases. In Liu et al.'s study it was reported as 11.8% (14). Focal consolidation can cover a single segment or an entire lobe. No volume loss is visible, air bronchograms are visible, and it can imitate streptococcal pneumonia. It is not possible to distinguish it from inflammatory pneumonia using CT or high resolution CT (17).

Gaeta et al. reported that the mucinous subtype is the most prone to developing diffuse disease, probably representing aerogenous spread. They observed low levels of  $\alpha$ 2-integrin receptors in BAC (18). In the present study a diffuse radiological pattern correlated with mucinous pathology, and solitary nodule/mass/cavitation radiological findings correlated with non-mucinous pathology. Similar to our results Okubo et al. reported that an infiltrative pattern correlated with mucinous histology, and mass lesions correlated with non-mucinous histology (9). While they studied only 17 patients with pure BAC pattern, we studied 26 patients with a pure BAC pattern. Barsky et al. reported that the mucinous subtype was more strongly associated with diffuse pulmonary involvement and that the sclerotic subtype was more strongly associated with multifocal involvement. They included 25 patients with BAC, but the study was conducted before publication of the revised WHO classification (3). In contrast, the sclerotic subtype was associated with solitary nodules/masses in the present study. This has been reported by others (9). In addition, we also evaluated the lymphocytic infiltration of the tumors. There was no correlation between lymphocytic infiltration and radiological findings.

In conclusion, a diffuse radiological pattern correlated with mucinous subtype, while solitary nodule/mass/cavitation correlated with non-mucinous histology and the presence of sclerosis; however, we could not define a 100% relationship between them. In order to better understand the biological nature of the disease additional molecular and genetic studies are required.

## References

1. Travis WD, Travis LB, Devesa SS. Lung cancer. *Cancer* 1995; 75: 191-202.
2. Travis TV, Colby TV, Corrin B, Shimosato Y, Brambilla E. Histologic and graphical text slides for the histologic typing of lung and pleural tumors. In: World Health Organisation Pathology Panel: World Health Organization. *International Histological Classification of Tumors*. 3rd ed. Springer Verlag, Berlin, 1999.
3. Barsky SH, Cameron R, Osann KE, Tomita D, Holmes EC. Rising incidence of bronchioloalveolar lung carcinoma and its unique clinicopathologic features. *Cancer* 1994; 73: 1163-1170.
4. Breathnach OS, Ishibe N, Williams J, Linnoila RI, Caporaso N, Johnson BE. Clinical features of patients with stage IIIB and IV bronchioloalveolar carcinoma of the lung. *Cancer* 1999; 86: 1165-1173.



5. Sakurai H, Dobashi Y, Mizutani E, Matsubara H, Sizuki S, Takano K et al. Bronchioloalveolar Carcinoma of the Lung 3 Centimeters or Less in Diameter: A Prognostic Assessment. *Ann Thorac Surg* 2004; 78: 1728-1733.
6. Okada M, Nishio W, Sakamoto T, Uchino K, Hanioka K, Ohbayashi et al. Correlation between computed tomographic findings, bronchioloalveolar carcinoma component and biologic behavior of small-sized lung adenocarcinomas. *J Thorac and Cardiovasc Surg* 2004; 127: 857-861.
7. Armstrong P. Neoplasms of the Lungs, Airways and Pleura. In: Armstrong P, Wilson GA, Dee P, Hansel DM, editors. *Imaging Disease of Chest*. 3rd ed. London: Harcourt Publishers; 2000. p.332-335.
8. Regnard JF, Santelmo N, Romdhani N, Gharbi N, Bourcereau J, Dulmet E et al. Bronchoalveolar Lung Carcinoma: Results of Surgical Treatment and Prognostic Factors. *Chest* 1998; 114: 45-50.
9. Okubo K, Mark EJ, Flieder D, Wain JC, Wright CD, Moncre AC et al. Bronchioloalveolar Carcinoma: Clinical, Radiologic and Pathologic Factors and Survival. *J Thorac Cardiovasc Surg* 1999; 118: 702-709.
10. Bonomo L, Storto ML, Ciccotosto C, Polverosi R, Merlino B, Bellelli M et al. Bronchioloalveolar carcinoma of the lung. *Eur Radiol* 1998; 8: 996-1001
11. Lee KS, Kim Y, Han J, Ko EJ, Park CK, Primack SL, et al. Bronchioloalveolar carcinoma: clinical, histopathologic and radiologic findings. *Radiographics* 1997; 17:1345-1357.
12. Akata S, Fukushima A, Kakizaki D, Abe K, Amino S. CT scanning of bronchioloalveolar carcinoma: specific appearances. *Lung Cancer* 1995; 12:221-230.
13. Albertine KH, Steiner RM, Radack DM, Golding DM, Peterson D, Cohn HE et al. Analysis of Cell Type and Radiographic Presentation as Predictors of the Clinical Course of Patients with Bronchioloalveolar Cell Carcinoma. *Chest* 1998; 113: 997-1006.
14. Liu Y, Chen YM, Huang MH, Perng RP. Prognosis and Recurrent Patterns in Bronchioloalveolar Carcinoma. *Chest* 2000; 118: 940-7.
15. Thun MJ, Lally CA, Flannery JT, Calle EE, Flanders WD, Heath CW. Cigarette smoking and changes in the histopathology of lung cancer. *J Natl Cancer Inst* 1997; 89: 1580-1586.
16. Devasa SS, Shaw GL, Blot WJ. Changing patterns of lung cancer incidence by histologic type. *Cancer Epidemiol Biomarkers Prev* 1991; 1: 29-33.
17. Fraser RS, Colman N, Müller NL, Pare PD. Pulmonary Neoplasms. In: Fraser RS, Colman N, Müller NL, Pare PD, editors. *Diagnosis of Diseases of the Chest*. 4th ed. Philadelphia: WB Saunders Company; 1999. p.1069-228.
18. Gaeta M, Blandino A, Pergolizzi S, Mazziotti S, Caruso R, Barone M et al. Patterns of recurrence of bronchioloalveolar cell carcinoma after surgical resection: a radiological, histological and immunohistochemical study. *Lung Cancer* 2003; 42: 319-326.