

1-1-2009

Co-occurrence of internal carotid artery agenesis with multicystic dysplastic kidney

GÜLGÜN YILMAZ OVALI

SERDAR TARHAN

PETEK BAYINDIR

MUZAFFER POLAT

İPEK AKIL

Follow this and additional works at: <https://journals.tubitak.gov.tr/medical>



Part of the [Medical Sciences Commons](#)

Recommended Citation

OVALI, GÜLGÜN YILMAZ; TARHAN, SERDAR; BAYINDIR, PETEK; POLAT, MUZAFFER; and AKIL, İPEK (2009) "Co-occurrence of internal carotid artery agenesis with multicystic dysplastic kidney," *Turkish Journal of Medical Sciences*: Vol. 39: No. 5, Article 23. <https://doi.org/10.3906/sag-0706-11>
Available at: <https://journals.tubitak.gov.tr/medical/vol39/iss5/23>

This Article is brought to you for free and open access by TÜBİTAK Academic Journals. It has been accepted for inclusion in Turkish Journal of Medical Sciences by an authorized editor of TÜBİTAK Academic Journals. For more information, please contact academic.publications@tubitak.gov.tr.

Gülgün YILMAZ OVALI¹
Serdar TARHAN¹
Petek BAYINDIR¹
Muzaffer POLAT²
İpek AKIL²

Co-occurrence of internal carotid artery agenesis with multicystic dysplastic kidney

Abstract: Congenital absence of Internal Carotid Artery (ICA) is a rare disorder. This anomaly may be an isolated entity or may be associated with other organ, or system anomalies (1). Multicystic Dysplastic Kidney (MCDK) is a congenital mal-development in which the renal cortex is replaced by numerous cysts of multiple sizes. Urologic and non-urologic anomalies may accompany MCDK (2). In this paper, we detail a case of congenital agenesis of ICA and the existence of MCDK. To our knowledge, this is the first of such a case to be reported regarding the co-occurrence of ICA agenesis and MCDK.

Key words: Internal Carotid Artery, Agenesis, Carotid Canal

İnternal karotid arter agenezisi ve multikistik displastik böbrek anomalisinin birlikteliği

Özet: İnternal karotid arterin (İKA) yokluğu nadir bir durumdur. Bu anomali izole görülebileceği gibi diğer organ ve sistem anomalileri ile birliktelik gösterebilir (1). Multikistik displastik böbrek (MKDB) renal korteksin değişik boyutta birçok kist ile kaplanması ile karakterize konjenital bir hastalıktır. Ürolojik ve non ürolojik anomaliler MKDB'e eşlik edebilir (2). İKA yokluğuna multikistik displastik böbrek anomalisinin eşlik ettiği olgumuz sunulmaktadır. Bilgimize göre olgumuz literatürde İKA yokluğu ve MKDB birlikteliğinin ilk sunulmuş formudur.

Anahtar sözcükler: İnternal Karotid Arter, Agenezi, Karotid Kanal

Introduction

Major congenital anomalies of ICA are rare and can be classified as agenesis, aplasia or hypoplasia, occurring in less than 0.01% of the population (1-3). The term 'agenesis' is used when ICA is absent, whereas 'aplasia' denotes that vestiges are present and 'hypoplasia' that the vessel is present, but small (4). Unlike ICA agenesis, MCDK is a relatively common form of renal pathology. The MCDK can be unilateral, bilateral or segmental; it probably results from atresia of the ureteral bud system during embryogenesis. The incidence of MCDK is approximately 1:4,300 of live births (5). Urologic and non-urologic anomalies may accompany MCDK (2).

In the following report, we note the co-occurrence of ICA agenesis and MDCK.

Case report

A two-month old male patient exhibited a failure to thrive and diarrhea, which started a few days after birth. Past medical history and family history were nondescript. Physical examination revealed a severely dehydrated male infant of 2,500 grams (<3 percentile) and 51 cm (<3 percentile). Other systemic assessment findings were normal, including a neurological examination. Laboratory analysis

¹ Department of Radiology,
Faculty of Medicine,
Celal Bayar University,
Manisa - TURKEY

² Department of Pediatrics,
Faculty of Medicine,
Celal Bayar University,
Manisa - TURKEY

Received: June 12, 2007
Accepted: January 27, 2009

Correspondence

Gülgün YILMAZ OVALI
Department of Radiology,
Faculty of Medicine,
Celal Bayar University,
Manisa - TURKEY

gulgun.yilmaz@bayar.edu.tr

revealed serum levels of urea, creatinine, uric acid, sodium and potassium of 238, 3.07, 9.8, 125 and 6.8 respectively. Arterial blood gas testing revealed metabolic acidosis with pH 7.04, $p\text{CO}_2$ 13.7, HCO_3^- 3.6, $p\text{O}_2$ 83.5 and SpO_2 89%. Fluid and sodium deficit therapy was initiated. Serum electrolytes normalized after one day of treatment, but urea normalized after 7 days and creatinine did not fall below 1. On the fourth and sixth days of hospitalization, he had tonic convulsions of about 2 minutes in duration. Serum electrolytes were found to be normal during this period.

The patient was examined with cranial Magnetic Resonance Imaging (MRI) and Magnetic Resonance Angiography (MRA). MRI and MRA showed the absence of flow in right ICA (Figure 1, 2). The left ICA was normal. A cranial base CT was also performed to evaluate the carotid canal. A very small carotid canal was identified on the right side (Figure 3). The left carotid canal was normal.

Abdominal US in the region of the right kidney revealed multiple cysts of different sizes (Figure 4). The left kidney's pelvis and ureter was dilated. MSUG was performed and showed GRADE 4 vesicoureteral reflux in left kidney (Figure 5). No renal function was identified on right kidney in radionuclide studies

(Figure 6). These findings suggest that the right kidney was MCDK and contralateral vesicoureteral reflux on the left side.

Discussion

The ICA agenesis is a relatively rare disorder. There are some accounts of agenesis and associated anomalies in the literature, but this is the first reported case showing the co-occurrence ICA agenesis with MCDK (1-6). At present, congenital hypopituitarism, Horner's syndrome, Klinefelter syndrome, status epilepticus, otorhinolaryngologic symptoms, hypogonadotropic hypogonadism are conditions associated with ICA agenesis (1-6).

ICA agenesis is usually incidentally detected, as the case would be with our patient. Patients are usually asymptomatic, but they may also exhibit cerebrovascular insufficiency, compression due to enlarged collateral vessels, and complications associated with cerebral aneurysms. The increased or redistributed pressure and flow in the circle of Willis has been held as aggravates for the development of

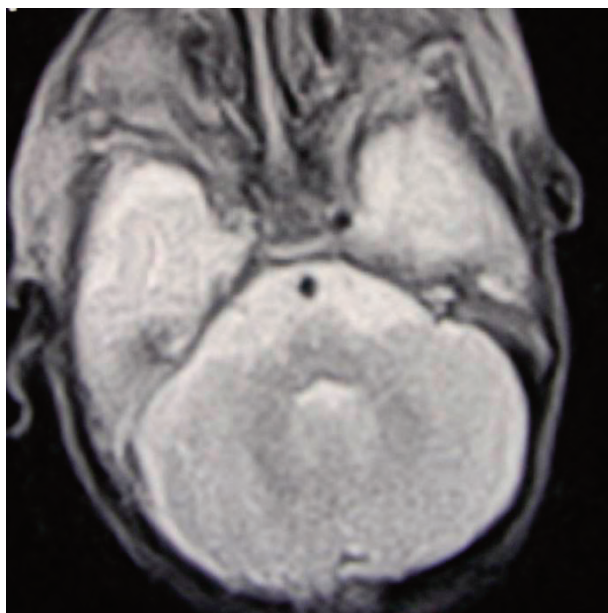


Figure 1. On T2 Weighted images, the right carotid artery is missing.

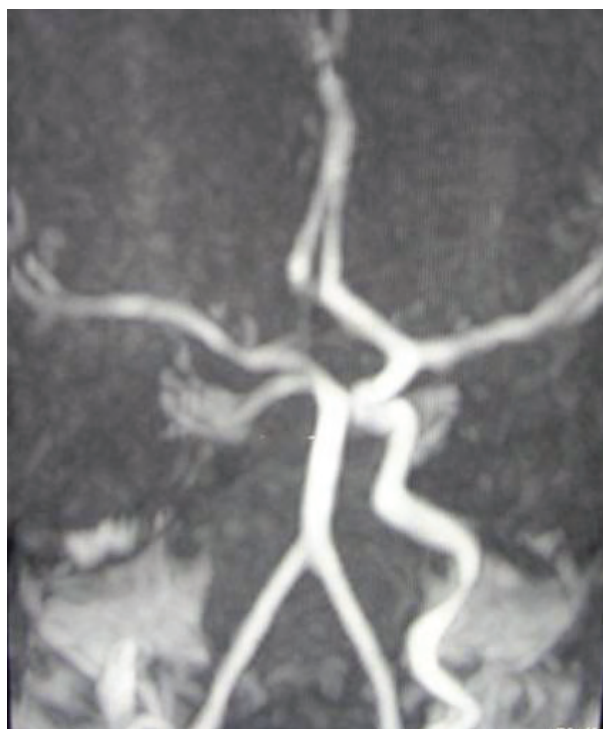

Figure 2. On MIP images of MRA, right internal carotid artery is absent.

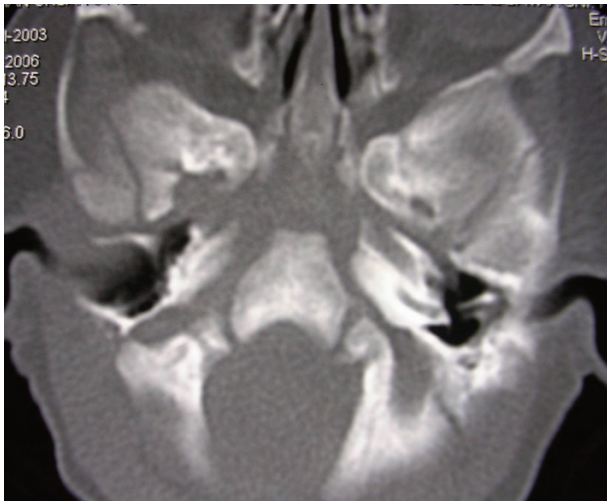


Figure 3. Cranial CT shows a very small carotid canal, whereas the left one was normal in size.

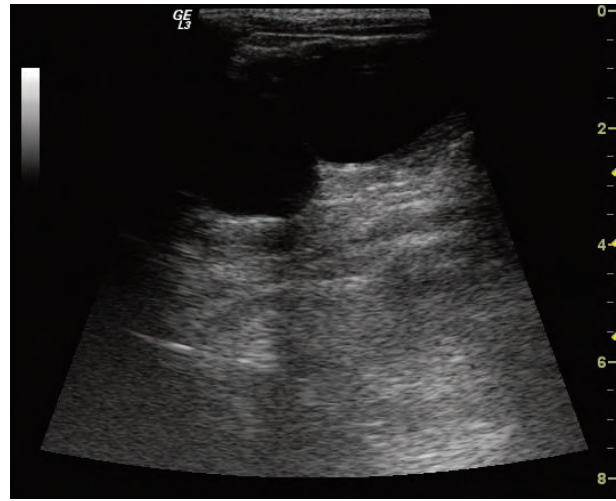


Figure 4. Multiple cysts of different sizes in the region of the right kidney on US.

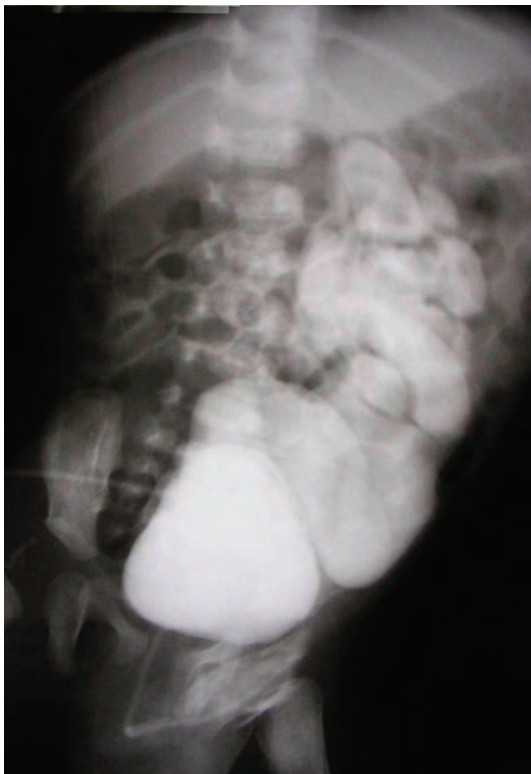

Figure 5. GRADE 4 vesicoureteral reflux in left kidney on MSUG.

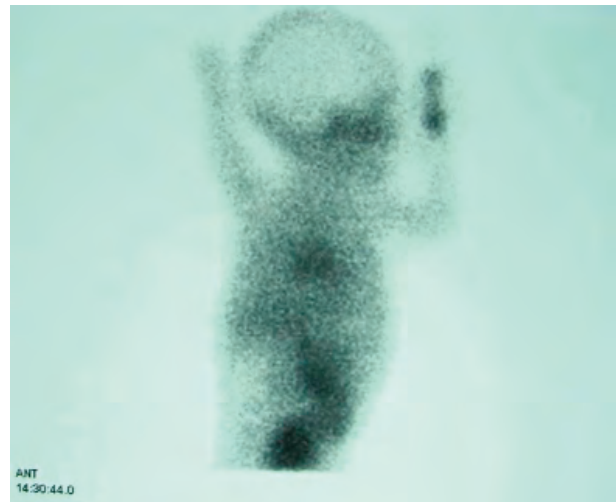


Figure 6. Radionuclide studies (A-P view of renal scintigraphy) shows that no renal function was identified on right kidney.

aneurysm (7). The estimated prevalence of cerebral aneurysms in the general population is 2% to 4%, but the reported prevalence of aneurysms in association

with absence of ICA is 24% to 34% (7, 8). Recognition of this anomaly is important not only because of the increased risk of aneurysm, but further events involving the collateral systems that might cause severe problems.

MCDK is a congenital mal-development in which the renal cortex is replaced by numerous cysts of multiple sizes (2). Dysplastic parenchyma anchors the cysts and the calyceal drainage system is absent (2). This type of disorder is usually unilateral; the bilateral

condition is incompatible with extrauterine survival. Most unilateral cases are asymptomatic, but associated anomalies effecting the contralateral kidney, which may cause problems as in our case (2,9).

Reported associated anomalies with MCDK are grouped as urologic associated and non-urologic linked abnormalities. The most common urologic associated anomaly is the contralateral vesico-ureteral reflux, as we see in our case (9). The non-renal abnormalities is more rare in unilateral multicystic dysplastic kidney disease (11%) than the bilateral form (80 %) (10). Most commonly associated syndrome is the VATER sequence (vertebral defects, anal atresia, tracheoesophageal fistula with esophageal atresia, radial and renal dysplasia). Other associated anomalies include congenital heart disease, gastrointestinal, spinal and cranial abnormalities (2, 11, 12). To our knowledge, this is the first case reported of MCDK and ICA agenesis occurring together.

ICA agenesis occurs before 24 days of embryogenesis. If the embryonic primordium of the ICA fails to develop early in embryonic life (before 3–

5 embryonic weeks), the ICA and the carotid channel cannot develop. Absence of both the ICA and the carotid channel in our patient was consistent with an infliction having occurred before 3 to 5 weeks of fetal life (13). The human metanephros arises at 5 weeks of gestation, when it consists of ureteric bud epithelium and renal mesenchymal cells, which will induce each other to form collecting ducts and nephrons respectively. The orthodox view of MCDK pathogenesis, as outlined by Potter several decades ago, is that these organs represent a primary failure of renal mesenchyme induction (14). Both ICA agenesis and MCDK occur before 3-5 embryonic weeks.

The ICA agenesis and MCDK situation needs close follow-up. Patients with agenesis of ICA are possible candidates for cerebrovascular accidents. So, close follow-up and symptomatic treatment are recommended (3).

In conclusion, it is possible for unilateral ICA agenesis and MCDK to occur together. To our knowledge this is the first of such case to reported of ICA agenesis and MCDK.

References

1. Baysefer A, Akay KM, Tasar M, Izci Y. Congenital Absence of Internal Carotid Artery Associated with Hypogonadotropic Hypogonadism. *Vascular and Endovascular Surgery* 2002; 36: 457-459.
2. Dungan JS, Fernandez MT, Abbitt PL, Thiagarajah S, Howards SS, Hogge WA. Multicystic Dysplastic Kidney: Natural History of Prenatally Detected Cases. *Prenat Diagn* 1990; 10:175-82.
3. Claros P, Bandos R, Gilea I, Clarós A, Capdevila A, García Rodríguez J, Major Congenital Anomalies of the Internal Carotid Artery-agenesis, Aplasia, and Hypoplasia. *Int J Pediatr Otorhinolaryngol* 1999; 49: 69–76.
4. Meder JF, Blustajn J, Trystram D, Godon-Hardy S, Devaux B, Zuber M. Radiologic Anatomy of Segmental Agenesis of the Internal Carotid Artery. *Surg Radiol Anat* 1997; 19:385–394.
5. Winyard P, Chitty L. Dysplastic and Polycystic Kidneys: Diagnosis, Associations and Management. *Prenat Diagn*; 2001; 21:924-925.
6. Ryan FH, Kline LB, Gomez C. Congenital Horner's Syndrome Resulting from Agenesis of the Internal Carotid Artery. *Ophthalmology* 2000; 107: 185-188.
7. Given CA, Huang-Hellinger F, Baker MD, Chepuri NB, Morris PP. Congenital Absence of the Internal Carotid Artery: Case Reports and Review of the Collateral Circulation *AJNR Am J Neuroradiol* 2001; 22: 1953–1959.
8. Afifi AK, Godersky JC, Menezes A, Smoker WR, Bell WE, Jacoby CG. Cerebral Hemiatrophy, Hypoplasia of Internal Carotid Artery, and Intracranial Aneurysm: A Rare Association Occurring in an Infant. *Arch Neurol*; 1987; 44:232–235.
9. Kaneko K, Suzuki Y, Fukuda Y, Yabuta K, Miyano T. Abnormal Contralateral Kidney in Unilateral Multicystic Dysplastic Kidney Disease. *Pediatr Radiol*; 1995; 25: 275-7.
10. Dungan JS, Fernandez MT, Abbitt PL, Thiagarajah S, Howards SS, Hogge WA. Multicystic Dysplastic Kidney: Natural History of Prenatally Detected Cases. *Prenat Diagn* 1990; 10: 175-82.
11. Blane CE, Ritchey ML, DiPietro MA, Sumida R, Bloom DA. Single System Ectopic Ureters and Ureteroceles Associated with Dysplastic Kidney. *Pediatr Radiol* 1992; 22: 217–20.
12. Fanos V, Schena S, Dal Moro A, Portuese A, Antoniazzi F. Multicystic Kidney Dysplasia and Turner Syndrome: Two Cases and a Literature Review. *Pediatr Nephrol* 2000; 14: 754–7.
13. Dinc H, Alioglu Z, Erdol H, Ahmetoglu A. Agenesis of the Internal Carotid Artery Associated with Aortic Arch Anomaly in a Patient with Congenital Horner's Syndrome. *Am J Neuroradiol* 2002; 23: 929–931.
14. Woolf AS, Price K, Scambler PJ, Winyard PJD. Evolving Concepts in Human Renal Dysplasia. *J Am Soc Nephrol* 2004; 15: 998–1007.