

1-1-2010

A comparison of the treatment of DDH in the older children by femoral shortening with a) acetabular shelf and b) innominate osteotomy plus shelf

METİN DOĞAN

SAVAŞ AĞAOĞLU

DURMUŞ ALİ ÖÇGÜDER

MAHMUT UĞURLU

RAHMİ YAVUZ ÖNEM

See next page for additional authors

Follow this and additional works at: <https://journals.tubitak.gov.tr/medical>

 Part of the [Medical Sciences Commons](#)

Recommended Citation

DOĞAN, METİN; AĞAOĞLU, SAVAŞ; ÖÇGÜDER, DURMUŞ ALİ; UĞURLU, MAHMUT; ÖNEM, RAHMİ YAVUZ; AKSOY, MUSTAFA; and BOZKURT, MURAT (2010) "A comparison of the treatment of DDH in the older children by femoral shortening with a) acetabular shelf and b) innominate osteotomy plus shelf," *Turkish Journal of Medical Sciences*: Vol. 40: No. 1, Article 13. <https://doi.org/10.3906/sag-0909-317>
Available at: <https://journals.tubitak.gov.tr/medical/vol40/iss1/13>

This Article is brought to you for free and open access by TÜBİTAK Academic Journals. It has been accepted for inclusion in Turkish Journal of Medical Sciences by an authorized editor of TÜBİTAK Academic Journals. For more information, please contact academic.publications@tubitak.gov.tr.

A comparison of the treatment of DDH in the older children by femoral shortening with a) acetabular shelf and b) innominate osteotomy plus shelf

Authors

METİN DOĞAN, SAVAŞ AĞAOĞLU, DURMUŞ ALİ ÖÇGÜDER, MAHMUT UĞURLU, RAHMİ YAVUZ ÖNEM, MUSTAFA AKSOY, and MURAT BOZKURT

A comparison of the treatment of DDH in the older children by femoral shortening with a) acetabular shelf and b) innominate osteotomy plus shelf

Metin DOĞAN¹, Savaş AĞAOĞLU², Ali ÖÇGÜDER², Mahmut UĞURLU¹,
Yavuz ÖNEM², Mustafa AKSOY³, Murat BOZKURT⁴

Aim: To examine the surgical outcome of 2 different techniques used in the treatment of developmental dislocation of the hip with delayed diagnosis.

Materials and methods: The patients were divided into 2 groups based on the technique applied: 21 hips of 18 patients were included in Group 1 and 20 hips of 16 patients were included in Group 2. Initially, all the patients were subjected to femoral osteotomy, shortening, varization and derotation. In Group 1, additionally extra-articular grafting was performed for acetabulum and in Group 2, acetabular osteotomy and extraarticular grafting were performed. The mean age of Group 1 was 8 years, and the mean age of Group 2 was 7 years.

Results: The results were evaluated radiologically and clinically. The mean follow-up time was 4 years. In the patients under 7 years of age, successful results were obtained in both groups. Of 7 patients with poor outcome, 6 were older than 7 years of age.

Conclusion: The surgical treatment of childhood developmental dislocation of the hip with delayed diagnosis is difficult. However, it can be concluded that, in patients 7 years old or younger with a diagnosis of developmental hip dislocation, the 2 techniques described here are effective.

Key words: Developmental dislocation of the hip, delayed diagnosis, acetabuloplasty techniques

İleri yaş çocuklarda gelişimsel kalça çıkığının tedavisinde femoral kısaltma ile birlikte a) Asetabuler çatı ile b) Innominant osteotomi ve çatı tekniğinin karşılaştırılması

Amaç: Çocukluk çağında geç tanı konan gelişimsel kalça çıkığının tedavisinde kullanılan iki farklı tekniğin cerrahi sonuçlarının retrospektif olarak incelenmesi.

Yöntem ve gereç: Hastalar, uygulanan teknikler baz alınarak iki gruba ayrıldı. 18 hastanın 21 kalçası grup I'yi, 16 hastanın 20 kalçası grup II'yi oluşturdu. İlk olarak tüm hastalara femur varizasyon ve derotasyon osteotomisi ve kısaltma uygulandı. Grup I'de ek olarak asetabulum için eklem dışı greftleme; Grup II'de ek olarak asetabuler osteotomi ve eklem dışı greftleme gerçekleştirildi. Grup I'de yaş ortalaması 8, grup II'de 7 idi.

Bulgular: : Sonuçlar radyolojik ve klinik olarak değerlendirildi. Ortalama takip süresi 4 yıl idi. Her iki grupta da 7 yaşın altındaki hastalarda başarılı sonuçlar elde edildi. Kötü sonuç alınan 7 hastanın 6 sı, 7 yaşından büyüktü.

Sonuç: Çocukluk çağında geç tanı konan gelişimsel kalça çıkığının tedavisi zordur. Fakat 7 yaş ve altında gelişimsel kalça çıkığı tanısı konan çocuklarda her iki cerrahi tekniğin de etkili olduğu tanımlanmıştır.

Anahtar sözcükler: Gelişimsel kalça çıkığı, geç tanı, asetabuloplasti teknikleri

Received: 30.09.2009 – Accepted: 08.01.2010

¹ Department of 4th Orthopaedics and Traumatology Clinic, Atatürk Training and Research Hospital, Bilkent, Ankara - TURKEY

² Department of 2nd Orthopaedics and Traumatology Clinic, Atatürk Training and Research Hospital, Bilkent, Ankara - TURKEY

³ Department of Anesthesiology and Reanimation, Dışkapı Training and Research Hospital, Dışkapı, Ankara - TURKEY

⁴ Department of 3rd Orthopaedics and Traumatology Clinic, Dışkapı Training and Research Hospital, Dışkapı, Ankara - TURKEY

Correspondence: Metin DOĞAN, Department of 4th Orthopaedics and Traumatology, Atatürk Training and Research Hospital, 06800 Bilkent, Ankara - TURKEY

E-mail: mdoğanort@hotmail.com

Introduction

The principles of developmental dysplasia treatment of the hip (DDH) in childhood differ from those pertaining to infants (1-6). The goals of the treatment are to achieve and maintain a concentric reduction. When the diagnosis is delayed, the treatment of DDH to gain a concentric reduction gets difficult. Muscle contractures around the joint and soft tissue pathology hinder the reduction, and prevent the normal development of the head of the femur by inflicting pressure. In spite of the attempts to reduce the ischemic changes through various traction methods, there is no definite evidence to support this treatment modality (2,4-6).

Some studies claim that femoral shortening can facilitate reduction and reduce the risk of osteonecrosis (2,3,7,8). Some authors have claimed that besides open reduction, a one-stage operation must sometimes also include capsulorrhaphy, femoral shortening, and pelvic osteotomies in cases requiring these types of treatments (8-10). Various pelvic osteotomies were described for the treatment of residual acetabular dysplasia. Of them, the most widely known are the Salter and the Pemberton osteotomies.

Furthermore Dega or shelf procedures were developed to overcome some surgical problems. The main principle of these osteotomies is to redirect the true acetabulum in order to obtain the femoral head coverage. So we can prevent secondary coxarthrosis. This study was aimed to evaluate extraarticular grafting acetabuloplasty alone and combined Dega and extraarticular grafting at neglected DDH cases.

Materials and methods

Between 1998 and 2003, 41 hips in 34 children (24 girls and 10 boys) with neglected dislocation of the hip were treated at 2 different clinics and they were evaluated as Groups 1 and 2. Group 1 consists of 21 hips (n=18) and Group 2, 20 hips (n=16). The mean age at the time of operation was 8 years in Group 1 (5-10 years) and 7 years in Group 2 (5-10 years). All the patients were limping and had a positive Trendelenburg sign. Only 8 of patients had hip pain. All the patients were subjected to open reduction and capsulorrhaphy under general anesthesia in supine

position using combined Smith Petersen and proximal longitudinal femoral approaches in 12 patients and the Watson-Jones approach in 26 patients. In all the patients, following intertrochanteric osteotomy, femoral shortening and derotation were performed by adding varization in 38 hips that required it. Taking the state of the acetabulum and the height of the femur into consideration, either Dega osteotomy with extraarticular grafting (Group 2) (Figure 1) or only extra-articular grafting acetabuloplasty (EAGA) (Group 1) (Figure 2A and 2B) was performed to maintain an acetabular roof. None of the patients had experienced preoperative traction before our treatment (Table 1). Because of suspected instability, the femoral head was fixed to the acetabulum with a pin in 5 patients after partial capsule resection and plication. For all the patients, a hip spica cast was

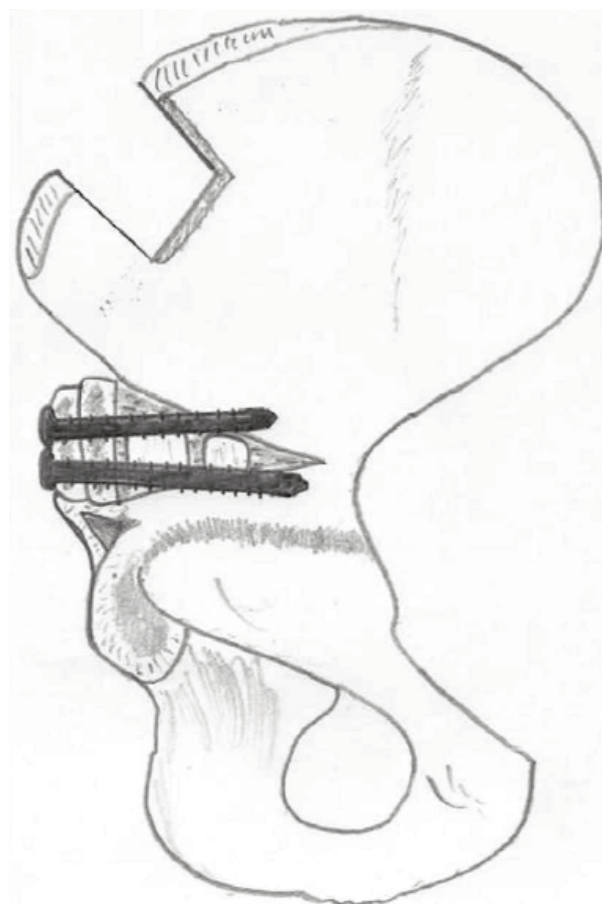


Figure 1. The illustration of Dega osteotomy with extraarticular grafting.

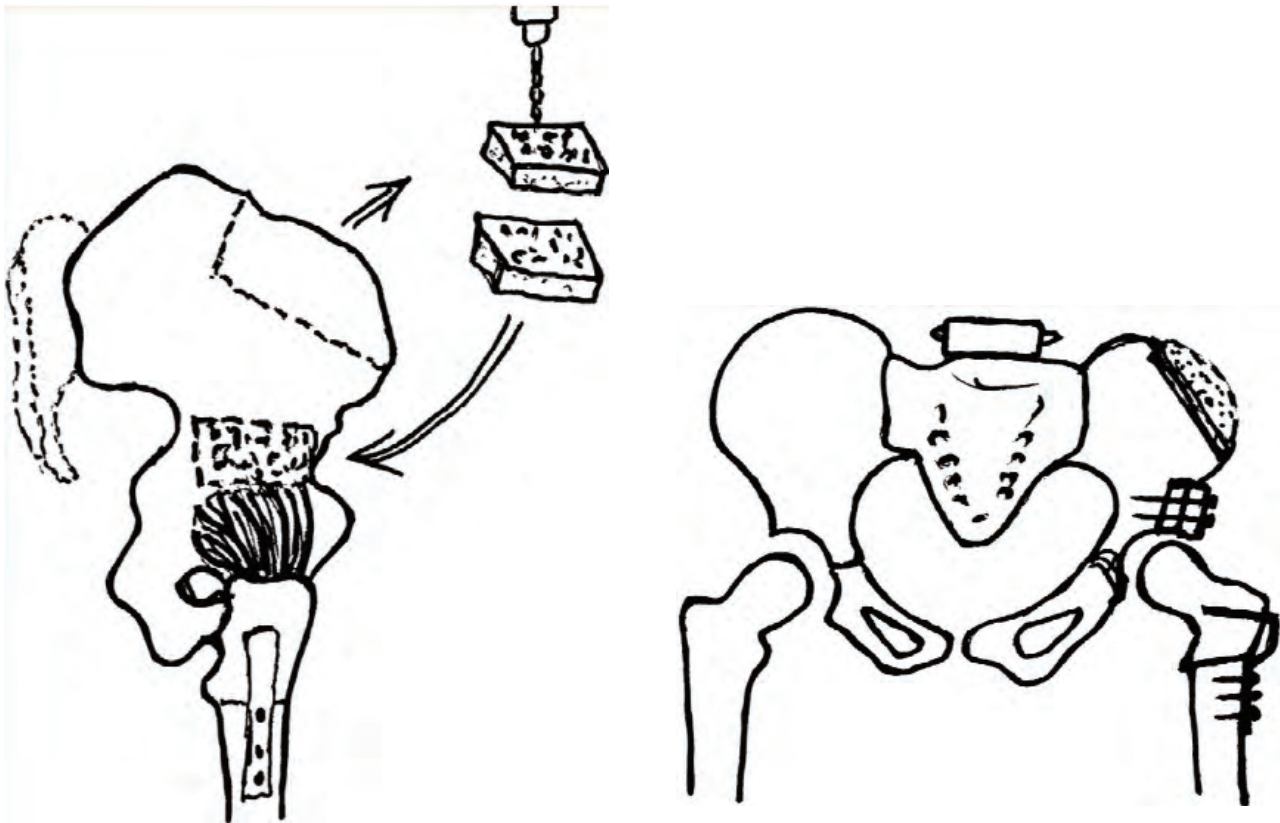


Figure 2. A. The illustration of extraarticular grafting. The graft is taken from the iliac crest and divided into 2 pieces, B. Osteosynthesis of the graft into the false acetabulum.

Table 1. Detailed information of the patient groups.

	Group 1	Group 2
Mean age	8 years	7 years
Bilateral case number	3	4
Unilateral case number	15	12
VDO application (hip)	17	18
Main osteotomy technique	EAGA	EAGA+Dega

applied after the operation. In week 4 after surgery, the pin was removed. The casts, however, were not removed for an average of 8 weeks. Following the removal of the casts, active and passive motion was carried out for 6 weeks using an abduction brace to increase the strength of the muscles and the range of motion of the joints. At the end of this procedure, the patients were able to walk by controlled weight bearing. Postoperative radiological and clinical evaluation was performed through the Severin and Mc Kay classification systems. The acetabular index

and Wiberg's centre-edge (CE) angles were evaluated pre- and post-operatively.

The patients were evaluated functionally and radiographically in the postoperative 1st, 3rd, and 6th months, and at the end of the 1st year, depending on the osseous maturation. Preoperative radiographs were used to determine the degree of depletion of the femoral head with respect to Tönnis (15) criteria, position of the hip, the acetabular index, and the regularity of the Shenton line. Having at least 8 degrees of correction of the dysplastic acetabulum, or an acetabular index lower than 20 degrees on the last radiograph according to the criteria of Ryan et al (8) was considered a sufficient acetabular reconstruction.

Results

In the last follow-up, 30 of 34 patients were pain-free at rest, used no analgesics, and were able to walk without crutches. The mean range of motion (flexion,

abduction, internal rotation, and external rotation) in Group 1 and Group 2 was 105° and 100°; 30° and 35°; 35° and 35°; 35°, and 30°, respectively. Eleven of 34 patients had a positive Trendelenburg sign at the last follow-up. The mean limb length discrepancy was 1.2 (0–5.5) cm and only 4 patients had a difference of more than 2 cm. The skeletal maturation was determined by radiographic examination of the proximal femoral epiphysis and triradiate cartilage; 9 patients had skeletal maturation. The preoperative mean acetabular index was 51° (35–65) and 55° (40–60) in Groups 1 and 2, respectively; in the last follow-up it was 32° and 34° (15–50). Satisfactory reduction (Severin Class I) was achieved in 18 hips in Group 1

(Figure 3 B, A) and 10 hips in Group 2 (Figure 4 A,B) according to the follow-up radiography and they developed no osteonecrosis. The Shenton line was intact in 36 hips, and the mean CE angle of Wiberg was increased to 19° (15–26). In the Severin classification; 28 hips were Class I, 8 hips were class II, 1 hip was Class IV, and 4 hips were Class V. Of the 41 hips we evaluated, 5 patients had insufficient reduction and 4 hips developed osteonecrosis (Figure 5). The Mc Kay’s scores of the patients according to age distribution are summarized in Table 2. The surgical technique did not interfere with the clinical outcome but the age of the child was the main determinant. Postoperative measurements and

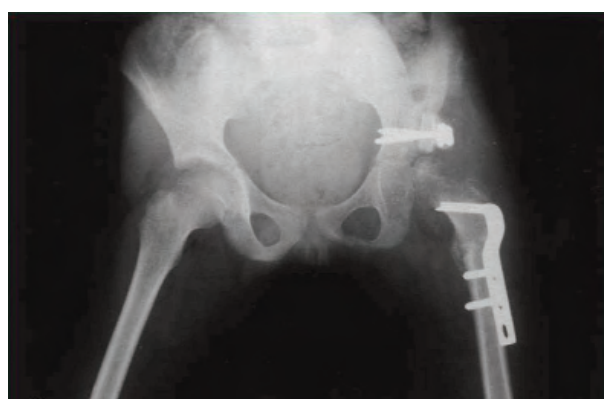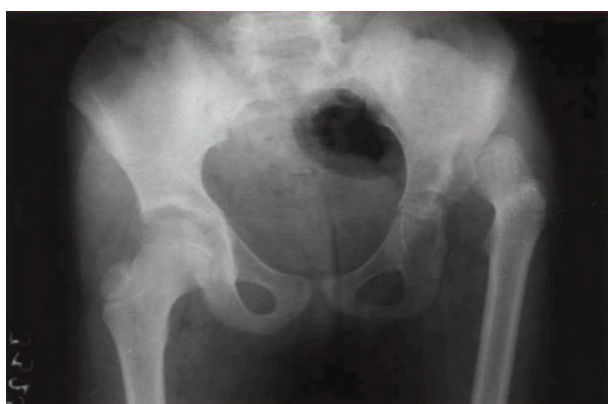


Figure 3. A. Preoperative anteroposterior pelvis X-ray of a 6 years old patient, B. Extraarticular grafting acetabuloplasty was applied and concentric reduction was achieved.

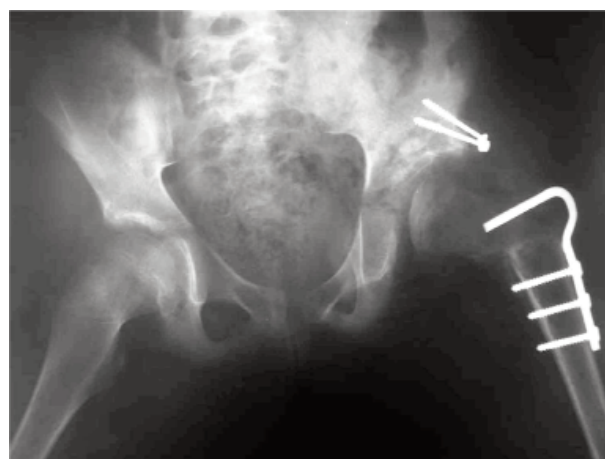
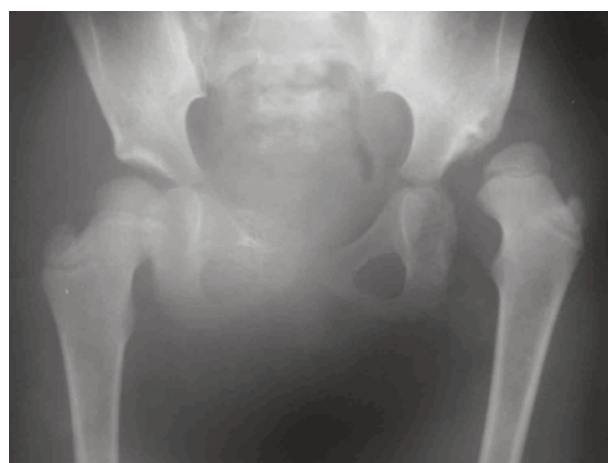

Figure 4. A. Preoperative anteroposterior pelvis X-ray of a 7-year-old patient, B. Successful reduction was achieved after the proximal femoral osteotomy, DEGA. Osteotomy, and extraarticular grafting (Postoperative 2nd year x-ray).

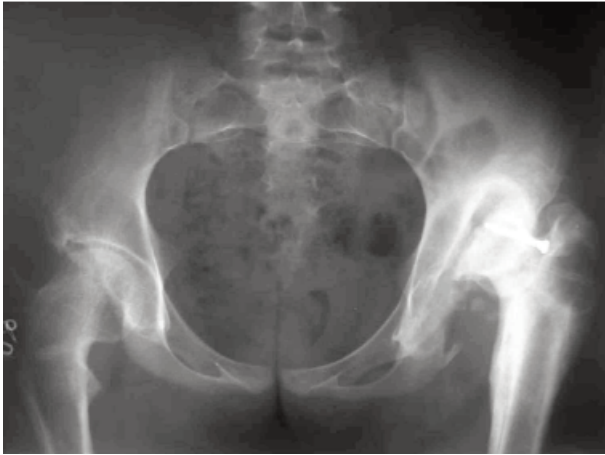


Figure 5. Postoperative x-ray of a 13-year-old patient. Complications of both redislocation and graft absorption can be seen

radiological evaluations of the hips are presented in Table 3. An open reduction on those hips was performed because of re-dislocation after the removal of the hip spica cast. In addition, 8 hips in which the desired outcomes were not obtained were manipulated under general anesthesia to overcome

the joint stiffness. After manipulation, the desired range of motions of the hips was achieved except in 5 patients. Additional complications were implant failure in 2 patients and heterotopic ossification in 2 hips. In addition, 8 patients had lateral rotational deformity because of excessive derotation.

Discussion

For both the older child and the infant, the aim of the treatment of congenital dislocation of the hip is focused on the reduction of the femoral head into the true acetabulum (4,6,9-14). Because of the risk of serious complications in the surgical treatment of older age DDH, open reduction and some acetabuloplasty techniques are contraindicated (4-5,15-17). The age group concerned is 6 and 14 years old. If the femoral head is flattened or the acetabulum is dysplastic, concentric reduction in older children may be a challenge. Soft tissue contracture, which obstructs the reduction, may increase some complications, such as improper reduction and avascular necrosis of the femoral head (6,11,13-14). The anatomy of older children with DDH

Table 2. Mc Kay's scores for post-operative clinical evaluation concerning the patient age.

Mc Kay's scores	5 years old (n = 4)	6 years old (n = 6)	7 years old (n = 7)	8 years old (n = 8)	9 years old (n = 4)	10 years old (n = 5)
Excellent	3	3	5	4		
Good		2	2			1
Fair	1			2	3	1
Poor		1		2	1	3

Table 3. Post-operative radiological outcomes of the patients.

	Group 1 (n = 18)		Group 2 (n = 16)	
	Unilateral (n = 15)	Bilateral (n = 3)	Unilateral (n = 12)	Bilateral (n = 4)
Mean CE Angle	18°	26°	24°	25°
Severin's criteria				
Class I	14	2	6	2
Class II	-	1	4	1
Class IV	-	-	1	-
Class V	1	-	1	1

* having at least 8 degrees of correction of the dysplastic acetabulum, or an acetabular index lower than 20 degrees on the last radiograph according to Ryan et al.

substantially varies in the degree of acetabular anteversion and it was not possible to remodel their bones. Because of dysplasia, anatomic changes occur in the pelvic bones. The shapes of the pelvis differs in uni- and bi-lateral DDH patients. In addition, because of secondary changes in the soft tissue and bone, the treatment may be more complex or have a protracted course. Thus, the outcome may be affected by age and laterality and is important in treatment planning (14). Although there were fewer patients in our study with bilateral involvement than those with unilateral involvement, they were more challenging as to the treatment and treatment results. In this retrospective study, 2 small groups of children in older ages were analyzed and no clinical or radiological differences were detected between the 2 groups when the age was not taken into consideration after simultaneous open reduction and extraarticular grafting with or without Dega osteotomy, including femoral shortening, derotation, and varization osteotomies. However, our radiological and clinical results in both groups were definitely better in children who were under 7 years of age. Dega's incomplete transiliac osteotomy can both reorient and reshape the acetabulum especially in young children with a wide-open triradiate cartilage. Although hinging occurs at the sciatic notch and the triradiate cartilage in the younger child, hinging probably occurs at the sciatic notch and the symphysis pubis as the child gets closer to skeletal maturity. Reorientation of the acetabulum is considered to be significant when there is a change in the obturator foramen, the acetabular index, and the center-edge angle. In the light of the relevant literature, we believe that Dega's osteotomy can be performed through either an open or a closed triradiate cartilage. Dega's osteotomy must be accompanied with open reduction and an appropriate correction of the proximal femoral deformity to gain a satisfactory result (2,4-5,8,12,14). The extraarticular grafting, termed as Shelf arthroplasty is a simpler method than Dega osteotomy, which forms an acetabular roof by placing the iliac wing graft over the hip capsule (1,12,16). Although a stable fixation can be achieved with 2 or more screws, resorption is common. In the current study we observed resorption in 13 hips independent from either the surgical technique or bilaterality. Nevertheless, all of these hips were those of the children with older age.

Dogan et al.(12) achieved good results by performing various surgical techniques for neglected cases of DDH after concentric reduction. They concluded that, as in our study, the age of the patient is the main determinant for the successful clinical outcome for advanced age DDH. We have used some of the preliminary results of this study.

The long-term functional and radiographic outcomes of one-stage open reduction of DDH have been widely studied in the literature (1,8,12,16). Most authors achieved good or excellent results by combined operative reduction in young children. Ryan et al. (8) reported good or excellent results in 16 of 18 children between 3 and 14 years of age after one-stage reduction. On the other hand, because of the insufficient remodeling capacity of the acetabulum some authors obtained increasingly poor results in children above 4 years of age who had undergone pelvic osteotomies. In our 2 different case groups with an age range of 3–14 years, we performed either Dega's osteotomy and extraarticular grafting or only extra-articular grafting acetabuloplasty.

The type of surgery was based on the preoperative evaluations of the pathologies as well as on our peroperative observations. We achieved good results after concentric reduction in both groups. However, the older age seemed to have a significant effect on the prognosis for the patients in whom concentric reduction was neither achieved nor sustained. While the patients under 7 years of age with previously insufficient reductions had good radiographic results, some of the patients 7 years old or older presented poor results, and thus required reoperation. Therefore, it can be concluded that in patients 7 years old or younger with a late diagnosis of developmental hip dislocation, the 2 techniques described here are feasible and safe. Despite the reports of Massie and Howorth (5) and Williamson et al. (10), who claimed that the age of the patient does not have any effect on the results, we report contrary results with 2 different acetabuloplasty techniques in our patients in respect to DDH treated at an older age.

Increased femoral shortening reduced the risk of osteonecrosis as well as facilitating better reduction among the patients (2,7-8,10-14). Thus, increased femoral shortening proved to be a superior method. Furthermore, preoperative traction did not increase

the risk of osteonecrosis as reported in the literature (1,6-7,14,18). In patients with severely dysplastic acetabulum whose diagnosis had been established through preoperative radiographic studies, we performed shelf arthroplasty through extraarticular grafting to increase the degree of reduction via increased acetabular volume (16). However, apart from the failure in providing total concentric reduction and stability in these patients, the external rotation deformity in gait due to over-derotation was another problem (4-5,8,16). There are 2 major

advantages of operative treatment of DDH in the periadolescent period. The surgical treatment restores hip anatomy and thus increases the probability of a successful hip replacement operation in adult life. Moreover, until the adult life, it provides a mobile and pain free hip for these patients (1-2,4-5,8,16,19).

Femoral osteotomy or any combination involving shortening, varus osteotomy, or derotation osteotomy combined with open reduction, capsulorrhaphy, and extraarticular grafting acetabuloplasty with or without pelvic osteotomy can be performed safely in one stage.

References

- Berkeley ME, Dickson JH, Cain TE, Donovan MM. Surgical therapy for congenital dislocation of the hip in patients who are twelve to thirty-six months old. *J Bone Joint Surg Am.* 1984 Mar; 66(3): 412-20.
- Dimitriou JK, Cavadias AX. One-stage surgical procedure for congenital dislocation of the hip in older children. *Clin Orthop* 1989 Sep; (246): 30-8.
- Karakas ES, Baktir A, Argun M, Turk CY. One stage treatment of congenital dislocation of the hip in older children. *J Pediatr Orthop* 1995 May-Jun; 15(3): 330-6.
- MacEwen GD. Treatment of congenital dislocation of the hip in older children. *Clin Orthop* 1987 Dec; (225): 86-92.
- Massie WK, Howorth MB. Congenital dislocation of the hip. Part II. Results of open reduction as seen in early adult period. *J Bone Joint Surg (Am)* 1951; 33: 171-90.
- Severin E. Congenital dislocation of the hip: development of the joint after closed reduction. *J Bone Joint Surg (Am)* 1950; 32-A: 507-18.
- Tükenmez M, Perçin S, Tezeren G, Cingöz MA, The outcomes of salter innominate osteotomy in the treatment of developmental dysplasia of the hip. *Turkiye Klinikleri J Med Sci* 2006; 26(4): 390-95.
- Ryan MG, Johnson LO, Quanbeck DS, Minkowitz B. Onestage treatment of congenital dislocation of the hip in children three to ten years old. Functional and radiographic results. *J Bone Joint Surg (Am)* 1998; 80: 336-44.
- Boyer DW, Mickelson MR, Ponseti IV. Slipped capital femoral epiphysis. Long-term follow-up study of one hundred and twenty-one patients. *J Bone Joint Surg (Am)* 1981; 63: 85-95.
- Williamson DM, Glover SD, Benson MK. Congenital dislocation of the hip presenting after the age of three years. A long-term review. *J Bone Joint Surg (Br)* 1989; 71: 745-51.
- Barrett WP, Staheli LT, Chew DE. The effectiveness of the Salter innominate osteotomy in the treatment of congenital dislocation of the hip. *J Bone Joint Surg (Am)* 1986; 68-A: 79-87.
- Dogan M, Bozkurt M, Sesen H, Yildirim H. One stage treatment of congenital severely dislocated hips in older children through various acetabuloplasty techniques: 22 children followed for 1-5 years. *Acta Orthop* 2005; Apr; 76(2): 212-9.
- Kalamchi A, MacEwen GD. Avascular necrosis following treatment of congenital dislocation of the hip. *J Bone Joint Surg (Am)* 1980; 62: 876-88.
- Kinik H, Mergen E, Radical reduction for developmental dislocation of the hip (Çakırgil's procedure). *Acta Orthop Traumatol Turc* 2007; 41, Suppl 1; 47-53.
- Tönnis D. Normal values of the hip joint for the evaluation of x-rays in children and adults. *Clin Orthop* 1976 Sep; (119): 39-47.
- Wiberg G. Shelf operation in congenital dysplasia of the acetabulum and in subluxation and dislocation of the hip. *J Bone Joint Surg (Am)* 1953; 35-A: 65-80.
- Tomak Y, Dabak N, Tilki K, Gülman B, Karaismailoğlu TN, The complications of open reduction and salter innominate osteotomy in the treatment of developmental dislocation of the hip. *Joint Diseases and Related Surgery* 2000; 11(2): 162-168
- Galpin RD, Roach JW, Wenger DR, Herring JA, Birch JG. One-stage treatment of congenital dislocation of the hip in older children, including femoral shortening. *J Bone Joint Surg (Am)* 1989; 71: 734-41.
- Subasi M, Arslan H, Cebesoy O, Buyukbebeci O, Kapukaya A. Outcome unilateral or bilateral DDH treated with one-stage combined procedure. *Clin Orthop* 2008 Apr; 466(4): 830-6.