

1-1-2010

The effects of adding methylprednisolone to low-potassium dextran solution on preserved ischemic lungs

ALİ YEGİNSU

MAKBULE ERGİN

HÜSEYİN ÖZYURT

ÇİĞDEM ELMAS

GÜLESER ÇAĞLAR GÖKTAŞ

Follow this and additional works at: <https://journals.tubitak.gov.tr/medical>



Part of the [Medical Sciences Commons](#)

Recommended Citation

YEGİNSU, ALİ; ERGİN, MAKBULE; ÖZYURT, HÜSEYİN; ELMAS, ÇİĞDEM; and GÖKTAŞ, GÜLESER ÇAĞLAR (2010) "The effects of adding methylprednisolone to low-potassium dextran solution on preserved ischemic lungs," *Turkish Journal of Medical Sciences*: Vol. 40: No. 1, Article 6. <https://doi.org/10.3906/sag-0812-5>

Available at: <https://journals.tubitak.gov.tr/medical/vol40/iss1/6>

This Article is brought to you for free and open access by TÜBİTAK Academic Journals. It has been accepted for inclusion in Turkish Journal of Medical Sciences by an authorized editor of TÜBİTAK Academic Journals. For more information, please contact academic.publications@tubitak.gov.tr.

The effects of adding methylprednisolone to low-potassium dextran solution on preserved ischemic lungs

Ali YEGİNSU¹, Makbule ERGİN¹, Hüseyin ÖZYURT², Çiğdem ELMAS³, Güleser ÇAĞLAR GÖKTAŞ³

Aim: To investigate the effects of adding methylprednisolone to low-potassium dextran solution on cold-preserved ischemic lungs.

Materials and methods: The study included 42 rat lung blocks that were divided into 7 groups (n = 6). Lung blocks were preserved in 40 mL of cold Perfadex solution, to which 5, 15, 30, 60, and 120 mg kg⁻¹ (approximately 40, 120, 240, 480, and 960 mg L⁻¹) of methylprednisolone were added. After a 24-h preservation period, the lungs were removed from the solution and examined.

Results: As compared to the Perfadex only group, cell death and degeneration were significantly higher in the Perfadex + methylprednisolone groups (P < 0.05). MDA and IL-8 levels were higher in all Perfadex + methylprednisolone groups. Statistically significant differences were observed between some of these groups. Antioxidant enzyme activity was generally higher in the Perfadex + methylprednisolone groups than in the Perfadex only group (P < 0.05).

Conclusion: Adding methylprednisolone to low-potassium dextran solution does not have any beneficial effects but has possible deleterious effects in rat lung preservation.

Key words: Lung transplantation, organ preservation, Perfadex, methylprednisolone, rat

Düşük potasyumlu dekstran solusyonuna metilprednizolon ilavesinin iskemik akciğer koruma üzerine etkileri

Amaç: Bu çalışmanın amacı düşük potasyumlu dekstran solusyonuna metilprednizolon ilavesinin iskemik akciğer koruma üzerine etkilerini araştırmaktır.

Yöntem ve gereç: Kırk iki verici sıçan akciğer bloğu 7 gruba bölündü (n = 6). Akciğer blokları 40 mL 5, 15, 30, 60 ve 120 mg kg⁻¹ (yaklaşık 40, 120, 240, 480 ve 960 mg L⁻¹) soğuk Perfadex solusyonu içerisinde korundu. Yirmi dört saatlik koruma süresi sonrasında akciğerler solusyondan çıkarıldı ve tetkikler için saklandı.

Bulgular: Metilprednizolon eklenmiş Perfadex grubunda hücre ölümü ve dejenerasyon Perfadex grubuna kıyasla anlamlı olarak daha fazlaydı (P < 0,05). MDA ve İL-8 düzeyleri metilprednizolon eklenen tüm gruplarda daha yüksekti. Bu grupların bazılarında istatistiksel anlamlılık vardı. Antioksidan enzim aktiviteleri metilprednizolon eklenmiş Perfadex gruplarında Perfadex gruplarına kıyasla genel olarak daha yüksekti (P < 0,05).

Sonuç: Düşük potasyumlu dekstran solusyonuna eklenen metilprednizolonun sıçanlarda akciğer korumada yararlı bir etkisi olmamakla birlikte, muhtemel zararlı etkileri mevcuttur.

Anahtar sözcükler: Akciğer nakli, organ koruma, perfadex, metilprednizolon, sıçan

Received: 01.12.2008 – Accepted: 09.09.2009

¹ Department of Thoracic Surgery, Faculty of Medicine, Gaziosmanpaşa University, Tokat - TURKEY

² Department of Biochemistry, Faculty of Medicine, Gaziosmanpaşa University, Tokat - TURKEY

³ Department of Histology and Embryology, Faculty of Medicine, Gazi University Ankara - TURKEY

Correspondence: Ali YEGİNSU, Department of Thoracic Surgery, Faculty of Medicine, Gaziosmanpaşa University, Tokat - TURKEY

E-mail: yeginsu@hotmail.com

Introduction

To date, lung transplantation remains the best therapeutic option for end-stage lung disease. One of the main determinants in obtaining successful lung transplantation results is optimal preservation of the donor lung and use of the optimal preservation solution. Low-potassium dextran solution (Perfadex) has been commonly used in lung transplantation at many institutions, and the superiority of Perfadex to other preservation solutions used in lung transplantation has been reported (1).

In clinical application some additives have been used together with organ preservation solutions, such as steroids (2), prostaglandin E1 (3), raffinose (4), and pH-regulating drugs (5), for improving the preservative effect. Glucocorticoids are one of the most potent anti-inflammatory agents known to clinical medicine. Pharmacologic doses of glucocorticoids dramatically inhibit exudation of plasma and accumulation of leukocytes at sites of inflammation. They antagonize macrophage differentiation, inhibit neutrophil adhesion to endothelial cells, decrease circulating eosinophil and basophil counts, and decrease the accumulation of eosinophils and mast cells at sites of allergic reactions. They have profound effects on the activation and subsequent function of endothelial cells, and clearly inhibit vascular permeability (6).

The purpose of the present study was to investigate the dose-dependent effects of methylprednisolone (MP) added to Perfadex solution on lung preservation.

Materials and methods

Animals

The study included 42 male Wistar rats weighing 280-320 g. This study was approved by the local ethics committee and was funded by the scientific research board of our university. All animals received humane care in compliance with the "Guide for the Care and Use of Laboratory Animals," prepared by the Institute of Laboratory Animal Resources (7).

Agents

Perfadex solution (Vitrolife, Sweden), for experimental use only, was obtained from Vitrolife and methylprednisolone (Prednol-L, Mustafa Nevzat, Türkiye) was commercially obtained.

Surgical procedure

The rats were divided into 7 groups ($n = 6$). After anesthesia with 30 mg kg^{-1} of IV thiopentone (pental sodium, IE Ulagay, İstanbul, Turkey), the rats were intubated via tracheostomy and connected to a rodent ventilator (Harvard Inspira ASVV, MA, USA). Animals were ventilated with room air, 4-cm H₂O positive end-expiratory pressure, and at 60 breaths min^{-1} . Heparin 50 IU was given through the penile vein and 5 min later laparo-sternotomy was performed. The inferior vena cava, and right and left atrial appendages were cut. The lungs were flushed with 20 mL of 1-4 °C Perfadex or Perfadex + MP solutions through the pulmonary artery with a pressure of 20-cm H₂O. In controls, lungs were removed immediately after flushing with isotonic saline. In the Perfadex + MP groups, 5, 15, 30, 60, and 120 mg kg^{-1} (approximately 40, 120, 240, 480, and 960 mg L^{-1} , respectively) of MP were added to Perfadex solution. After flushing, the trachea was tied and the lungs were inflated. The lung-heart block was removed and immersed in 40 mL of Perfadex or Perfadex + MP solutions at 1-4 °C. After a 24-h preservation period the lung blocks were removed from the solutions. Left lungs were used for the determination of cell death; the right upper lobes were kept in 10% formalin solution for morphometric studies and the remaining lobes were kept at -80 °C for biochemical studies.

Histological assessment of cell death

Lungs were flushed for 5 min with 20 mL of 500 mmol L^{-1} Trypan blue (Sigma Chemical) solution through the main pulmonary artery. This flush was followed by 20 mL of 0.9% normal saline solution. Trypan blue was dissolved in Krebs-Henseleit buffer (pH 7.4; Sigma Chemical). The lungs were then fixed in 10% formalin. The middle third of each left lung was used for histological examination, as it is representative of the peripheral and central

parenchymal areas. An eosin counterstain was used to identify all viable cells, which do not pick up Trypan blue as dead cells do because they lose their ability to exclude the dye actively. Cells were counted from 10 randomly chosen fields per slide. All viable cells were counted first, followed by all Trypan blue-stained cells. Results for dead cells are expressed as a percentage of total cells.

Morphometric study

All tissues were transferred immediately to 10% formalin for 72 h, dehydrated in graded alcohols, and embedded in paraffin wax. Sections 4- μ m thick were cut on a microtome (Leica SM 2000, Germany). Afterwards, the slides were counterstained with hematoxylin-eosin. All slides were evaluated using a Leica photomicroscope and camera (DM 4000 B, and DFC280 Plus Camera, Leica, Weetlar, Germany). Ten histopathologic evaluations per field were made, and 10 fields in each section were analyzed. Infiltration, terminal bronchial wall damage and debris, respiratory bronchial wall damage and debris, and alveolar degeneration were evaluated. Each was graded as follows: 1: absent; 2: mild; 3: moderate; 4: severe. Mean scores were recorded for each rat.

Preparation of lung tissue homogenate

Lung tissue was stored at -80°C until analyzed. After weighing the lung tissues, homogenization in 5 volumes of ice-cold tris-HCl buffer (50 mM, pH 7.4) containing 0.50 mL L⁻¹ of Triton X-100 was performed for 2 min at 13,000 rpm (homogenizer: IKA Ultra-Turrax T 25 Basic, Germany). All procedures were performed at 4°C . The homogenate, supernatant, and extracted samples were prepared, and then the samples were analyzed using commercial chemicals supplied by Sigma (St Louis, MO, USA). Protein measurements of the samples were taken as described by Lowry et al. (8).

Biochemical analysis

Determination of interleukin-8 level, antioxidant enzyme activity, and lipid peroxidation

IL-8 levels were measured using the enzyme-linked immunosorbent assay (ELISA). IL-8 levels are

expressed as pg mL⁻¹. Total (Cu-Zn and Mn) SOD (EC 1.15.1.1) activity was determined according to the method of Sun et al. (9). SOD activity is expressed as U mg⁻¹ of protein. Glutathione peroxidase (GPX) activity was measured according to Paglia and Valentine (10) and is expressed as U g⁻¹ of protein.

The malondialdehyde (MDA) level, which indicates lipid peroxidation, was determined using a method based on reaction with thiobarbituric acid (TBA) at $90-100^{\circ}\text{C}$ (11). Results are expressed as nmol g⁻¹ of wet tissue, according to the standard graphic prepared from measurements with a standard solution (1,1,3,3-tetramethoxypropane).

Statistics

SPSS v.15.0 was used for statistical evaluation. Data are expressed as mean \pm SD. The Kruskal-Wallis test was used for comparisons between the groups. Post hoc multiple comparisons were calculated with the Mann-Whitney U test. P values < 0.05 were considered significant.

Results

The Perfadex and Perfadex + MP groups had more inflammation and cell damage than the control group. In the Perfadex + MP groups the percentage of cell death and severity of degeneration were significantly higher than in the Perfadex only group. IL-8 levels were higher in all the Perfadex + MP groups than in the Perfadex only group, and statistically significant differences were observed between the Perfadex only group, and the MP15, MP30, and MP60 groups. MDA levels were also higher in the Perfadex + MP groups than in the Perfadex only group, and the difference between the MP120 group and the Perfadex only group was significant ($P < 0.05$). SOD activity was lower in the MP5 and MP15 groups than in the Perfadex only group; however, the differences were not significant. The MP30 and MP120 groups had significantly higher SOD activity than the Perfadex only group. The difference in GPX activity between the groups was not statistically significant. The results of the statistical analysis of the groups are shown in Tables 1 and 2.

Table 1. Evaluation of the study data. The Kruskal-Wallis test was used to compare the groups.

Parameter	Control	Perfa-dex	MP5	MP15	MP30	MP60	MP120	P
Cell death (%)	2.4 ± 0.5	33 ± 5	45 ± 5	46 ± 4	42 ± 5	41 ± 2	48 ± 3	<0.001*
Degeneration	1.1 ± 0.4	1.3 ± 0.5	2.5 ± 0.5	3.5 ± 0.5	3.3 ± 0.1	2.5 ± 0.8	2.6 ± 0.5	<0.001*
IL-8	49 ± 19	63 ± 20	76 ± 14	98 ± 19	100 ± 23	93 ± 16	81 ± 31	0.002*
MDA	1.62 ± 0.1	1.76 ± 0.3	2.38 ± 0.5	2.06 ± 0.1	2.04 ± 0.2	2.10 ± 0.6	2.47 ± 0.3	0.041*
SOD	50.3 ± 9	77.6 ± 9	73.2 ± 15	63.0 ± 15	136.84 ± 14	138.0 ± 15	90.2 ± 14	<0.001*
GPX	16.3 ± 1.8	23.0 6.6	23.8 ± 5.9	23.1 ± 8.8	23.1 ± 4.9	19.3 ± 2.7	23.6 ± 7.0	0.034*

*Statistically significant.

IL-8: Interleukin-8 (pg mL⁻¹); MDA: malondialdehyde (nmol g⁻¹ of wet tissue); SOD: superoxide dismutase (U g⁻¹ of protein); GPX: glutathione peroxidase (U g⁻¹ of protein).

Table 2. Multiple comparisons of the groups (P values).

Groups	Cell Death	Degeneration	IL-8	MDA	SOD	GPX
Control-Perfadex	<0.001*	0.699	0.093	0.589	0.002*	0.132
Control-MP5	<0.001*	0.004*	0.026*	0.015*	0.004*	0.002*
Control-MP15	<0.001*	0.002*	0.004*	0.004*	0.009*	0.180
Control-MP30	<0.001*	0.026*	0.009*	0.015*	0.002*	0.015*
Control-MP60	<0.001*	0.026*	0.009*	0.093	0.002*	0.065
Control-MP120	<0.001*	0.004*	0.041*	0.004*	0.002*	0.065
Perfadex-MP5	<0.001*	0.015*	0.394	0.065	0.589	0.320
Perfadex-MP15	<0.001*	0.002*	0.026*	0.180	0.394	0.937
Perfadex-MP30	0.001*	0.004*	0.026*	0.180	0.002*	0.937
Perfadex-MP60	<0.001*	0.041*	0.026*	0.310	0.002*	0.394
Perfadex-MP120	<0.001*	0.009*	0.394	0.015*	0.589	1.000
MP5-MP15	0.796	0.026*	0.041*	0.240	0.937	0.485
MP5-MP30	0.123	0.180	0.065	0.394	0.002*	0.180
MP5-MP60	0.019*	0.818	0.093	0.699	0.002*	0.015*
MP5-MP120	0.218	0.699	0.818	0.699	0.394	0.699
MP15-MP30	0.063	0.699	0.818	0.932	0.002*	0.937
MP15-MP60	0.009*	0.065	0.818	0.818	0.002*	0.394
MP15-MP120	0.315	0.065	0.310	0.065	0.310	0.937
MP30-MP60	0.971	0.240	0.310	0.699	0.937	0.132
MP30-MP120	0.015*	0.310	0.310	0.041*	0.041*	0.699
MP60-MP120	0.001*	0.937	0.394	0.240	0.026*	0.093

*Statistically significant.

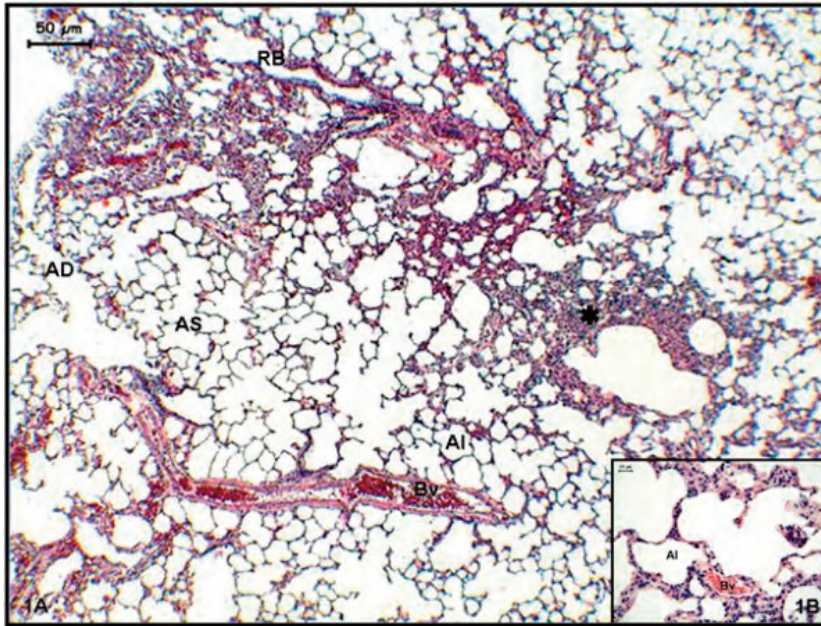


Figure 1. Perfadex group. Increased lymphocyte infiltration (β) was seen in the lung tissue (AS). Regional alveolar ductal (AD) and respiratory bronchiolar (RB) widening were noted (hematoxylin-eosin: 1A, 100 \times and 1B, 400 \times). Bv: blood vessels, Al: alveolus, AS alveolar space.

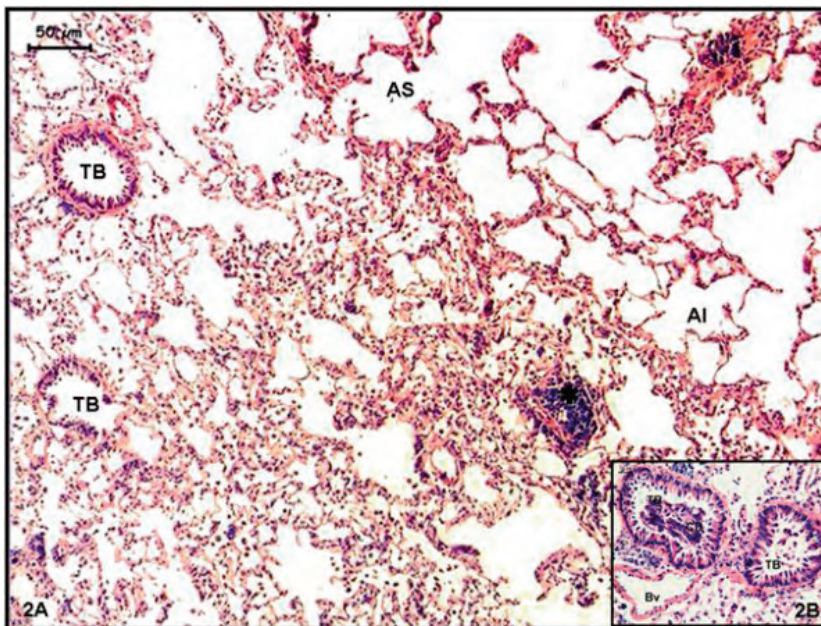


Figure 2. MP-5 group. General structure of the lung tissue, predominantly alveoli (Al), was degenerated. Terminal bronchiolar (TB) wall degeneration with infiltrative cells and epithelial debris was seen. Alveoli were fused and composed very large forms, and interalveolar connective tissue increased (hematoxylin-eosin: 2A, 100 \times and 2B, 400 \times).

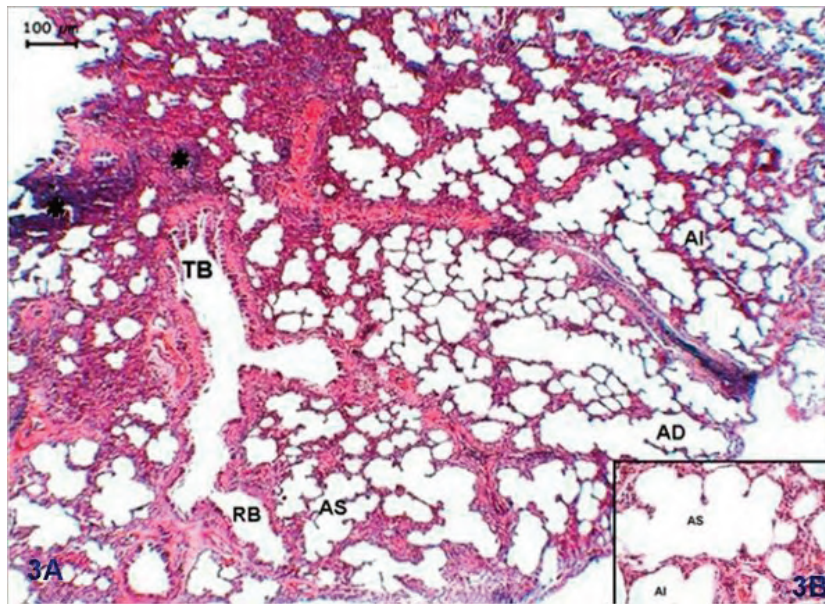


Figure 3. MP-120 group. Obvious lymphocyte infiltration (B) and an increase in connective tissue were noted, in general. Terminal bronchial (TB) disarrangement and degeneration were present. Epithelial debris was seen in the bronchiolar lumen. Alveolar (Al) wall was thickened site-by-site, and cells were irregular. Macrophagic infiltration increased in the alveoli (hematoxylin-eosin: 3A, 40× and 3B, 400×).

Discussion

The present study shows that MP added to lung preservation solution had some harmful effects on lung tissue, such as increasing cell death and degeneration, lipid peroxidation, IL-8 release, and oxidative stress. To the best of our knowledge the literature does not contain any reports that confirm the present study's results. In contrast to the present study, those that used lazareid U74500A, a type of steroid-inhibiting lipid peroxidation, reported that its addition enhanced the preservative effect of University of Wisconsin solution (UWS) in pulmonary grafts (12). It also protected lung grafts from ischemia-reperfusion injury (13) and improved endothelial cell viability (14). Hisatomi et al. (15) added 50, 100, 150, and 200 mg L⁻¹ of MP to Euro-Collins solution in a myocardial preservation study. Their results show that the addition of the steroid to the preservation solution might have been effective in preventing myocardial injury during preservation of rat hearts, and the optimal concentration appeared to range from 150

to 200 mg L⁻¹. Although it was not a lung preservation study, its similarity to our study may be of importance.

While systemic addition of MP to donor lungs attenuated posttransplant graft function (16), our study shows that addition of MP had some harmful effects to donor lung tissue; however, it is not clear why it was harmful. The commercial form of MP used in the present study contained methylprednisolone sodium succinate, sodium phosphate, sodium chloride, lactose monohydrate, and distilled water; to the best of our knowledge, the literature does not contain any reports about the direct toxic effects of these chemicals on lung tissue.

It is known that the pH of preservation solution is important for cell viability (17). The pH of MP is about 7.20 and the addition of MP did not affect the pH of Perfadex solution (pH value is about 5.8). We measured the pH values of the Perfadex + MP solutions (range: 5.8 to 6.1) and do not consider the changes in pH values as the source of MP's harmful effects.

Cellular electrophysiological changes might be a cause of cell damage. As it is known, Na^+/K^+ -ATPase pump function decreases in hypothermia (18). Schramm et al. (19) reported that MP potentiated Na^+/K^+ ATPase pump activity in rabbit airway smooth muscle. As such, we can speculate that the cause of cell damage was that MP altered ionic stability and metabolic activity by potentiating Na^+/K^+ -ATPase pump activity. We think additional studies are necessary to evaluate our results more fully.

Cell viability was reported as a predictive factor in posttransplant graft dysfunction (20). Transvascular Trypan blue flush is a valuable technique for the detection of dead cells in lungs. This technique has been commonly used for lung and other tissues in transplantation studies. Trypan blue staining easily identifies all necrotic and apoptotic dead cells with blue-stained nuclei. Fischer et al. (20) reported that, whereas less than 3% of graft cells died in the early period (first 12 h) of cold preservation, 27% of all cells died by the 24th h of preservation. Additionally, they reported that the percentage of necrotic cells was inversely correlated to posttransplant graft dysfunction. In the present study, the cell death rate was 33% in the Perfadex only group versus 41%-48% in the Perfadex + MP groups.

Fisher et al. (21) reported that IL-8 levels in donor lungs were associated with early graft failure after lung transplantation. Kaneda et al. (22) showed that increased m-RNA expression in multiple cytokines in donor lungs was associated with posttransplant mortality. They reported that IL-6, IL-8, TNF- α , and IL-1 β were risk factors for mortality, and that IL-10 and IFN- γ were protective factors.

Alveolar morphologic changes have been reported after lung preservation (23). Severe alveolar degeneration appeared after 24 h of storage. Degenerative findings, such as lamellar degeneration in type-II pneumocytes, type-I pneumocyte damage, cytoplasmic vacuolization, contraction of the endothelial lining of capillaries, vacuolization of endothelial cells, and pericapillary edema may be seen with light microscopy.

Antioxidant enzyme activity increased during ischemic lung preservation (24). Superoxide dismutase, which causes superoxide breakdown and the subsequent production of hydrogen peroxide, has a central role in the regulation of reactive oxygen species (ROS) levels (25). Vascular smooth muscle cells, pulmonary endothelial cells, and lung macrophages generate superoxide under basal and stimulated conditions (26). Glutathione peroxidase is a cytosolic enzyme that also eliminates H_2O_2 and includes a wide range of substrates (including lipid peroxides). The primary function of glutathione peroxidase is to detoxify low levels of H_2O_2 in cells (27,28). In the present study the addition of MP to preservation solution did not prevent an increase in antioxidant enzyme activity.

Oxygen radicals react with polyunsaturated fatty acid residues in phospholipids, and MDA is one of the final products of that reaction in cells. An increase in free radicals causes overproduction of MDA, the level of which is a marker for oxidative stress (11,24). In our previous study there was no statistically significant increase in the MDA level, although antioxidant enzyme activity increased. The present study shows that the addition of MP to preservation solution increased MDA levels.

The present study investigated the effects of MP on preserved lung tissue, but not its posttransplant effects, which is a limitation. We do not know how these results would affect the posttransplant condition. On the other hand, the findings in donor lungs mentioned above may be helpful in predicting transplantation outcomes; therefore, the present results might indirectly indicate the posttransplant course.

In conclusion, addition of MP to Perfadex solution did not provide additional preservative benefits during 24 h of cold preservation of ischemic rat lungs. In contrast, the use of MP was associated with some harmful effects on lung tissue, the mechanism of which remains unknown. Further studies are needed in order to collect more detailed data and for clarifying the clinical use of MP.

References

1. Rabanal JM, Ibañez AM, Mons R, Gonzalez AM, Carbajo M, Ortega J et al. Influence of preservation solution on early lung function (Euro-Collins vs. Perfadex). *Transplant Proc* 2003; 35: 1938-9.
2. Hall TS, Borkon AM, Gurtner GC, Brawn J, Hutchins GM, Reitz BA et al. Improved static lung preservation with corticosteroids and hypothermia. *J Heart Transplant* 1988; 7: 348-52.
3. de Perrot M, Fischer S, Liu M, Jin R, Bai XH, Waddell TK et al. Prostaglandin E1 protects lung transplants from ischemia-reperfusion injury: a shift from pro- to anti-inflammatory cytokines. *Transplantation* 2001; 72: 1505-12.
4. Fischer S, Hopkinson D, Liu M, MacLean AA, Edwards V, Cutz E et al. Raffinose improves 24-hour lung preservation in low potassium dextran glucose solution: a histologic and ultrastructural analysis. *Ann Thorac Surg* 2001; 71: 1140-5.
5. Hopkinson DN, Odom NJ, Bridgewater BJ, Hooper TL. Lung graft preservation. Comparison of phosphate-buffered sucrose, modified EuroCollins, and University of Wisconsin solutions. *Transplantation* 1994; 58: 763-8.
6. Boumpas DT, Chrousos GP, Wilder RL, Cupps TR, Balow JE. Glucocorticoid therapy for immune-mediated diseases: basic and clinical correlates. *Ann Intern Med*. 1993; 119: 1198-208.
7. Guide for the care and use of laboratory animals. 6th ed. Washington, DC: National Academy Press, 1996.
8. Lowry OH, Rosenbrough NJ, Farr AL, Randall RJ. Protein measurement with the Folin phenol reagent. *J Biol Chem* 1951; 193: 265-275.
9. Sun Y, Oberley LW, Ying L. A simple method for clinical assay of superoxide dismutase. *Clin Chem* 1988; 34: 497-500.
10. Paglia DE, Valentine WN. Studies on the quantitative and qualitative characterisation of erythrocyte glutathione peroxidase. *J Lab & Clin Med* 1967; 70: 158-169.
11. Esterbauer H, Cheeseman KH. Determination of aldehydic lipid peroxidation products: malonaldehyde and 4-hydroxynonenal. *Methods Enzymol* 1990; 186: 407-21.
12. Aeba R, Killinger WA, Keenan RJ, Yousem SA, Hamamoto I, Hardesty RL et al. Lazaroid U74500A as an additive to University of Wisconsin solution for pulmonary grafts in the rat transplant model. *J Thorac Cardiovasc Surg* 1992; 104: 1333-9.
13. Kuwaki K, Komatsu K, Sohma H, Abe T. The effect of various doses of lazardoid U74389G on lung ischemia reperfusion injury. *Thorac Cardiovasc Surg* 1999; 47: 67-72.
14. Killinger WA Jr, Dorofi DB, Keagy BA, Johnson G Jr. Improvement of endothelial cell viability at 4 degrees C by addition of lazardoid U74500A to preservation solutions. *Transplantation* 1992; 53: 983-6.
15. Hisatomi K, Isomura T, Sato T, Hayashida N, Kosuga K, Ohishi K. Beneficial effect of steroid on myocardial preservation in isolated rat hearts *Jpn Circ J* 1995; 59: 815-23.
16. Hall TS, Borkon AM, Gurtner GC, Brawn J, Hutchins GM, Reitz BA et al. Improved static lung preservation with corticosteroids and hypothermia. *J Heart Transplant* 1988; 7: 348-52.
17. Hiramatsu Y, Muraoka R, Chiba Y, Sasaki M. Influence of pH of preservation solution on lung viability. *Ann Thorac Surg* 1994; 58: 1083-6.
18. Martin DR, Scott DF, Downes GL, Belzer FO. Primary cause of unsuccessful liver and heart preservation: cold sensitivity of the ATPase system. *Ann Surg* 1972; 175: 111-7.
19. Schramm CM, Grunstein MM. Corticosteroid modulation of Na(+)-K+ pump-mediated relaxation in maturing airway smooth muscle. *Br J Pharmacol*. 1996; 119: 807-12.
20. Fischer S, Maclean AA, Liu M, Cardella JA, Slutsky AS, Suga M et al. Dynamic changes in apoptotic and necrotic cell death correlate with severity of ischemia-reperfusion injury in lung transplantation. *Am J Respir Crit Care Med* 2000; 162: 1932-9.
21. Fisher AJ, Donnelly SC, Hirani N, Haslett C, Strieter RM, Dark JH et al. Elevated levels of interleukin-8 in donor lungs is associated with early graft failure after lung transplantation. *Am J Respir Crit Care Med* 2001; 163: 259-65.
22. Kaneda H, Waddell TK, de Perrot M, Bai XH, Gutierrez C, Arenovich T et al. Pre-implantation multiple cytokine mRNA expression analysis of donor lung grafts predicts survival after lung transplantation in humans. *Am J Transplant* 2006; 6: 544-51.
23. Arbak S, Yalin A, Ercan F. Effects of preservation of rat lungs in a hypothermic medium on alveolar morphology. *Acta Histochem* 1999; 101: 341-9.
24. Yeginsu A, Ergin M. Antioxidant enzymes and lipid peroxidation in cold ischemic lung preservation experimental and clinical transplantation. 2009; 2: 94-8.
25. Pryor WA, Houk KN, Foote CS, Fukuto JM, Ignarro LJ, Squadrito GL et al. Free radical biology and medicine: it's a gas, man! *Am J Physiol Regul Integr Comp Physiol* 2006; 291: R491-R511.
26. Yang W, Block ER. Effect of hypoxia and reoxygenation on the formation and release of reactive oxygen species by porcine pulmonary artery endothelial cells. *J Cell Physiol* 1995; 164: 414-423.
27. Quinlan T, Spivack S, Mossman BT. Regulation of antioxidant enzymes in lung after oxidant injury. *Environ Health Perspect* 1994; 102 (suppl 2): 79-87.
28. Heffner JE, Repine JE. Pulmonary strategies of antioxidant defense. *Am Rev Respir Dis* 1989; 140: 531-554.