

1-1-2010

## Comparative efficacy of caffeic acid phenethyl ester (CAPE), olopatadine hydrochloride, and dexamethasone sodium phosphate in experimental allergic conjunctivitis\*

ERDİNÇ AYDIN

HELİN DENİZ DEMİR

HÜSEYİN ÖZYURT

ÜNAL ERKORKMAZ

Follow this and additional works at: <https://journals.tubitak.gov.tr/medical>



Part of the [Medical Sciences Commons](#)

---

### Recommended Citation

AYDIN, ERDİNÇ; DEMİR, HELİN DENİZ; ÖZYURT, HÜSEYİN; and ERKORKMAZ, ÜNAL (2010) "Comparative efficacy of caffeic acid phenethyl ester (CAPE), olopatadine hydrochloride, and dexamethasone sodium phosphate in experimental allergic conjunctivitis\*," *Turkish Journal of Medical Sciences*: Vol. 40: No. 4, Article 14. <https://doi.org/10.3906/sag-0805-20>

Available at: <https://journals.tubitak.gov.tr/medical/vol40/iss4/14>

This Article is brought to you for free and open access by TÜBİTAK Academic Journals. It has been accepted for inclusion in Turkish Journal of Medical Sciences by an authorized editor of TÜBİTAK Academic Journals. For more information, please contact [academic.publications@tubitak.gov.tr](mailto:academic.publications@tubitak.gov.tr).

## Comparative efficacy of caffeic acid phenethyl ester (CAPE), olopatadine hydrochloride, and dexamethasone sodium phosphate in experimental allergic conjunctivitis\*

Erdoğan AYDIN<sup>1</sup>, Helin DENİZ DEMİR<sup>1</sup>, Hüseyin ÖZYURT<sup>2</sup>, Ünal ERKORKMAZ<sup>3</sup>

**Aim:** To compare the antiallergic efficacy of 1% caffeic acid phenethyl ester (CAPE), 0.1% olopatadine hydrochloride, and 0.1% dexamethasone sodium phosphate.

**Materials and methods:** Experimental allergic conjunctivitis was provoked by a mast cell activator (compound 48/80) in 31 New Zealand rabbits. The rabbits were divided into 3 groups, and 1% CAPE, 0.1% olopatadine hydrochloride, and 0.1% dexamethasone sodium phosphate were instilled 30 min before and 15 min after the provocation. The edema and hyperemia in the experimental (right) eyes and control (left) eyes were scored in each group. Anterior segment photographs and conjunctival samples for histopathological evaluation and scoring were taken.

**Results:** When the edema and hyperemia scores of the postprovocation term were compared with those of the provocation term, a significant difference was detected in each group ( $P = 0.021$ ,  $P = 0.037$ ,  $P = 0.0001$ ). The histopathological scores of the provocation and postprovocation terms were evaluated; a statistically significant difference was found in the CAPE and dexamethasone sodium phosphate groups ( $P = 0.003$ ,  $P = 0.014$ ), but not in the olopatadine group ( $P = 0.096$ ).

**Conclusion:** This study demonstrated that 1% CAPE was as clinically efficacious as 0.1% olopatadine and 0.1% dexamethasone. Thus, 1% CAPE may be an alternative to 0.1% olopatadine and 0.1% dexamethasone in the management of acute allergic reactions.

**Key words:** Allergic conjunctivitis, caffeic acid phenethyl ester, dexamethasone sodium phosphate, olopatadine hydrochloride

### Deneysel alerjik konjonktivit modelinde kafeik asit fenilettil ester (CAPE), olopatadine hidroklorid ve deksametazon sodyum fosfat'ın etkinliklerinin karşılaştırılması

**Amaç:** % 1 kafeik asit fenilettil ester (CAPE), % 0,1 olopatadine hidroklorür ve % 0,1 deksametazon sodyum fosfat'ın anti-alerjik etkinliğinin karşılaştırılması.

**Yöntem ve gereç:** Deneysel alerjik konjonktivit üç gruba ayrılmış 31 Yeni Zelanda tipi tavşanlarda bir mast hücre aktivatörü olan 48/80 bileşik ile oluşturuldu. % 1 CAPE, % 0,1 olopatadine hidroklorür ve % 0,1 deksametazon sodyum fosfat provokasyondan 30 dakika önce, provokasyondan 15 dakika sonra damlatıldı. Her bir grupta çalışma (sağ) ve kontrol (sol) gözlerinde ödem ve hiperemi derecelendirildi. Ön segment fotoğrafları ve histopatolojik değerlendirme için konjunktiva örnekleri alındı ve derecelendirildi.

**Bulgular:** Provokasyon sonrası dönemde ödem ve hiperemi skorları provokasyon dönemi ile karşılaştırıldığında her grupta anlamlı farklılık belirlendi ( $P = 0,021$ ;  $P = 0,037$ ;  $P = 0,0001$ ). provokasyon dönemi ve provokasyon sonrası

Received: 12.05.2008 – Accepted: 19.10.2009

<sup>1</sup> Department of Ophthalmology, Faculty of Medicine, Gaziosmanpaşa University, Tokat - TURKEY

<sup>2</sup> Department of Biochemistry, Faculty of Medicine, Gaziosmanpaşa University, Tokat - TURKEY

<sup>3</sup> Department of Biostatistics, Faculty of Medicine, Gaziosmanpaşa University, Tokat - TURKEY

**Correspondence:** Erdoğan AYDIN, Department of Ophthalmology, Faculty of Medicine, Gaziosmanpaşa University, 60100 Tokat - TURKEY

E-mail: erdincaydin@yahoo.com

\* Presented at the 40th Turkish Ophthalmology Society National Congress, Antalya, Turkey, 2006.

dönemde histopatolojik skorlar değerlendirildiğinde, CAPE ve deksametazon sodyum fosfat gruplarında istatistiksel anlamlı farklılık bulunurken ( $P = 0,003$ ;  $P = 0,014$ ), olopatidine grubunda mevcut değildi ( $P = 0,096$ ).

**Sonuç:** Bu çalışma % 1 CAPE'nin klinik olarak % 0,1 olopatidine ve % 0,1 deksametazon kadar etkili olduğunu göstermektedir. % 1 CAPE, akut alerjik konjonktivitinin kontrol altına alınmasında % 0,1 olopatidine ve % 0,1 deksametazon'a bir alternatif olabilir.

**Anahtar sözcükler:** Alerjik konjonktivit, kafeik asit feniletıl ester, deksametazon sodyum fosfat, olopatidin hidroklorür

## Introduction

Allergic conjunctivitis is one of the most common ocular conditions encountered by clinicians. The pathogenesis of ocular allergy involves various mechanisms that result in mast cell degranulation and the release of mediators. These mediators lead to itching, conjunctival vasodilatation, increased vascular permeability, leukocyte chemotaxis, and ocular surface alterations (1, 2). Type 1 hypersensitivity has early and late periods. Vasodilatation and increased vascular permeability are the hallmarks of the early period and present themselves as severe itching, conjunctival injection, chemosis, and tearing. The selective H1 receptor is mainly responsible for itching, while the stimulation of the H2 receptor results in redness. The early period reactions are elicited within 5-30 min and then disappear slowly. Late period reactions initiate within 2-6 h without exposure to additional antigens, and inflammation is elevated by secondary mediators (3).

Mast cell stabilizers, H1 selective receptor blockers, nonsteroidal antiinflammatory drugs, and steroids have been commonly used for the treatment of allergic conjunctivitis. Alleviating this condition is an active area of research. Interventional studies of novel antiallergic drugs are still continuing.

Caffeic acid phenethyl ester (CAPE) and its analogs are found in various kinds of vegetative plant materials and fruits. The compounds are known to have antibacterial, antiviral, antiinflammatory, antiatherosclerotic, antioxidative, antiproliferative, immunostimulatory, and neuroprotective properties (4-10). The antiallergic effects of CAPE are unknown. In the present study, we investigated the antiallergic effects of CAPE and compared our data with the effects of 0.1% olopatadine hydrochloride and 0.1% dexamethasone sodium phosphate.

## Materials and methods

### Reagents and equipment

Compound 48/80, as a mast cell activator, and CAPE, as an inhibitor agent, were purchased from Sigma (St. Louis, MO, USA). The 1% CAPE, 0.1% olopatadine hydrochloride (Patanol®, Alcon), and 0.1% dexamethasone sodium phosphate (Maxidex®, Alcon) were instilled into the experimental eyes, and their solvents alone were instilled into the control eyes.

### Experimental Allergic Conjunctivitis

Animals were maintained and treated according to the Association for Research in Vision and Ophthalmology Resolution on the Use of Animals in Research. The experimental allergic conjunctivitis in 31 New Zealand albino male rabbits weighing 1.5-2.5 kg was provoked by a mast cell activator (compound 48/80). All animals were anesthetized by intramuscular injection of ketamine hydrochloride (25 mg/kg, Ketalar®) and locally by topical 0.4% oxybuprocaine hydrochloride (Benoxinate®), and then they were divided into 3 groups.

Thirty minutes before the provocation by compound 48/80 (50 mg/mL), each drug was applied as a pretreatment to the right eyes. Left eyes were used as controls and solvents of the agents were instilled. The same procedure (second instillation) was performed 15 min after the provocation. Group 1 ( $n = 11$ ) received 1% CAPE, group 2 ( $n = 10$ ) received 0.1% dexamethasone sodium phosphate, and group 3 ( $n = 10$ ) received 0.1% olopatadine hydrochloride in the experimental (right) eyes.

The bulbar and tarsal conjunctival edema and hyperemia in both eyes were scored at the 1st and 30th minutes after the provocation. Edema and hyperemia were evaluated according to the scale described by Abelson (Hyperemia: 0 = no hyperemia,

1 = mild, 2 = moderate, 3 = severe, 4 = extremely severe. Chemosis: 0 = none, 1 = mild, 2 = moderate, 3 = severe) (11). Scoring was performed by 2 trained observers. The average of the conjunctival edema and hyperemia scores was defined as the conjunctival inflammation score. Immediately after scoring, the physical appearances of the eye, including the periocular region anterior segment, were photographed for each group immediately after the provocation and 15 min after the second instillation.

### Histopathology

After sacrificing the animals, lids with conjunctiva were excised. These tissues were fixed in 10% buffered formaldehyde for 4 days and then were embedded in paraffin. Prepared sections, 4  $\mu$ m thick, were stained with hematoxylin and eosin stain (H&E) and examined under a light microscope under 200 $\times$  and 400 $\times$  magnifications. The conjunctival inflammation score, characterized by the infiltration of inflammatory cells (neutrophil and eosinophil polymorph nuclear lymphocytes), was calculated according to the following criteria by 2 trained observers: no cells = 1, mild infiltration = 2, moderate infiltration = 3, severe infiltration = 4.

### Statistical Analysis

The Kolmogorov-Smirnov test was used to evaluate the distribution of variables. If the distribution was normal, a 2 independent sample t-test was used to compare the clinical and pathological scores between the experimental and control groups. The paired sample t-test was used to compare the clinical and pathological scores of the provocation and postprovocation terms. The repeated measures 2-way ANOVA test was used to analyze the clinical and pathological scores of the experimental and control groups. The continuous variables were presented as means and standard deviations. A P-value less than 0.05 was considered significant. Analyses were performed using commercial software (SPSS 15.0 demo, Chicago, IL, USA).

### Results

In our study, we scored the bulbar and tarsal conjunctival edema and hyperemia in both eyes at the

1st and 30th minutes of the postprovocation term, according to the scale mentioned before. The mean  $\pm$  SD (range) of conjunctival edema and hyperemia scores for the provocation term and 30 min after the provocation was, respectively,  $2.63 \pm 0.59$  (1.5-3.5) and  $1.77 \pm 0.46$  (1-2.5) in the CAPE group,  $2.95 \pm 0.64$  (1.5-3.5) and  $1.90 \pm 0.61$  (1-2.5) in the olopatadine hydrochloride group, and  $3.05 \pm 0.55$  (2-3.5) and  $1.95 \pm 0.15$  (1.5-2.0) in the dexamethasone sodium phosphate group experimental eyes. The corresponding scores in the control eyes were  $2.59 \pm 0.58$  (1.5-3.5) and  $2.27 \pm 0.47$  (1.5-3.0) in the CAPE group,  $2.95 \pm 0.60$  (1.5-3.5) and  $2.50 \pm 0.58$  (1.5-3.5) in the olopatadine hydrochloride group, and  $3.15 \pm 0.47$  (2.5-3.5) and  $2.75 \pm 0.42$  (2.0-3.5) in dexamethasone sodium phosphate group, respectively. The mean  $\pm$  SD (range) of the pathologic scores at the 1st and 30th minutes of the postprovocation term were, respectively,  $2.72 \pm 0.78$  (2.0-4.0) and  $1.90 \pm 0.30$  (1.0-4.0) in the CAPE group,  $3.10 \pm 0.73$  (2.0-4.0) and  $2.10 \pm 0.73$  (1.0-3.0) in the olopatadine hydrochloride group, and  $3.10 \pm 0.87$  (2.0-4.0) and  $2.0 \pm 0.47$  (1.0-3.0) in the dexamethasone sodium phosphate group in the experimental eyes. The corresponding scores in the control eyes were  $2.82 \pm 0.75$  (2-4) and  $2.55 \pm 0.52$  (2-3) in the CAPE group,  $2.9 \pm 0.57$  (2-4) and  $2.6 \pm 0.52$  (2-3) in the olopatadine hydrochloride group, and  $2.9 \pm 0.74$  (2-4) and  $2.6 \pm 0.52$  (2-3) in the dexamethasone sodium phosphate group.

When the clinical scores of the postprovocation term were compared with the provocation term scores for the experimental eyes and control eyes, statistically significant differences were detected in all groups. For CAPE, olopatadine hydrochloride, and dexamethasone sodium phosphate,  $P = 0.001$ ,  $P = 0.001$ , and  $P = 0.001$ ; and  $P = 0.002$ ,  $P = 0.004$ , and  $P = 0.011$  for the experimental and control eyes, respectively (Table 1) (Figures 1 and 2).

When the clinical scores of the experimental and control eyes were compared for the provocation term and the postprovocation term, statistically significant differences were only detected for the postprovocation term in all groups ( $P = 0.021$ ,  $P = 0.0001$ , and  $P = 0.037$ , respectively) (Table 1).

Table 1. Clinical scores of study and control eyes for the provocation and postprovocation terms.

Clinical Scores		Study Eye		Control Eye		t <sup>‡</sup>	P
		Mean	SD	Mean	SD		
CAPE	Provocation Term	2.63	0.60	2.59	0.58	0.181	0.858
	Postprovocation Term	1.77	0.47	2.27	0.47	-2.510	0.021
		t <sup>§</sup> = 4.811, P = 0.001		t <sup>§</sup> = 4.183, P = 0.002			
O	Provocation Term	2.95	0.64	2.95	0.60	0.000	1.000
	Postprovocation Term	1.90	0.62	2.50	0.58	-2.250	0.037
		t <sup>§</sup> = 5.659, P < 0.001		t <sup>§</sup> = 3.207, P = 0.011			
Dx	Provocation Term	3.05	0.55	3.15	0.47	-0.435	0.669
	Postprovocation Term	1.95	0.16	2.75	0.42	5.580	<0.001
		t <sup>§</sup> = 5.547, P < 0.001		t <sup>§</sup> = 3.857, P = 0.004			

CAPE: caffeic acid phenethyl ester, O: olopatadine hydrochloride, Dx: dexamethasone sodium phosphate.

<sup>‡</sup>: Two independent samples' t-test result (the comparison between the study and control eyes).

<sup>§</sup>: Paired samples' t-test result (the comparison between the pre- and postprovocation terms).

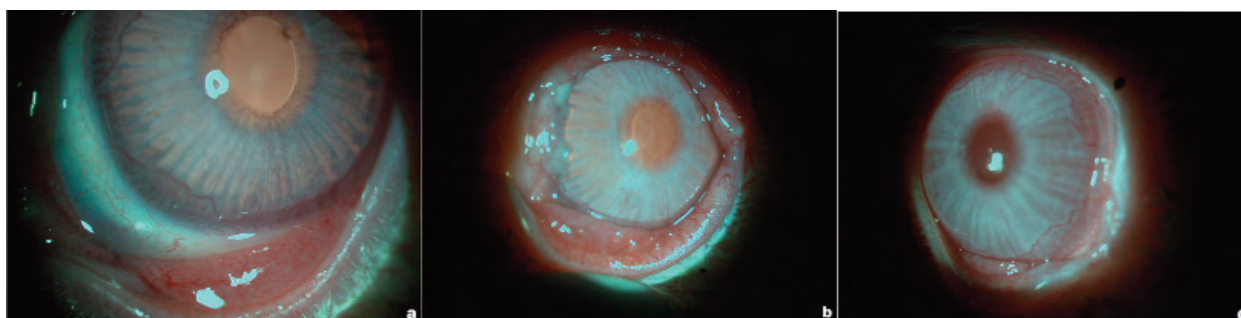

Figure 1. Pictures of eyes in the provocation term, a: 1% CAPE, b: 0.1% olopatadine hydrochloride, c: 0.1% dexamethasone sodium phosphate.

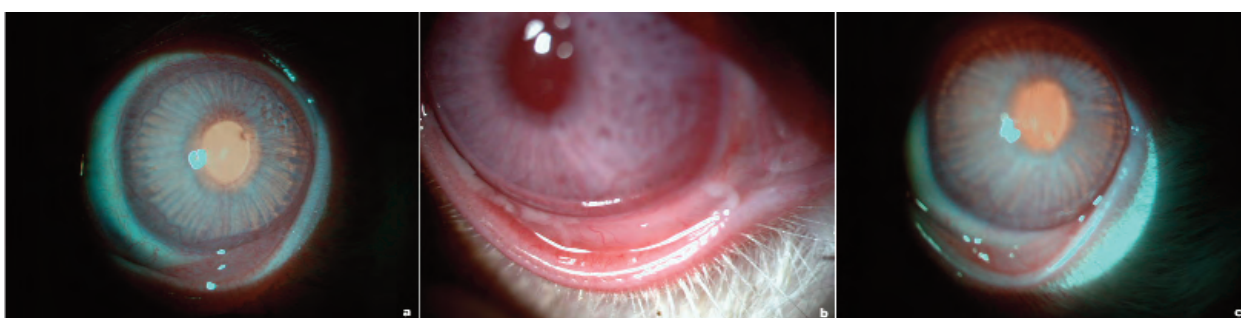

Figure 2. Pictures of eyes showing the reduction of conjunctival edema, hyperemia, and ocular mucus following instillation of agents in the postprovocation term, a: 1% CAPE, b: 0.1% olopatadine hydrochloride, c: 0.1% dexamethasone sodium phosphate.

When the pathological scores of the postprovocation term were compared with the provocation term for the experimental and control eyes, there were statistically significant differences observed in the experimental eyes but not in the control eyes. For CAPE, olopatadine hydrochloride,

and dexamethasone sodium phosphate,  $P = 0.011$ ,  $P = 0.007$ , and  $P = 0.001$ , respectively (Table 2) (Figures 3-8).

When the pathology scores of the experimental and control eyes were compared for the provocation term and the postprovocation term, statistically

Table 2. Pathological scores of study and control eyes for the provocation and postprovocation terms.

Pathological Scores		Study Eye		Control Eye		t <sup>‡</sup>	P
		Mean	SD	Mean	SD		
CAPE	Provocation Term	2.72	0.79	2.82	0.75	-0.277	0.784
	Postprovocation Term	1.91	0.30	2.55	0.52	-3.500	0.003
		t <sup>§</sup> = 3.105, P = 0.011		t <sup>§</sup> = 1.936, P = 0.082			
O	Provocation Term	3.10	0.74	2.90	0.57	0.679	0.506
	Postprovocation Term	2.10	0.74	2.60	0.52	-1.756	0.096
		t <sup>§</sup> = 6.708, P < 0.001		t <sup>§</sup> = 1.964, P = 0.081			
Dx	Provocation Term	3.10	0.88	2.90	0.74	0.552	0.588
	Postprovocation Term	2.00	0.47	2.60	0.52	-2.714	0.014
		t <sup>§</sup> = 3.498, P = 0.007		t <sup>§</sup> = 1.406, P = 0.193			

CAPE: caffeic acid phenethyl ester, O: olopatadine hydrochloride, Dx: dexamethasone sodium phosphate.

<sup>‡</sup>: Two independent samples' t-test result (the comparison between study and control eyes).

<sup>§</sup>: Paired samples' t-test result (the comparison between pre- and postprovocation terms).

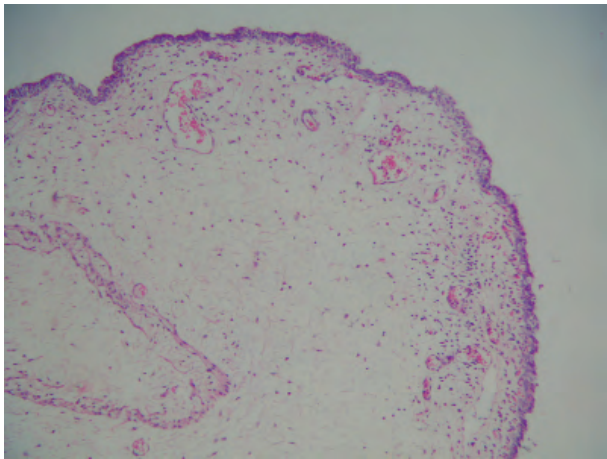


Figure 3. Stromal edema and superficial, mild infiltration of eosinophils and mononuclear leukocytes in the conjunctiva in the provocation term of the CAPE group (H&E ×5).

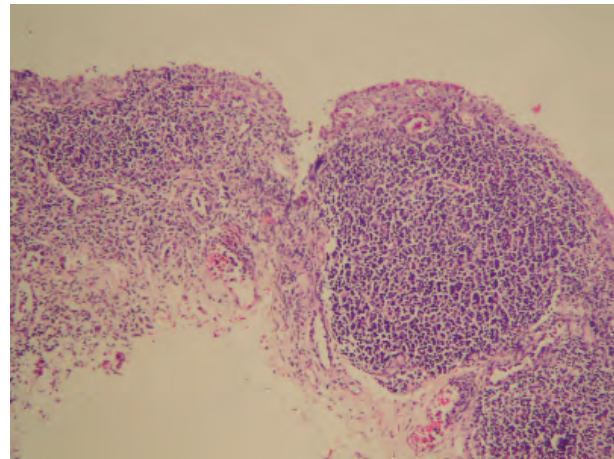


Figure 4. Lymphoid follicle formed an intensive lymphoplasmacytic cell infiltration and scattered eosinophilic leukocytes in the superficial portion of the conjunctiva following instillation of agents in the postprovocation term of the CAPE group (H&E ×20).

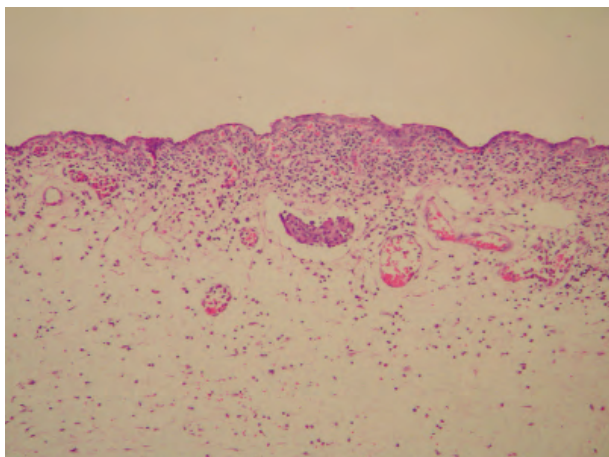


Figure 5. Superficial mild mononuclear and more rarely polymorphonuclear leukocyte cell infiltration in the edematous stroma of the conjunctiva in the provocation term of the olopatadine hydrochloride group (H&E  $\times 8$ ).

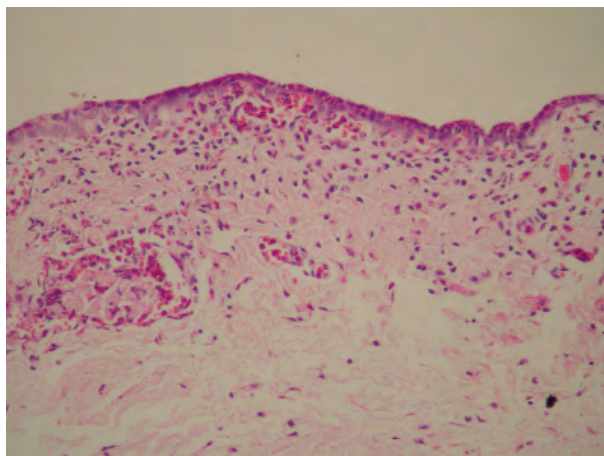


Figure 7. Stromal and epithelial infiltration with eosinophilic leukocytes in the conjunctiva in the provocation term of the dexamethasone sodium phosphate group (H&E  $\times 40$ ).

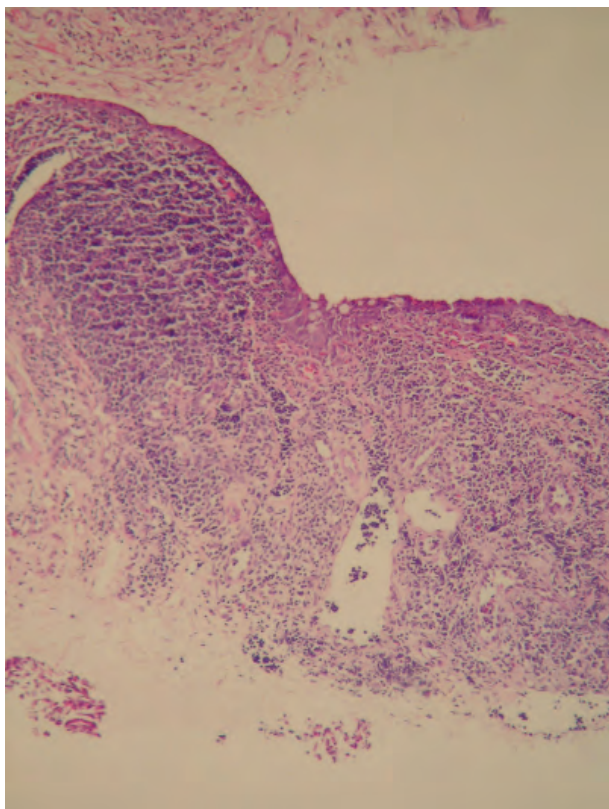


Figure 6. Extensive and intensive mononuclear inflammatory cell infiltration with lymphoid follicle formation in the conjunctiva in the postprovocation term of the olopatadine hydrochloride group (H&E  $\times 10$ ).

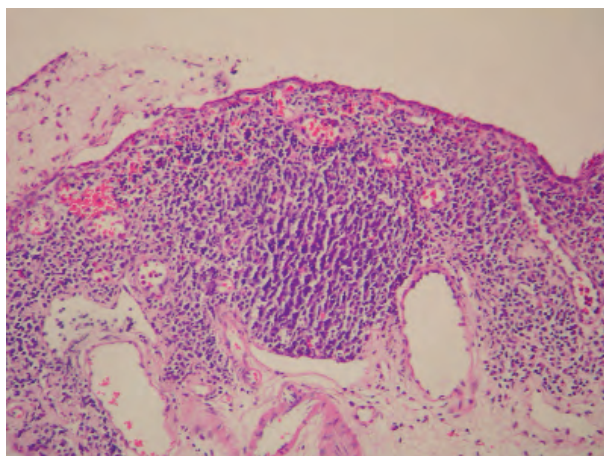


Figure 8. Intensive mononuclear inflammatory cell infiltration with a lymphoid follicle in the conjunctiva and infiltration of the conjunctiva epithelium by eosinophilic leukocytes in the postprovocation term of the dexamethasone sodium phosphate group (H&E  $\times 40$ ).

significant differences were only detected for the postprovocation term in the CAPE and dexamethasone sodium phosphate groups ( $P = 0.003$  and  $P = 0.014$ , respectively) (Table 2).

### Discussion

The popular folk medicine propolis (bee glue) is alleged to possess broad-spectrum usage qualities, including antimicrobial, antiinflammatory, and tumor

growth inhibitor effects. Caffeic acid and analogs extracted from propolis are reported to have antibacterial, antiviral, antiinflammatory, antiatherosclerotic, antioxidative, antiproliferative, immunostimulatory, and neuroprotective properties (4-10). To the best of our knowledge, this is the first study that investigates the antiallergic properties of CAPE.

The pathogenesis of ocular allergy involves various mechanisms that lead to mast cell degranulation and the release of chemical mediators. These mediators reveal the symptoms and signs of allergic conjunctivitis, such as redness, epiphora, and chemosis, that occur as a result of increased vascular permeability (1,3).. Ko et al. described the typical findings of allergic conjunctivitis, including itching, tearing, chemosis, and redness after the instillation of compound 48/80 (12). They stressed that these findings were observed 5-30 min (early period) and 1.5 h (late period) after the provocation. All symptoms and signs disappeared within 24 h in their study. In the present study, the acute allergic conjunctivitis model was used as described by Ko et al. (12).

Olopatadine is one of the most recent drugs that can be added to this particular class of antiallergic agents. It displays antihistaminic and membrane-stabilizing properties, but also has effects on other mediators involved in the allergic response. In comparative studies, the H1 selectivity of olopatadine was superior to that of other ocularly used antihistamines studied, such as ketotifen, levocabastine, antazoline, and pheniramine (13,14).

When Abelson and Greiner compared the effect of olopatadine on itching and vascular permeability with the effects of levocabastine, olopatadine was superior to levocabastine (15). Schoch reported that ketotifen was more effective in reducing the vascular permeability of eyelids compared to olopatadine and levocabastine in a conjunctivitis model in rats (16). Ozturk et al. emphasized that topical lodoxamide was more effective at reducing signs of allergic conjunctivitis than sodium cromoglycate, but less effective than dexamethasone (17). In our study, no significant differences were found among the groups with regard to suppression of allergic conjunctivitis. However, dexamethasone showed partial superiority to CAPE and olopatadine in reducing clinical scores.

Abelson and Udell have demonstrated the presence of H2 receptors in human tissues (18). Combined use of H1 and H2 antagonists has also been shown to inhibit the conjunctival allergic reaction caused by histamine (19). It is well known that prostaglandins (PG) and arachidonic acid (AA) metabolites are effective at increasing histamine secretion and vascular permeability. Clinical studies that document the effectiveness of prostaglandin synthesis inhibitors, diclofenac sodium, and ketorolac tromethamine on seasonal allergic conjunctivitis also support this theory (20). Steroids prevent PG and AA metabolites by inhibiting phospholipase, an enzyme that decreases histamine secretion and vascular permeability. Leukotriene inhibitors in active anaphylaxis models and cyclooxygenase inhibitors such as ketorolac and flurbiprophen were shown to be ineffective in acute allergic conjunctivitis models (21). Conversely, prolonged topical use of steroids may lead to steroid-specific optic adverse reactions such as secondary infection, glaucoma, or cataracts in humans (22).

There were some limitations of our study. First, it is well known that allergic conjunctivitis correlates with significant changes in the levels of different mediators in the lacrimal fluid. These mediators were not included in this study. Second, rabbit conjunctiva often shows cell clusters in quite normal conditions. In addition, the punch biopsy might affect histopathological results.

In conclusion, our data demonstrated that 1% CAPE was as clinically efficacious as 0.1% olopatadine and 0.1% dexamethasone. In this manner, 1% CAPE may be a useful alternative to 0.1% olopatadine and 0.1% dexamethasone in the treatment of acute allergic conjunctivitis. Further studies in larger groups are needed to confirm these data.

### Acknowledgements

This study was supported by funds from Gaziosmanpaşa University. We owe special thanks to R. Doğan Köseoğlu MD, Department of Pathology, Gaziosmanpaşa University, for helping with the light microscopy of the conjunctiva, and Tamer Yener DVM PhD, Gaziosmanpaşa University Experimental Animal Research Laboratory, for assisting with animal processing.



## References

1. Abelson MB, Schafer K. Conjunctivitis of allergic origin. Immunologic mechanisms and current approach to therapy. *Surv Ophthalmol* 1993; 38: 115-32.
2. Meijer F, Van Delft JL, Garrelds IM, Van Haeringen NJ, Kijlstra A. Nitric oxide plays a role as a mediator of conjunctival edema in experimental allergic conjunctival edema in experimental allergic conjunctivitis. *Exp Eye Res* 1996; 62: 359-65.
3. Roith I, Brostoff J, Male DK. *Immunology*. St. Louis, Missouri, Mosby; 1985. 19.1-19.17.
4. Setzer WN, Setzer MC, Bates RB, Nakkiev P, Jacks BR, Chen L et al. Antibacterial hydroxycinnamic esters from *Piper caninum* from Paluma, North Queensland, Australia. The crystal and molecular structure of (+) bornyl coumarate. *Planta Med* 1999; 65: 747-9.
5. King PJ, Ma G, Miao W, Jia Q, McDougall BR, Renecke MG et al. Structure activity relationships, analogues of the caffeoylquinic and dicaffeoyltartaric acids as potent inhibitors of human immunodeficiency virus type 1 integrate and replication. *J Med Chem* 1999; 42: 497-509.
6. Sud'ina GF, Mirzoeva OK, Pushkareva MA, Korshunova GA, Sumbatyan NV, Varfolomeev D. Caffeic acid phenethyl ester as a lipoxygenase inhibitor with antioxidant properties. *FEBS Lett* 1993; 329: 21-24.
7. Nardini M, D'Aquino M, Tomassi G, Gentili V, Di Felice M, Scaccini C. Inhibition of human low density lipoprotein oxidation by caffeic acid and other hydroxycinnamic acid derivatives. *Free Radical Biol Med* 1995; 19: 541-52.
8. Chen JH, Ho CT. Antioxidant activities of caffeic acid and its related hydroxycinnamic acid compounds. *J Agric Food Chem* 1997; 45: 2374-8.
9. Chen JH, Shao Y, Huan MT, Chin CK, Ho CT. Inhibitory effect of caffeic acid phenethyl ester on human leukemia HL 60 cells. *Cancer Lett* 1996; 108: 211-4.
10. Lin LC, Kuo YC, Chou JC. Immunomodulatory principles of *Dichrocephala bicolor*. *J Nat Prod* 1999; 2: 405-8.
11. Abelson MB. Comparison of the conjunctival allergen challenge model with the environmental model of allergic conjunctivitis. *Acta Ophthalmol Scand Suppl* 1999; 228: 38-42.
12. Ko SM, Kim MK, Kim JC. The role of nitric oxide in experimental allergic conjunctivitis. *Cornea* 2000; 19: 84-91.
13. Sharif NA, Xu SX, Yanni JM. Olopatadine (AL-4943A): ligand binding and functional studies on a novel, long acting H1-selective histamine antagonist and anti-allergic agent for use in allergic conjunctivitis. *J Ocul Pharmacol Ther* 1996; 12: 401-7.
14. Sharif NA, Xu SX, Miller ST, Gamache DA, Yanni JM. Characterization of the ocular antiallergic and antihistaminic effect of olopatadine (AL-4943A), a novel drug for treating ocular allergic diseases. *J Pharmacol Exp Ther* 1996; 278: 1252-61.
15. Abelson MB, Greiner JV. Comparative efficacy of olopatadine 0.1% ophthalmic solution versus levocabastine 0.05% ophthalmic suspension using the conjunctival allergen challenge model. *Curr Med Res Opin* 2004; 20: 1953-8.
16. Schoch C. Effect of ketotifen fumarate, olopatadine, and levocabastine on ocular active anaphylaxis in the guinea pig and ocular immediate hypersensitivity in the albino rat. *Ocul Immunol Inflamm* 2005; 13: 39-44.
17. Ozturk F, Guler M, Ilker SS, Sobaci G. Efficacy of topical lodoxamide vs sodium cromoglycate and dexamethasone in rabbits with passive allergic conjunctivitis. *Ann Ophthalmol* 2002; 34: 100-3.
18. Abelson MB, Udell IJ. H2-receptors in the human ocular surface. *Arch Ophthalmol* 1981; 99: 302-4.
19. Leon J, Charap A, Duzman E, Shen CD. Efficacy of cimetidine/pyrilamine eye drops. A dose response study with histamine challenge. *Ophthalmology* 1986; 93: 120-23.
20. Koay P. The emerging roles of topical non-steroidal anti-inflammatory agents in ophthalmology. *BJO* 1996; 80: 480-5.
21. Gary RK, Woodward DF, Nieves AL, Williams LS, Gleason JG, Wasserman MA. Characterization of the conjunctival vasopermeability response to leukotrienes and their involvement in immediate hypersensitivity. *Invest Ophthalmol Vis Sci* 1988; 29: 119-26.
22. Tabbara KF. Ocular complications of vernal keratoconjunctivitis. *Can J Ophthalmol* 1999; 34: 88-92.