

1-1-2010

The comparison of MRI findings with severity score of incontinence after pubovaginal sling surgery

SERDAR TARHAN

BİLALİ GÜMÜŞ

GÖKHAN TEMELTAŞ

GÜLGÜN YILMAZ OVALI

SELİM SERTER

See next page for additional authors

Follow this and additional works at: <https://journals.tubitak.gov.tr/medical>



Part of the [Medical Sciences Commons](#)

Recommended Citation

TARHAN, SERDAR; GÜMÜŞ, BİLALİ; TEMELTAŞ, GÖKHAN; OVALI, GÜLGÜN YILMAZ; SERTER, SELİM; and GÖKTAN, CİHAN (2010) "The comparison of MRI findings with severity score of incontinence after pubovaginal sling surgery," *Turkish Journal of Medical Sciences*: Vol. 40: No. 4, Article 7. <https://doi.org/10.3906/sag-0904-35>

Available at: <https://journals.tubitak.gov.tr/medical/vol40/iss4/7>

This Article is brought to you for free and open access by TÜBİTAK Academic Journals. It has been accepted for inclusion in Turkish Journal of Medical Sciences by an authorized editor of TÜBİTAK Academic Journals. For more information, please contact academic.publications@tubitak.gov.tr.

The comparison of MRI findings with severity score of incontinence after pubovaginal sling surgery

Authors

SERDAR TARHAN, BİLALİ GÜMÜŞ, GÖKHAN TEMELTAŞ, GÜLGÜN YILMAZ OVALI, SELİM SERTER, and CİHAN GÖKTAN

The comparison of MRI findings with severity score of incontinence after pubovaginal sling surgery

Serdar TARHAN¹, Bilali GÜMÜŞ², Gökhan TEMELTAŞ², Gülgün YILMAZ OVALI¹,
Selim SERTER¹, Cihan GÖKTAN¹

Aim: To investigate the relationship between postoperative MRI findings and the severity score of incontinence in patients treated with pubovaginal sling surgery.

Materials and methods: Fifty-two female patients treated with pubovaginal slings were included in the study. These patients' severity scores of incontinence were evaluated in the postoperative 6th month. All the patients were examined using MRI on the same day. A T2-weighted sagittal image of the midline structures, including the symphysis, urethra, and coccyx, was obtained at rest and at maximal strain. The mobility of the bladder floor and change in the posterior urethrovessical angle were calculated for each patient. Relationships between the severity score of incontinence and mobility of the bladder floor and change in the posterior urethrovessical angle were analyzed using Spearman's rank correlation coefficients by means of SPSS.

Results: A positive correlation was found between the severity score of incontinence and the mobility of the bladder neck and also between the score and the degree of posterior urethrovessical angle ($r = 0.797, P = 0.000$; $r = 0.62, P = 0.000$, respectively). There was also a positive correlation between the severity score of incontinence and the increase in posterior urethrovessical angle during Valsalva's maneuver ($r = 0.47, P = 0.02$).

Conclusion: MRI is a non-invasive diagnostic method for the evaluation of bladder floor position, mobility of the bladder neck, and posterior urethrovessical angle in patients with stress urinary incontinence. It can play a major role in the postoperative follow up of stress urinary incontinence. MRI can also be used for the assessment of success in pubovaginal sling surgery.

Key words: Urinary incontinence, magnetic resonance imaging, pubovaginal slings

Pubovajinal sling operasyonu sonrası inkontinans şiddet indeksi ile MRG bulgularının karşılaştırılması

Amaç: Bu çalışmanın amacı pubovajinal sling operasyonu ile tedavi edilen hastalarda postoperatif MRG bulguları ile inkontinans şiddet indeksi arasındaki ilişkiyi araştırmaktır.

Yöntem ve gereç: Pubovajinal sling operasyonu geçirmiş 52 kadın hasta çalışmaya dahil edildi. Postoperatif altıncı ayda hastaların inkontinans şiddet indeksleri değerlendirildi. Aynı gün hastaların MRG incelemeleri de yapıldı. Hastalardan istirahatatta ve maksimum ıkmama sırasında simfisis, üretra ve koksiksi de içerecek şekilde T2-A sagittal görüntüler elde edildi. Her hasta için mesane tabanının mobilitesi ve posterior üretrovessikal açı değişiklikleri hesaplandı. İnkontinans şiddet indeksi ile mesane tabanı mobilitesi ve posterior üretrovessikal açı değişiklikleri arasındaki ilişki SPSS programı ile Spearman's Rho korelasyon testi kullanılarak analiz edildi.

Received: 30.04.2009 – Accepted: 04.02.2010

¹ Department of Radiology, Faculty of Medicine, Celal Bayar University, Manisa - TURKEY

² Department of Urology, Faculty of Medicine, Celal Bayar University, Manisa - TURKEY

Correspondence: Serdar TARHAN, Department of Radiology, Faculty of Medicine, Celal Bayar University, Manisa - TURKEY

E-mail: sertarhan@hotmail.com

* This study was performed in Celal Bayar University Radiology and Urology Departments and presented at the 23th National Congress of Radiology as a preliminary report.

Bulgular: İnkontinans şiddet indeksi ile mesane boynu mobilitesi arasında ve şiddet indeksi ile posterior üretrovezikal açının derecesi arasında pozitif korelasyon saptandı (sırasıyla, $r = 0,797$, $P = 0,000$; $r = 0,62$, $P = 0,000$). Valsalva manevrası sırasında posterior üretrovezikal açıdaki artış ile inkontinans şiddet indeksi arasında da pozitif korelasyon görüldü ($r = 0,47$, $P = 0,02$).

Sonuç: MRG stres üriner inkontinanslı hastalarda mesane tabanının pozisyonunun, mesane boynu mobilitesinin ve posterior üretrovezikal açının değerlendirilmesinde noninvaziv bir tanı yöntemidir. Stres üriner inkontinansın postoperatif takibinde önemli rol oynayabilir. MRG pubovajinal sling cerrahisinin başarısının değerlendirilmesinde de kullanılabilir.

Anahtar sözcükler: Üriner inkontinans, manyetik rezonans görüntüleme, pubovajinal sling

Introduction

Stress urinary incontinence is a significant problem in elderly women. It affects primarily parous women and in many cases is thought to be caused by injury to pelvic floor support structures during childbirth (1,2). Magnetic resonance imaging (MRI) has recently been used for the evaluation of urinary incontinence because it is non-invasive and does not require ionizing radiation. It has the advantages of rapid imaging in multiple planes, high spatial resolution, and contrast resolution allowing the identification of small support structures of the pelvic floor. Vaginal sling surgery is regarded as the gold standard for the treatment of stress urinary incontinence, which is caused by both urethral hypermobility and intrinsic sphincter deficiency.

The purpose of this study was to investigate the relationship between the postoperative MRI findings and the severity score of incontinence in the patients treated with pubovaginal slings using rectus abdominis fascia.

Materials and methods

Fifty-two female patients (31-58 years old, mean 49) treated with pubovaginal slings using rectus abdominis fascia between January 2000 and November 2007 were included in the study. Trial protocol approval was obtained from the institutional ethics committee and the study was performed according to the revised Declaration of Helsinki of 1989. Each patient provided written consent after having been fully informed about the study protocol. The incontinence severity scores of patients were evaluated in the postoperative 6th month. Objective outcome measures, i.e. the frequency of urine loss,

recorded in their diaries by the patients as episodes of urine loss during a 1-week period and over 1 day; the severity of incontinence, assessed using 4 indices in the questionnaires (Table 1), and from the total scores, divided into 3 groups as mild, moderate, and severe; and the frequency of nocturnal urine loss, in which patients who reported incontinence at night recorded (in the questionnaires) how often this occurred each month. All the patients were examined by means of MRI on the same day. Using a pressure-sensitive rectal balloon catheter, all patients were trained to correctly perform Valsalva's maneuver before imaging.

Table 1. The system for scoring the severity of incontinence.

Variable	Score
Frequency of urine loss	
3-4 times/month	1
a few times a week	2
daily	3
Use of protective pads or garments because of incontinence	
none	1
only occasionally	2
most of the time	3
Amount of urine loss	
a few drops	1
a little	2
a lot	3
Restrictions in daily activities caused by incontinence	
none	1
some	2
many	3
Level (severity) of incontinence (total score)	
mild	4-6
moderate	7-9
severe	10-12

MRI was performed with 0.23 T open-configuration system (Gyrosan Panorama 0.23; Philips Medical Systems, Helsinki, Finland). All patients were imaged with a body-phased-array receiver coil in the supine position. No premedication was utilized. To ensure a full bladder, patients were asked not to void for 2 h before imaging. After performing spoiled gradient-echo localizer series, a T2-weighted sagittal image of the midline structures, including the symphysis, urethra, and coccyx, was obtained at rest and at maximal strain. Standard fast spin-echo sequence (TR/effective TE, 3500/120; echo train length, 16; slice thickness, 9 mm; gap, 1 mm; number of excitations, 2; matrix, 256 × 256; field of view, 36 cm; acquisition time, 3.5 min) was used at rest and a modified fast spin-echo sequence (TR/effective TE, 12000/160; echo train length, 96; slice thickness, 7 mm; gap, 1 mm; number of excitations, 1; matrix, 160 × 160; field of view, 36 cm; acquisition time, 10 s) was used during Valsalva's maneuver. The modified fast spin-echo sequence was performed in triplicate during Valsalva's maneuver. The MR image showing maximal maneuver effect was used for analysis.

On sagittal MR images, the pubococcygeal line drawn between the inferior aspect of the symphysis and the distal joint of the coccyx was used as the reference line. The vertical distance from the pubococcygeal line to the most inferior portion of bladder floor was measured at rest and at maximal strain (Figure 1-A). The mobility of the bladder floor (i.e. the difference between rest and maximal strain) was calculated for each patient. Posterior urethrovesical angle was defined as the angle between the urethral axis and the posterior border of the bladder base (Figure 1-B). Posterior urethrovesical angle was measured at rest and at maximal strain. Change in the posterior urethrovesical angle (i.e. the difference between rest and maximal strain) was calculated for each patient. Relationships between the severity score of incontinence and mobility of the bladder floor and change in the posterior urethrovesical angle were analyzed using Spearman's rank correlation coefficients by means of SPSS. A significance level of P less than 0.05 was used in the test.

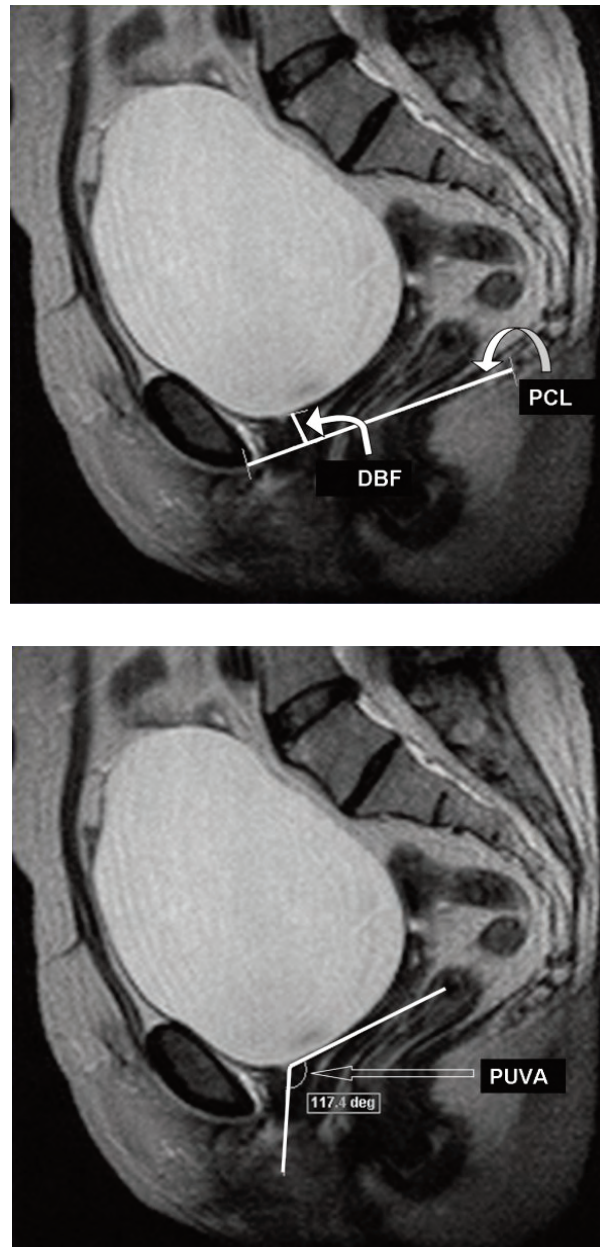


Figure 1. Sagittal T2-weighted MR images demonstrating the pubococcygeal line (PCL) and distance to the bladder floor (DBF) (A) and a posterior urethrovesical angle (PUVA)(B).

Results

The examination was well tolerated by all patients. The duration of the MRI examination was approximately 4 min for each patient. Diagnostic-quality MR images were obtained from all patients.

The severity score of incontinence of the patients was between 0-3 in 20 patients, 4-6 in 20 patients (mild incontinence), 7-9 in 9 patients (moderate incontinence) and 10-12 in 3 patients (severe incontinence) (mean \pm SD, 4.23 ± 1.63).

The bladder neck was above the pubococcygeal line in all patients at rest whereas it was below the pubococcygeal line in 16 patients during Valsalva's maneuver. Mobility of the bladder neck was between 3 and 32 mm (mean \pm SD, 17.83 ± 8.3 mm) (Figures 2-4).

Posterior urethrovesical angle was between 94 and 137° (mean \pm SD, $121 \pm 10.8^\circ$) and 114 - 175° (mean \pm SD, $138 \pm 12.5^\circ$) at rest and during Valsalva's maneuver, respectively. Posterior urethrovesical angle increased by 1 - 51° (mean \pm SD, $20 \pm 11.6^\circ$) at maximal strain.

Finally, postoperative MRI findings and the patients' severity scores of incontinence were compared. A positive correlation was found between the severity score of incontinence and the mobility of the bladder neck and between the score and the degree of posterior urethrovesical angle ($r = 0.797$, $P = 0.000$; $r = 0.62$, $P = 0.000$, respectively) (Figure 5).

There was also a positive correlation between the severity score of incontinence and increase in posterior urethrovesical angle during Valsalva's maneuver ($r = 0.47$, $P = 0.02$).

Discussion

Stress urinary incontinence is a significant problem in elderly women. It affects primarily parous women and in many cases is thought to be caused by injury to pelvic floor support structures during childbirth (1,2). The descent of the bladder neck upon straining has been observed more in women with a history of vaginal delivery (3-5). Currently, it is thought that deformity of the levator ani causes muscle dysfunction, possibly due to tearing and denervation, leading to an increased burden on the endopelvic fascia. When the pubocervical portion of this fascia stretches or tears, the urethra and the bladder neck become hypermobile. Increased abdominal pressure, often during a cough or laugh, then increases urethral closing pressure and thus urinary leakage occurs (6). Increased pelvic floor laxicity and mobility of the bladder neck have been observed in patients with stress incontinence (1,7).

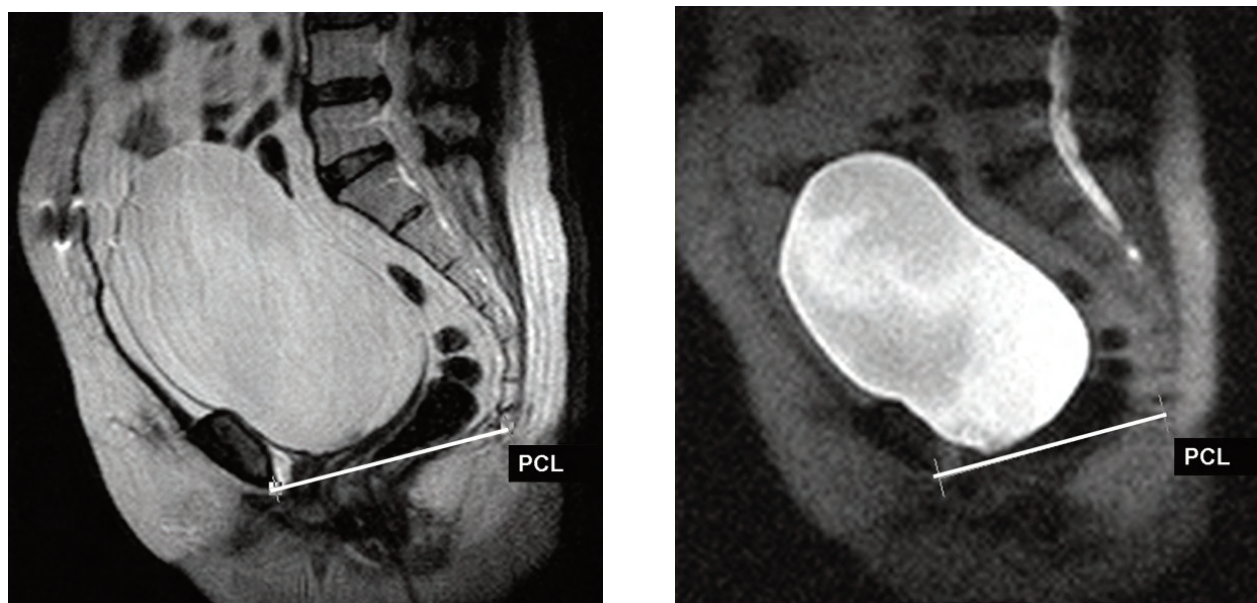


Figure 2. A 51-year-old postoperative asymptomatic woman (the severity score of incontinence, 0). Sagittal T2-weighted MR image at rest (A) and sagittal modified T2-weighted MR image on maximal straining (B), showing no significant bladder neck descent (PCL: pubococcygeal line).

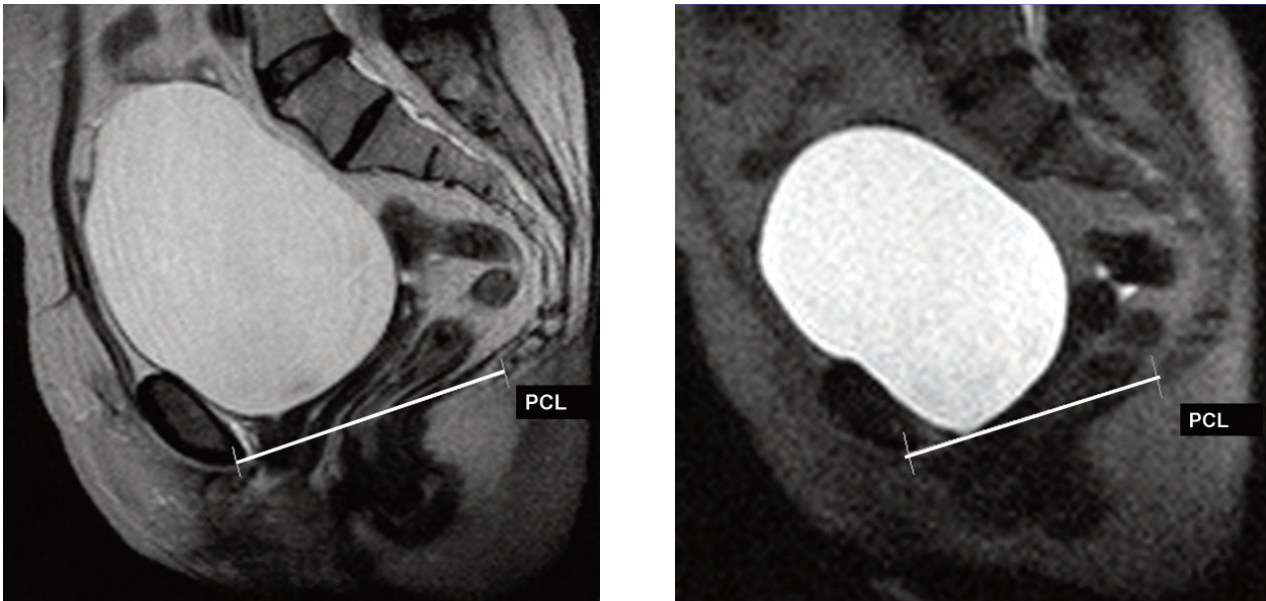


Figure 3. A 53-year-old postoperative mild symptomatic woman (the severity score of incontinence, 6). Sagittal T2-weighted MR image at rest (A) and sagittal modified T2-weighted MR image on maximal straining (B), showing minimal bladder neck descent (PCL: pubococcygeal line).

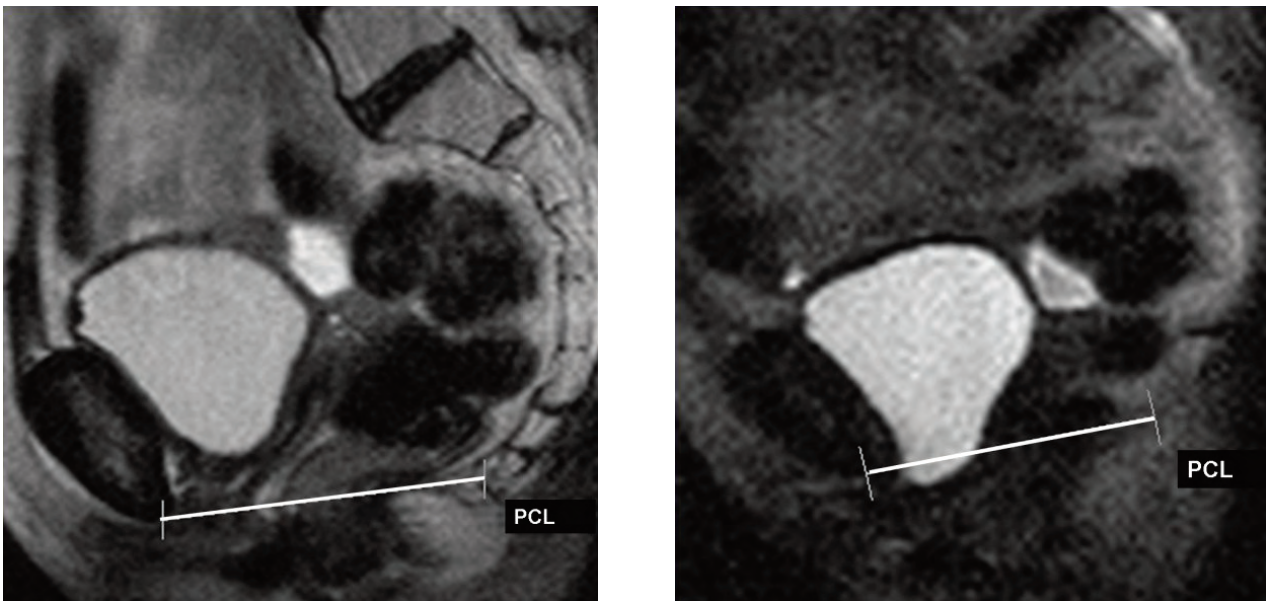


Figure 4. A 50-year-old postoperative severe symptomatic woman (the severity score of incontinence, 10). Sagittal T2-weighted MR image at rest (A) and sagittal modified T2-weighted MR image on maximal straining (B), showing some bladder neck descent. Bladder neck has descended below pubococcygeal line (PCL: pubococcygeal line).

Fielding et al. reported that mobility of the bladder neck and rotation of urethra manifested by an increased urethrovesical angle were found to be

greater in women with stress incontinence (1). The relatively large posterior urethrovesical angles generated at maximal strain in both the continent and

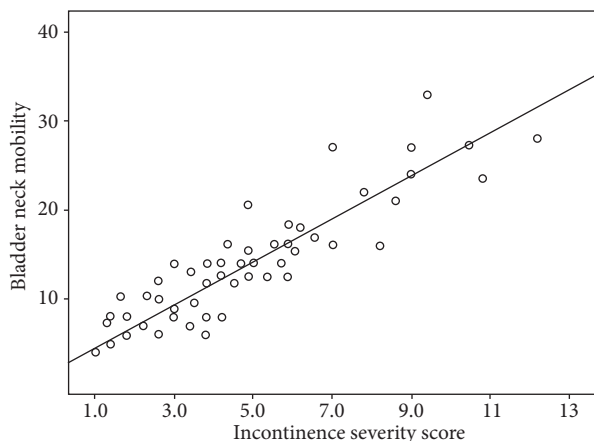


Figure 5. Correlation between the severity score of incontinence and the mobility of the bladder neck (mm) ($r = 0.797$, $P = 0.000$; Spearman's rho correlation test).

incontinent women are expected. Although previous studies have reported that a large (greater than 115°) posterior urethrovesical angle is associated with stress incontinence, recent studies have shown a significant overlap with continent women (8,9).

Various radiological techniques have been developed to meet the need for accurate visualization and quantitative assessment in the diagnosis of pelvic floor disorders (10-12). Bead-chain cystourethrography, colpocystorectography, and defecography have become key techniques for investigating all compartments (13). Vaginography explores the middle compartment and reveals vaginal fistulas (12). However, their drawbacks include high exposure to ionizing radiation and an absence of information on the surrounding soft tissue (13). Currently, ultrasonography (US) and MRI are used to evaluate stress urinary incontinence. Perineal, transvaginal, and transrectal US are well suited for the static and dynamic examination of the anterior compartment (4,11,14,15). Nonetheless, this method requires experience and is operator dependent. The contrast resolution may be lost with an increasing depth. MRI overcomes many of these limitations. The advantage of MRI is that it permits a complete analysis of the 3 pelvic compartments in a single procedure without exposure to ionizing radiation. The contrast of soft tissues is excellent, and it provides detailed anatomic information; in addition, no contrast agent

application is needed (16). MRI examinations may also be performed in the upright position if suitable MRI systems are used. (1,17,18).

The development of stronger and faster gradients and ultrafast T2-weighted pulse sequences with acquisition times under 1 s now permit a dynamic evaluation of the pelvic compartments at maximal strain (18-23). Our MR unit was not appropriate for dynamic evaluation. We used a standard T2-weighted fast spin-echo sequence (acquisition time, 3.5 min) at rest and a modified T2-weighted fast spin-echo sequence (acquisition time, 10 s) during Valsalva's maneuver. A major disadvantage of the technique may be related to the inability to ensure an adequate straining effort. In an attempt to minimize this effect, straining was practiced with the subject before the examination. Furthermore, only the MR image showing maximal depressant effect was used for subsequent analysis.

Pubovaginal sling is a surgical method for treating stress urinary incontinence. The urethra is slung to the pubis by means of natural or synthetic materials in pubovaginal sling surgery. Correction of intrinsic sphincter deficiency, caused by increased laxity of the pelvic floor, has been aimed in this surgical procedure (24-31). Procedures to correct stress urinary incontinence are designed to restore the support of the urethrovesical junction and, in cases of intrinsic sphincteric dysfunction, improve the coaptation of the urethra. In addition to the traditional pubovaginal sling techniques, recently developed techniques like transobturator tape, Mycomesh-Plus, and tension-free vaginal tape are also used for the treatment of stress urinary incontinence. There are many studies in the literature that utilized these techniques and compared them (32-43).

In our study, the postoperative MRI findings were compared with the severity score of incontinence in patients treated with pubovaginal slings in which rectus abdominis fascia was used. A positive correlation was found between the severity score of incontinence and the mobility of the bladder neck and between the score and the degree of posterior urethrovesical angle ($r = 0.797$, $P = 0.000$; $r = 0.62$, $P = 0.000$, respectively). There was also a positive correlation between the severity score of incontinence

and the increase in posterior urethrovesical angle during Valsalva's maneuver ($r = 0.47$, $P = 0.02$).

The MRI examinations not being applied in a dynamic fashion with the patient in the upright position, the low magnetic field strength of the MRI system, and the absence of urodynamic evaluations and preoperative MRI findings of the patients were the major limitations of this study.

In conclusion, MRI is a fast, reliable, and non-invasive diagnostic method for the evaluation of bladder floor position, mobility of the bladder neck, and posterior urethrovesical angle in patients with stress urinary incontinence. It can play a major role in the postoperative follow up of stress urinary incontinence. MRI can also be used for the assessment of success in pubovaginal sling surgery.

References

- Fielding JR, Griffiths DJ, Versi E, Mulkern RV, Lee MLT, Jolesz FA. MR imaging of pelvic floor continence mechanisms in the supine and sitting positions. *AJR* 1998; 171: 1607-10.
- Yang A, Mostwin JL, Rosenheim NB, Zerhouni EA. Pelvic floor descent in women: dynamic evaluation with fast MR imaging and cinematic display. *Radiology* 1991; 179: 25-33.
- Wijma J, Potters AE, de Wolf BT, Tinga DJ, Arnoudse JG. Anatomical and functional changes in the lower urinary tract following spontaneous vaginal delivery. *BJOG* 2003; 110: 658-63.
- Sartori JB, Sartori MG, Baracat EC, de Lima GR, Girão MJ. Bladder neck mobility and functional evaluation of the pelvic floor in primiparae according to the type of delivery. *Clin Exp Obstet Gynecol* 2004; 31: 120-2.
- Baytur YB, Serter S, Tarhan S, Uyar Y, Inceboz U, Pabuscu Y. Pelvic floor function and anatomy after childbirth. *J Reprod Med* 2007; 52: 604-10.
- DeLancey JOL. Structural aspects of extrinsic continence mechanism. *Obstet Gynecol* 1988; 72: 296-301.
- Unterweger M, Marincek B, Gottstein-Aalame N, Debatin JF, Seifert B, Ochsenbein-Imhof N et al. Ultrafast MR imaging of pelvic floor. *AJR* 2001; 176: 959-63.
- Pelsang RE, Bonney WW. Voiding cystourethrography in female stress incontinence. *AJR* 1996; 166: 561-5.
- Huddleston HT, Dunnihoo DR, Huddleston PM, Meyers PC. Magnetic resonance imaging of defect in DeLancey's vaginal support levels, I, II and III. *Am J Obstet Gynecol* 1995; 172: 1778-84.
- Lienemann A, Anthuber C, Baron A, Kohz C, Reiser M. Dynamic MR colpocystorectography assessing pelvic-floor descent. *Eur Radiol* 1997; 7: 1309-17.
- Schaer GN, Koechli OR, Schuessler B, Haller U. Perineal ultrasound for evaluating the bladder neck in urinary stress incontinence. *Obstet Gynecol* 1995; 85: 220-4.
- Giordano P, Drew PJ, Taylor D, Duthie G, Lee PW, Monson JR. Vaginography: investigation of choice for clinically suspected vaginal fistulas. *Dis Colon Rectum* 1996; 39: 568-72.
- Seifert H, Blass G, Leetz HK. Zur bestimmung der ovarialdosis bei der defakographie an einem digitalen c-bogen. *Rofo Fortschr Rontgen* 1994; 161: 70-4.
- Huang WC, Yang SH, Yang JM. Anatomical and functional significance of urogenital hiatus in primary urodynamic stress incontinence. *Ultrasound Obstet Gynecol* 2006; 27: 71-7.
- Balmforth JR, Mantle J, Bidmead J, Cardozo L. A prospective observational trial of pelvic floor muscle training for female stress urinary incontinence. *BJU Int* 2006; 98: 811-7.
- Comiter CV, Vasavada SP, Barbaric ZL, Gousse AE, Raz S. Grading pelvic prolapse and pelvic floor relaxation using dynamic magnetic resonance imaging. *Urology* 1999; 54: 454-7.
- Barrington JW, Abdel-Fattah M, Arunkalaivanan AS, Austin S, Isaacs J. Longitudinal study of pelviccol pubovaginal slings using magnetic resonance imaging. *J Obstet Gynaecol* 2004; 24: 542-6.
- Guffler H, Ohde A, Grau G, Grossmann A. Colpocystoproctography in the upright and supine positions correlated with dynamic MRI of the pelvic floor. *Eur J Radiol* 2004; 51: 41-7.
- Guffer H, Laubenberger J, DeGregorio G, Dohnicht S, Langer M. Pelvic floor descent: dynamic MR imaging using a half-fourier RARE sequence. *J Magn Reson Imaging* 1999; 9: 378-83.
- Vanbeckevoort D, Van Hoe L, Oyen R, Ponette E, De Ridder D, Deprest J. Pelvic floor descent in females: comparative study of colpocystodefecography and dynamic fast MR imaging. *J Magn Reson Imaging* 1999; 9: 373-7.
- Goh V, Halligan S, Kaplan G, Heally J, Bartam C. Dynamic MR imaging of the pelvic floor in asymptomatic subjects. *AJR* 2000; 174: 661-6.
- Lienemann A, Fischer T. Functional imaging of the pelvic floor. *Eur J Radiol* 2003; 47: 117-22.
- Hsu Y, Summers A, Hussain HK, Guire KE, Delancey JO. Lovator plate angle in women with pelvic organ prolapsed compared to women with normal support using dynamic MR imaging. *Am J Obstet Gynecol* 2006; 194: 1427-33.

24. McGuire EJ, O'Connell HE. Surgical treatment of intrinsic urethral dysfunction: slings. *Urol Clin North Am* 1995; 22: 657-64.
25. Young SB, Howard AE, Illanes DS, Weber Lebrun EE, Hardy JR, Kambiss SM et al. Long-term efficacy of the pubovaginal Mersilene mesh sling. *Am J Obstet Gynecol* 2009; 201: 516.e1-7.
26. Noblett KL, Shen B, Lane FL. Lynx midurethral sling system: a 1-year prospective study on efficacy and safety. *Int Urogynecol J Pelvic Floor Dysfunct* 2008; 19: 1217-21.
27. Lee JH, Kim KH, Lee HW, Kim KH, Choi JS, Yoon SJ et al. Distal urethral polypropylene sling surgical management for urodynamic stress incontinence in Korean women. *Urol Int* 2009; 82: 191-5.
28. Pianezza ML, Joffe R, Chugh T, Radomski SB. Long-term patient satisfaction following cadaveric pubovaginal sling incontinence surgery using the UDI and IIQ-7 questionnaires. *Neurourol Urodyn* 2007; 26: 185-9.
29. Petros PE, Richardson PA. Midurethral tissue fixation system (TFS) sling for cure of stress incontinence—3 year results. *Int Urogynecol J Pelvic Floor Dysfunct* 2008; 19: 869-71.
30. Mitsui T, Tanaka H, Moriya K, Kakizaki H, Nonomura K. Clinical and urodynamic outcomes of pubovaginal sling procedure with autologous rectus fascia for stress urinary incontinence. *Int J Urol* 2007; 14: 1076-9.
31. Rodrigues FR, Marocolo Filho R, Marocolo RR, Paiva LC, Diaz FA, Ribeiro EC. Pubovaginal sling with a low-cost polypropylene mesh. *Int Braz J Urol* 2007; 33: 690-4.
32. Sharifiaghdas F, Mortazavi N. Tension-free vaginal tape and autologous rectus fascia pubovaginal sling for the treatment of urinary stress incontinence: a medium-term follow-up. *Med Princ Pract* 2008; 17: 209-14.
33. Jeon MJ, Jung HJ, Chung SM, Kim SK, Bai SW. Comparison of the treatment outcome of pubovaginal sling, tension-free vaginal tape, and transobturator tape for stress urinary incontinence with intrinsic sphincter deficiency. *Am J Obstet Gynecol* 2008; 199: 76.e1-4.
34. Liapis A, Bakas P, Creatsas G. Tension-free vaginal tape in the management of recurrent urodynamic stress incontinence after previous failed midurethral tape *Eur Urol* 2009; 55: 1450-5.
35. Cholhan HJ, Lotze PM. Urodynamic changes after tension-free sling procedures: Mycromesh-Plus vs TVT sling. *Int Urogynecol J Pelvic Floor Dysfunct* 2008; 19: 217-25.
36. Lo TS, Lee SJ. Simple sling resection and a second, intermediate polypropylene mesh for treatment of vaginal tape protrusion concurrent with recurrent urinary stress incontinence after TVT procedure. *J Obstet Gynaecol Res* 2007; 33: 739-42.
37. Zullo MA, Ruggiero A, Plotti F, Bellati F, Basile S, Mancini N et al. Anterior colporrhaphy plus inside-out tension-free vaginal tape for associated stress urinary incontinence and cystocele. *J Minim Invasive Gynecol* 2008; 15: 446-51.
38. Schierlitz L, Dwyer PL, Rosamilia A, Murray C, Thomas E, De Souza A et al. Effectiveness of tension-free vaginal tape compared with transobturator tape in women with stress urinary incontinence and intrinsic sphincter deficiency: a randomized controlled trial. *Obstet Gynecol* 2008; 112: 1253-61.
39. Sartori JP, Martins JA, Castro Rde A, Sartori MG, Girão MJ. Pubovaginal sling and tension-free vaginal tape for surgical treatment of stress urinary incontinence in women. *Rev Bras Ginecol Obstet* 2008; 30: 127-34.
40. Liapis A, Bakas P, Creatsas G. Long-term efficacy of tension-free vaginal tape in the management of stress urinary incontinence in women: efficacy at 5- and 7-year follow-up. *Int Urogynecol J Pelvic Floor Dysfunct* 2008; 19: 1509-12.
41. Lee JH, Yoon HJ, Lee SJ, Kim KH, Choi JS, Lee KW. Modified transobturator tape (canal transobturator tape) surgery for female stress urinary incontinence. *J Urol* 2009; 181: 2616-21.
42. Chene G, Amblard J, Tardieu AS, Escalona JR, Viallon A, Fatton B et al. Long-term results of tension-free vaginal tape (TVT) for the treatment of female urinary stress incontinence. *Eur J Obstet Gynecol Reprod Biol* 2007; 134: 87-94.
43. Güngördük K, Çelebi I, Ark C, Çelikkol O, Yıldırım G. Which type of mid-urethral sling procedure should be chosen for treatment of stress urinary incontinence with intrinsic sphincter deficiency? Tension-free vaginal tape or transobturator tape. *Acta Obstet Gynecol Scand* 2009; 88: 920-6.