

1-1-2010

Gastric volvulus due to diaphragmatic eventration and paraesophageal hernia

NURETTİN ÖZGÜR DOĞAN

GÖKHAN AKSEL

AHMET DEMİRCAN

AYFER KELEŞ

FİKRET BİLDİK

Follow this and additional works at: <https://journals.tubitak.gov.tr/medical>



Part of the [Medical Sciences Commons](#)

Recommended Citation

DOĞAN, NURETTİN ÖZGÜR; AKSEL, GÖKHAN; DEMİRCAN, AHMET; KELEŞ, AYFER; and BİLDİK, FİKRET (2010) "Gastric volvulus due to diaphragmatic eventration and paraesophageal hernia," *Turkish Journal of Medical Sciences*: Vol. 40: No. 5, Article 23. <https://doi.org/10.3906/sag-0904-39>
Available at: <https://journals.tubitak.gov.tr/medical/vol40/iss5/23>

This Article is brought to you for free and open access by TÜBİTAK Academic Journals. It has been accepted for inclusion in Turkish Journal of Medical Sciences by an authorized editor of TÜBİTAK Academic Journals. For more information, please contact academic.publications@tubitak.gov.tr.

Gastric volvulus due to diaphragmatic eventration and paraesophageal hernia

Nurettin Özgür DOĞAN, Gökhan AKSEL, Ahmet DEMİRCAN, Ayfer KELEŞ, Fikret BİLDİK

Abstract: Acute gastric volvulus occurs when the stomach or a part of it rotates more than 180 degrees. It is a potentially life-threatening entity and most cases of gastric volvulus occur in association with eventration of left hemidiaphragm or a hiatal hernia. Gastric volvulus is a rare condition and presents with nonspecific epigastric pain and vomiting, and therefore may be missed. Chest x-ray and CT can help the diagnosis. Emergent surgical approach is mandatory.

Two elderly patients admitted to ED with epigastric pain and intractable vomiting did not respond to the treatment and we were not able to pass nasogastric tube. We saw diaphragmatic eventration in their chest x-rays and ordered thoracoabdominal CT. CT revealed hiatal hernia and gastric volvulus in the first patient. In the second patient, there were gastric volvulus, moved colon into the mediastinum and dilatation of stomach. Both cases underwent emergent surgery and both of them were discharged healthy.

Acute gastric volvulus carries a mortality rate of 42–56%, secondary to gastric ischemia, perforation or necrosis. Emergency physicians should have suspicion about gastric volvulus when treating patients with abdominal pain and persistent vomiting. The threshold should be kept low for surgical consultations.

Key words: Vomiting, hiatal hernia, diaphragmatic eventration, gastric volvulus

Diyafragmatik eventrasyon ve paraözefageal herniye bağlı gastrik volvulus

Özet: Akut mide volvulusu, mide veya ona ait olan bir parçanın 180 dereceden daha fazla dönmesi sonucu oluşur. Bu, potansiyel olarak hayatı tehdit eden bir durumdur ve çoğu olguda sol hemidiyafram eventrasyonu ve hiatal herniye ile ilişkilidir. Nadir görülen mide volvulusu, özgül olmayan abdominal semptomlarla kendini gösterdiğinden kolaylıkla gözden kaçabilir. Göğüs radyografisi ve BT tanımı kolaylaştırır. Mutlak acil cerrahi girişim gereklidir.

İki yaşlı hasta acil servise epigastrik ağrı ve inatçı kusma yakınmalarıyla kabul edildi. Her iki hasta da uygulanan tedaviye cevap vermedi ve nazogastrik tüpü yutamadı. Göğüs radyografilerinde diyafragmatik eventrasyon görülmesi üzerine torakoabdominal BT istendi. İlk hastanın BT'sinde hiatal herni ve gastrik volvulus görüldü. İkinci hastanın BT'sinde ise gastrik volvulus, mediastene taşınmış kolon ve dilate mide izlendi. Her iki hasta da acil cerrahi alındılar ve sağlıklı olarak taburcu edildiler.

Akut gastrik volvulus; mide iskemisi, perforasyon ve nekroza ikincil olarak %42-56 arasında mortalite hızına sahiptir. Acil servis doktorları karın ağrısı ve inatçı kusması olan hastaları tedavi ederken, gastrik volvulustan şüphelenmelidirler. Cerrahi konsültasyonlar için eşik düşük tutulmalıdır.

Anahtar sözcükler: Kusma, hiatal herni, diyafragma eventrasyonu, mide volvulusu

Introduction

Gastric volvulus is a rare disease and it is defined as an acquired rotation of the stomach or parts there of more than 180 degree creating a closed loop obstruction. The incidence and prevalence is

Received: 30.04.2009 – Accepted: 08.03.2010

Department of Emergency Medicine, Faculty of Medicine, Gazi University, Ankara - TURKEY

Correspondence: Nurettin Özgür DOĞAN, Department of Emergency Medicine, Faculty of Medicine, Gazi University, Beşevler 06500, Ankara - TURKEY

E-mail: nurettinozgurdogan@gmail.com

unknown at this time, as many cases are chronic and intermittent and often go undiagnosed (1).

There are two types of gastric volvulus: organoaxial and mesenteroaxial. The most common type is organoaxial, in which the stomach rotates along the longitudinal axis and is associated with paraesophageal hernias. The mesenteroaxial type, in which the stomach rotates between the lesser and greater curvatures, is believed to be idiopathic, causing chronic symptoms (2). The presence of persistent vomiting and epigastric pain despite initial antiemetic treatment should trigger one to think of gastric volvulus, despite the patient appearing very stable and healthy.

Unless it stays in the back of the emergency physicians' mind, diagnosis of gastric volvulus, which can have significant morbidity and mortality associated with it, can be easily missed. Early radiological imaging with x-ray or computed tomography (CT) can facilitate the management of the patient.

We report two cases of acute gastric volvulus secondary to hiatal hernia and diaphragm eventration that presented with abdominal pain and intractable vomiting.

CASE 1

A 75 year-old female with a history of hypertension, goiter, atherosclerotic coronary artery disease and appendectomy presented to emergency department (ED) with complaints of nausea and vomiting. Physical examination showed some abdominal distention with mild diffuse tenderness but no rebound, guarding or melena. She couldn't tolerate the nasogastric tube. Complete blood count, renal and liver function tests, amylase level, ECG and arterial blood gases were unremarkable. There was only 10-15 leucocytes in urine microscopy. She was treated with intravenous ranitidine, metoclopramide and discharged home with oral ciprofloxacin and metoclopramide.

Two days later she presented to the ED with same complaints additionally with hematemesis. She couldn't take drugs because of oral intolerance. In addition, there was hypoxia in arterial blood gases.

She had a chest x-ray in her second visit and left hemidiaphragm eventration was observed (Figure 1). Lung abscess or hiatal hernia was considered and thoracoabdominal CT was ordered. CT revealed stomach volvulus and hiatal hernia (Figure 2).

An eusophagogastroduodenoscopy was obtained. It revealed rotation in stomach, three large herniation pockets in fundus, major curvatura and antrum of the stomach, secondary to the volvulus. However, no bleeding focus was seen. She was operated, volvulus was corrected and paraesophageal hernia was repaired. Finally, she was discharged home healthy.

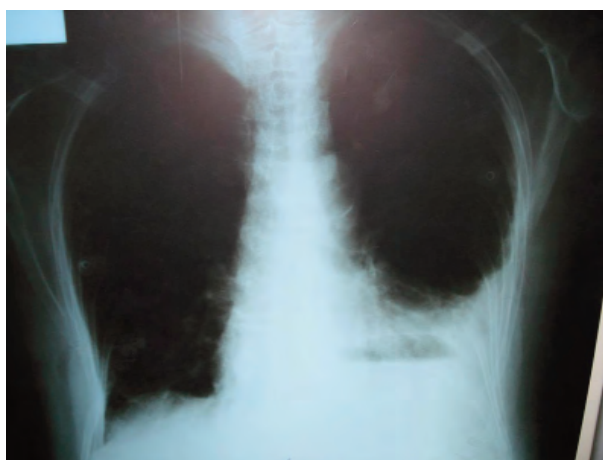

Figure 1. Chest x-ray of the first patient. Left hemidiaphragm eventration.

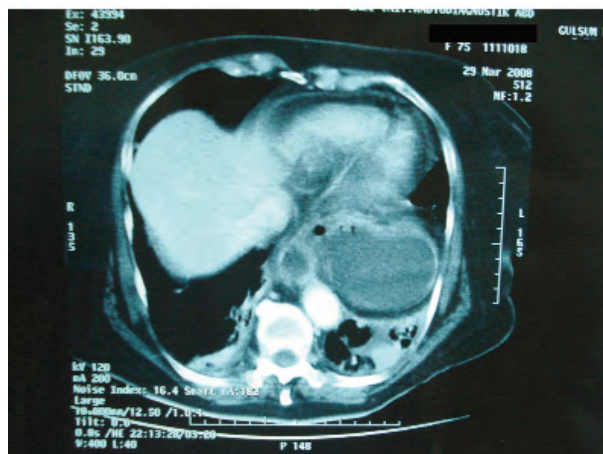


Figure 2. Thoracoabdominal CT scan of the first patient, which revealed gastric volvulus and hiatal hernia.

CASE 2

A 86 year-old female patient with a history of hypertension was admitted to ED with upper abdominal pain associated with intractable vomiting for two hours. She described her vomiting as “white foam”. Her complete blood count revealed leukocytosis with $21 \times 10^9/L$. Her ECG, amylase level, liver and renal function tests were in normal ranges.

A chest x-ray revealed the left hemidiaphragm eventration (Figure 3). Thoracoabdominal CT scan showed gastric volvulus, transvers colon which was moved to mediastinum, and dilatation of antrum and oesophagus. The patient was operated successfully; diaphragmatic repair, left hemicolectomy and colocolic anastomosis were performed as the surgical approach. She was discharged home healthy after a long hospital stay.

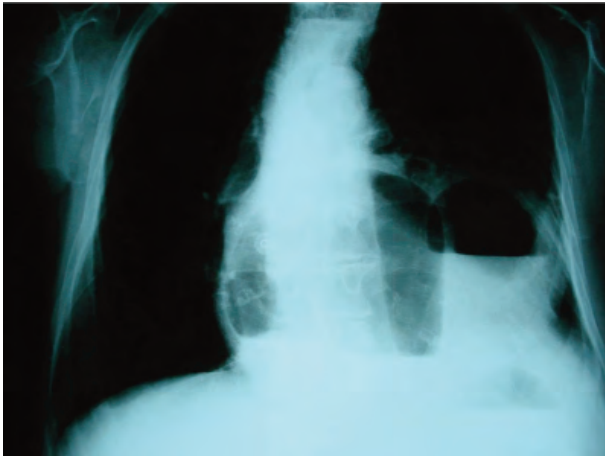


Figure 3. Chest x-ray of the second patient. Left hemidiaphragm eventration, colonic segments in mediastinum and gastric distention.

Discussion

Gastric volvulus is a potentially life-threatening entity and most cases of gastric volvulus occur in association with eventration of left hemidiaphragm or a hiatal hernia (3). Acute gastric volvulus carry a mortality rate of 42–56%, secondary to gastric ischemia, perforation or necrosis (4). Classically, Borchardt’s triad of vomiting, epigastric pain and an inability to pass a nasogastric tube should warn clinician to think of gastric volvulus as the primary

diagnosis. Borchardt’s triad has been reported to occur in 70% of cases (4).

In gastric volvulus, the etiology of the rotation is either primary or secondary. Primary refers to the absence of diaphragmatic defects or intra-abdominal abnormality causing the volvulus and also it may be seen in children with different ages (5). Laxity of the ligaments which anchors the stomach in place within the abdominal cavity, is a common cause. Lengthening of the ligaments due to stretching gives rise to abnormal rotation of the mesentery. In 30% of gastric volvuli, there is a primary cause. Secondary gastric volvulus have alternative causes, including congenital or traumatic diaphragmatic hernias, hiatal hernias, diaphragmatic eventration, abdominal bands or adhesions (4). Many cases occur with a paraesophageal hernia or diaphragmatic eventration like our patients.

Currently, CT can lead to an immediate diagnosis with all the anatomical details and confirm the diagnosis. As the literature reveals, the final diagnosis were setup by the great help of thoracoabdominal CT in our patients (6). Blood amylase levels in our patients were in normal ranges, but Wu et al found high amylase levels in their patient. Although rare, hematemesis with gastrointestinal bleeding may be the initial presentation or one of symptoms of acute gastric volvulus like our first patient (6).

Simple cases of diaphragmatic eventration may not require surgical intervention if it is not intruding significantly into the thoracic cavity and is not associated with adverse symptoms. However, symptomatic gastric volvulus associated with diaphragmatic eventration is a surgical emergency and always requires surgical repair (3). Similarly, paraesophageal hernia rarely causes severe complications like incarceration, volvulus, or strangulation, which are true emergencies in the ED. But a gastric volvulus leading to paraesophageal hernia can also present with nonspecific epigastralgia and anterior chest pain in the ED (7).

Treatment can be either surgical or medical in nature. Conservative management consists of endoscopic reduction or percutaneous endoscopic gastrostomy. The risk of gastric perforation is significant in conservative treatment. Therefore, patients should be considered carefully for conservative treatment. The gold standard is open

laparotomy with detorsion and revention with anterior gastropexy. Nissen fundoplication decreases future occurrences in patients with a hiatal hernia (8).

Gastric volvulus is an uncommon cause of upper abdominal pain and persistent vomiting. This diagnosis must be suspected in patients with documented paraesophageal hernia and diaphragma

eventration. The presence of persistent vomiting despite initial antiemetic treatment, continuing epigastric pain and inability to pass a nasogastric tube should trigger one to think of gastric volvulus. With the advent of CT and surgery, the gold standards for diagnosing and treating this disease are ever evolving.

References

1. Sevcik WE, Steiner IP. Acute gastric volvulus: case report and review of the literature. *CJEM* 1999; 1: 200-3.
2. Moy RK, Salazar AM, Chan SB. Inability to pass a nasogastric tube: a surgical emergency. *Am J Emerg Med* 2007; 25: 213-5.
3. Shah NN, Mohsin M, Khursheed SQ, Farooq SS, Buchh AA, Quraishi AQ. Eventration of diaphragm with gastric volvulus: a case report. *Cases J* 2008; 1: 404.
4. Chau B, Dufel S. Gastric volvulus. *Emerg Med J* 2007; 24: 446-7.
5. Andıran F, Tanyel FC, Balkancı F, Hiçsönmez A. Acute abdomen due to gastric volvulus: Diagnostic value of a single plain radiograph. *Pediatr Radiol* 1995; 25 Suppl 1: S240.
6. Wu MH, Chang YC, Wu CH, Kang SC, Kuan JT. Acute gastric volvulus: a rare but real surgical emergency. *Am J Emerg Med* 2010; 28: 118.e5-7.
7. Chang CC, Tseng CL, Chang YC. A surgical emergency due to an incarcerated paraesophageal hernia. *Am J Emerg Med* 2009; 27: 134.e1-3.
8. Machado NO, Rao BA. Gastric volvulus with identifiable cause in adults. Presentation and management. *Saudi Med J* 2004; 25: 2032-4.