

1-1-2010

Feminizing genitoplasty: an evaluation of 41 patients in 8 years

FATİH AKBIYIK

HÜSEYİN TUĞRUL TİRYAKİ

EMRAH ŞENEL

ERVİN MAMBET

YUSUF ZİYA LİVANELİOĞLU

See next page for additional authors

Follow this and additional works at: <https://journals.tubitak.gov.tr/medical>

 Part of the [Medical Sciences Commons](#)

Recommended Citation

AKBIYIK, FATİH; TİRYAKİ, HÜSEYİN TUĞRUL; ŞENEL, EMRAH; MAMBET, ERVİN; LİVANELİOĞLU, YUSUF ZİYA; and ATAYURT, HALİL FARUK (2010) "Feminizing genitoplasty: an evaluation of 41 patients in 8 years," *Turkish Journal of Medical Sciences*: Vol. 40: No. 5, Article 21. <https://doi.org/10.3906/sag-1002-653>

Available at: <https://journals.tubitak.gov.tr/medical/vol40/iss5/21>

This Article is brought to you for free and open access by TÜBİTAK Academic Journals. It has been accepted for inclusion in Turkish Journal of Medical Sciences by an authorized editor of TÜBİTAK Academic Journals. For more information, please contact academic.publications@tubitak.gov.tr.

Feminizing genitoplasty: an evaluation of 41 patients in 8 years

Authors

FATİH AKBIYIK, HÜSEYİN TUĞRUL TİRYAKİ, EMRAH ŞENEL, ERVİN MAMBET, YUSUF ZİYA LİVANELİOĞLU, and HALİL FARUK ATAYURT

Feminizing genitoplasty: an evaluation of 41 patients in 8 years

Fatih AKBIYIK, Tuğrul TİRYAKİ, Emrah ŞENEL, Ervin MAMBET, Ziya LİVANELİOĞLU, Halil ATAYURT

Aim: The authors present early results of feminizing genitoplasty procedures.

Materials and methods: Medical records of 41 patients who underwent feminizing genitoplasty in between 2001 and 2009 were evaluated retrospectively.

Results: Follow-up period was 1 month to 7.5 years. Clitorolabial cosmesis was good in all patients except one. Neither clitoral necrosis nor enlargement was noted in postoperative period. The most common complication observed was vaginal stenosis. For 7 patients with severe stenosis, reoperations are planned at puberty.

Conclusion: One-stage or staged genitoplasty is performed for disorders of sexual development (DSD) patients. Although results of clitoroplasty are satisfactory, reoperation rates due to vaginal stenosis in vaginal procedures is commonly reported. This study showed that staged genitoplasty for treatment may be the most prudent approach if patients do not have a low opening vagina.

Key words: Feminizing genitoplasty, children, congenital adrenal hyperplasia

Feminizan genitoplasti: Sekiz yılda 41 hastanın değerlendirilmesi

Amaç: Yazarlar feminizan genitoplasti işleminin erken sonuçlarını tarif etmektedirler.

Yöntem ve gereç: 2001-2009 yılları arasında feminizan genitoplasti yapılan 41 hastanın tıbbi kayıtları geriye dönük olarak incelenmiştir.

Bulgular: İzlem süresi 1 ay-7,5 yıl arasındadır. Klitorolabial kozmetik görünüm bir hasta dışında tüm hastalarda iyi idi. Postop dönemde klitoral nekroz veya klitoral büyüme ile karşılaşmamıştır. En yaygın komplikasyonun vajinal stenoz olduğu gözlenmiştir. Ciddi stenozu olan 7 hastaya, ergen döneminde yeniden operasyon planlanmıştır.

Sonuç: Seksüel gelişim bozukluklarında (SGB) tek seans ya da aşamalı genitoplasti operasyonları yapılır. Klitoroplasti sonuçları iyi olmasına rağmen, vajinal stenoz nedeni ile yeniden operasyon sıkça bildirilmiştir. Bu çalışma, hastanın alçak açılımlı vaginali olmadığı durumlarda, aşamalı genitoplastinin daha iyi bir seçim olduğunu işaret etmektedir.

Anahtar sözcükler: Feminizan genitoplasti, çocuklar, konjenital adrenal hiperplazi

Introduction

Congenital adrenal hyperplasia (CAH) leads to phenotypic changes due to excessive endogenous androgen production during fetal development in genetic females. Similar phenotypic changes have also been seen in cases where iatrogenic exposure to exogenous androgenic agents occurred during various stages of gestation (1). Intersex surgery can be challenging and difficult in these patients with variable outcomes for cosmesis and functional results. Gender preference in adulthood is typically female but cannot be assured. The purpose of this study is to evaluate early results of feminizing genitoplasty procedures.

Received: 02.03.2010 – Accepted: 01.06.2010

Department of Pediatric Surgery, Dışkapı Children's Hospital, Ankara - TURKEY

Correspondence: Fatih AKBIYIK, Department of Pediatric Surgery, Dışkapı Children's Hospital, Ankara - TURKEY

E-mail: akbiyik@isbank.net.tr

Material and methods

Medical records of the patients who underwent feminizing genitoplasty after the decision of an intersex committee between 2001 and 2009 were evaluated retrospectively and age, diagnosis, preoperative radiological evaluations, surgical procedures, complications, and cosmetic results were noted.

Surgical technique: Clitoroplasty was performed by clitoral body excision preserving the neurovascular bundle with ventral clitoral glans reduction. In clitorolabioplasty, preputial flaps were also utilized to form the labia. In the single stage clitorolabiovaginoplasty procedure clitoroplasty, labioplasty, and vaginoplasty was performed, clitoroplasty was performed first. U-flap vaginoplasty was performed as introduced by Fortunoff (2). Urogenital sinus mobilization was utilized in patients who had proximal vaginal openings. At the end of the operation, packed Vaseline gauze was placed in to the vagina. Vaginal gauze dressing was removed on the second or third postoperative day. A urinary catheter placed during the operation was kept for 5 days. Patients were discharged on the 7th postoperative day.

On the 15th postoperative day, all patients were examined and calibrated under general anesthesia. Later, in the following 3 years, calibration-dilatation programs were scheduled for patients with vaginoplasty. Dilatation was performed in patients with stenosis daily, once in 2 days or 3 times in a week and continued for 3 to 6 months based on the need of the patient personally and ended if stenosis healed or showed resistance. The calibration-dilatation procedures were abandoned in the last 5 years.

For 11 of the patients who underwent clitorolabioplasty, vaginoplasty was planned to perform as the second part of the two-staged operation when they reach puberty (Figures 1a-d).

Colovaginoplasty was performed using sigmoid colon in 1 patient.

Results

In our center 41 patients underwent feminizing genitoplasty between April 2001 and April 2009. Ages of patients at the time of surgery were between 1 and

10 years (mean 4 years). Primary diagnosis was congenital adrenal hyperplasia due to 21-hydroxylase deficiency in all except one patient who was exposed to androgenic medication during the prenatal period, and later diagnosed as mixed gonadal dysgenesis.

Ultrasonography (n = 41) and MRI (n = 6) were used to demonstrate female internal genitalia in all patients. Preoperative urogenital sinogram and/or cystoscopy were performed routinely. Surgical procedures included; one stage clitorovaginoplasty in 29 patients, clitorolabioplasty in 8, clitoroplasty in 3, and colovaginoplasty in 1 patient. U-flap vaginoplasty was performed in 25 patients as introduced by Fortunoff (mean 4,5 years old). Urogenital sinus mobilization was utilized in 4 (mean 5 years old) patients who had proximal vaginal openings.

Follow-up period was 1 month to 7.5 years. There were no serious intraoperative, surgical, or endocrinological complications. Clitorolabial cosmesis was good in all patients except one who needed minor labial reconstruction. Neither clitoral necrosis nor clitoral enlargement was noted in later postoperative evaluations.

Flap necrosis was not encountered in any of patients with vaginoplasty. The most common complication noted was vaginal stenosis even with a dilatation program. Dilatation duration was 6-12 months postoperatively. Sixteen patients had good vaginal calibrations and are on yearly follow up. Vaginal stenosis occurred in 14 patients. For 7 patients with severe stenosis, reoperations were planned at puberty (Figures 2a, b).

Discussion

The 2 main steps in planning for the care of intersex patients are gender assessment and surgical treatment. Controversies on gender determination have intensified recently (3,4). On this issue, the decision of the surgical team and ethical committee must be precise and patient oriented (5).

Technical advances in intersex surgery have been well documented (6). Nevertheless, intersex surgery can be challenging, and, even when well done, may not match gender preferences as the child reaches adulthood.

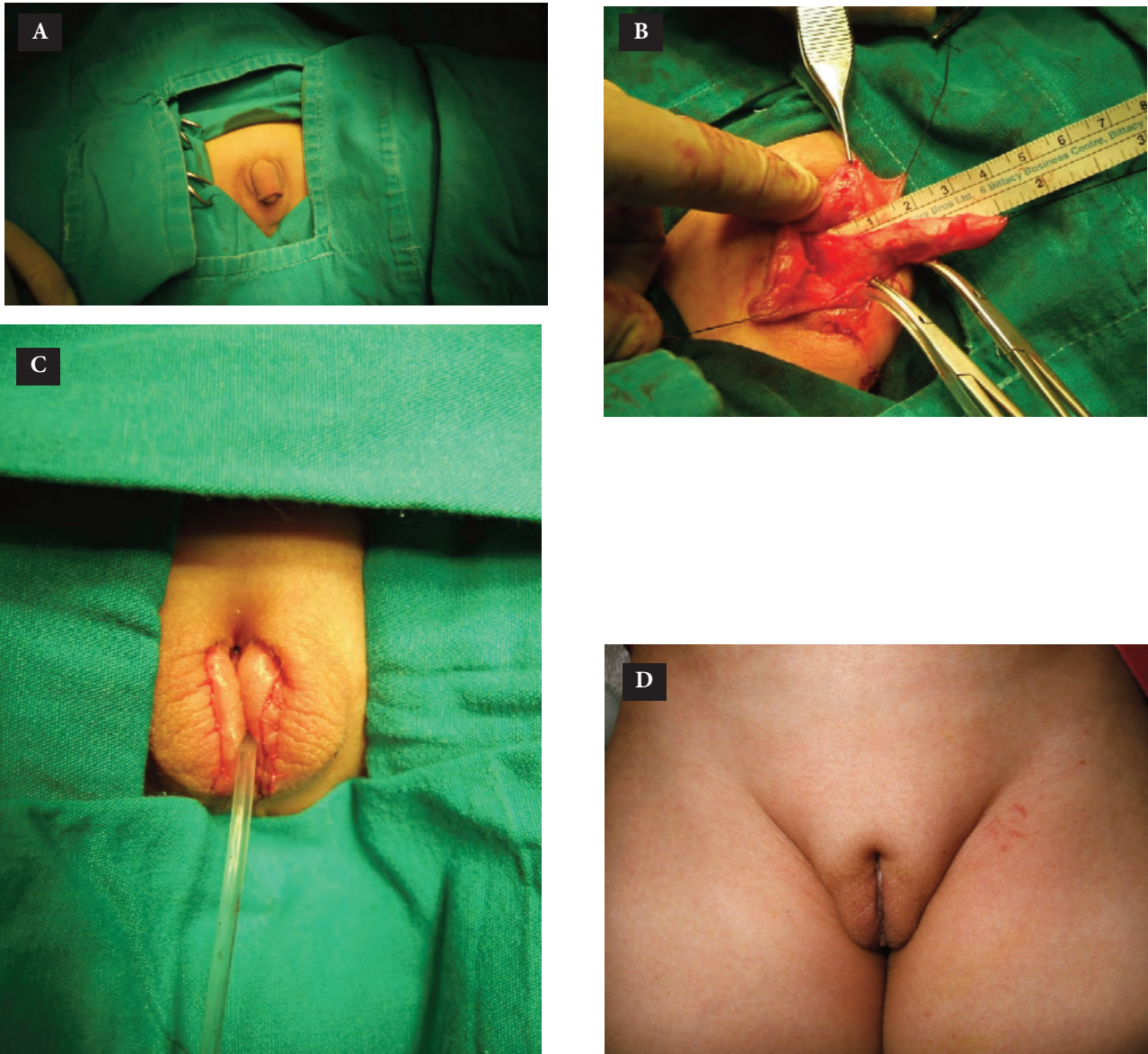


Figure 1. Images of preoperative, operative, and post-operative 7th day of patient with clitorolabioplasty.

Timing for vaginoplasty procedures has been widely discussed. Consensus has not completely reached on performing vaginoplasty in the first months of the life or at puberty (due to estrogen activity). Estrogen exposure, which occurs in the first months of life due to maternal estrogens (5,7) and after puberty, provides a better vascularized skin quality. The vaginal tissue, in this situation, is claimed to have a thicker wall, which is easy to handle (5). It was previously reported that neonatal vaginoplasty is easy to perform and results are good. Long term

evaluation and results neither for neonatal surgery nor (7-9) for single stage procedures, such as urogenital sinus mobilization, are available (9). Single or staged feminizing genitoplasty begins by clitoroplasty in all conditions. Recent reports on clitoris anatomy have highlighted refinement of the clitoroplasty procedure (10,11). The results of clitoroplasty are more satisfactory than the vaginal procedures (12,16). As an example, the study of Aliazzi et al. found that the anatomical outcomes were 46% unsatisfactory for the clitoris and unsatisfactory

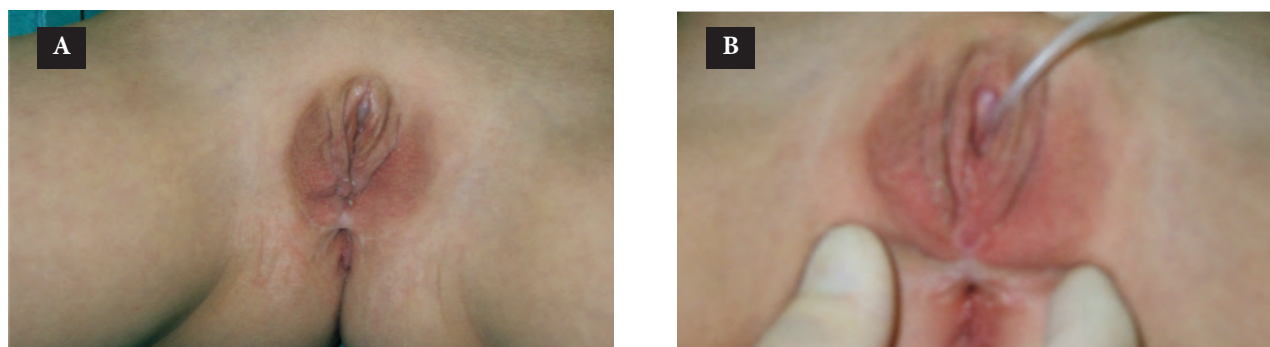


Figure 2. Images of severe vaginal stenosis of patient with single stage vaginoplasty.

results in vaginoplasty were 93% (12) (Table 1). Coran et al. stated that perineal vaginoplasty can be performed in the newborn period if the communication between the vagina and the urethra is distal to the external sphincter of the urethra. If communication is at or proximal to the sphincter, as in some cases of the CAH, a vaginal pull-through is a more appropriate operation. This procedure is generally performed during childhood when the child is bigger so as to decrease the incidence of postoperative vaginal stenosis (13). Surgery in infancy should be aimed principally at creating the appearance of normal external female genitalia, to alleviate parental distress and to avoid the potential psychological sequel of incorrect virilization in girls with CAH (12). It is logical to exteriorize the vagina in the presence of a low vagina and short urogenital sinus. We now believe that it may be prudent to defer definitive vaginoplasty until puberty. An advantage of deferring vaginoplasty until puberty is the availability of supple, genital skin which provides more robust and amenable flap formation than the genital and introital skin of infants (11).

Table 1. Postoperative evaluation of clitoroplasty.

	Number of Patients	Satisfactory Appearances %
Alizai et al. (12)	14	54
Creighton et al. (16)	44	59
Stikkelbroeck et al. (9)	8	63
Al Bassam et al. (20)	50	78
Miranda et al. (14)	43	100
Akbiyik et al.	41	100

Vaginal stenosis is the most commonly reported complication occurring in up to 78% of the cases (14). Vaginal stenosis after early vaginoplasty may be related to technical errors and poor understanding of anatomy, vascular causes, stretching of skin flaps, inflammation and infection, and estrogenic changes which may be an age dependent factor (5). Passerini-Glazel has suggested that if stenosis occurs, periodic dilatation should be avoided and surgical revision after puberty should be performed. In this way, the psychological trauma of an invasive maneuver will be avoided, and the patient and parents will benefit from the advantage of a more normal appearance of external genitalia (5). Powell et al. noted that repeated mechanical dilatation of a strictured anastomosis is almost always unsuccessful (15).

In our experience, compliance to a dilatation program was not successful for many of our patients and their families. The most common cause of ending the dilatation program in our series appears to be satisfaction with success of the cosmetic result of the surgery by their families (especially for very young patients). Dilatation procedures were also abandoned due to apparent psychological trauma of patients (and parents) and simple lack of compliance by parents. Cosmetic results of the surgery seem to be most important for family satisfaction. This has also been suggested by other authors (14) (Figures 1a-1d).

Difficulties and trauma of patients during dilatation and lack of compliance to dilatation procedures have lead us to prefer staged feminizing genitoplasty. Redo vaginoplasty after single-stage operations have been reported 45% to 86% successful (9,14,16,20) (Table 2). Alizai et al. reported the

Table 2 . Postoperative evaluation of vaginoplasty.

Study	Number of Patients	Need for Second Surgery %
Alizai et al. (12)	13	100
Creighton et al. (16)	44	75
Stikkelbroeck et al. (9)	8	87
Bailez et al. (17)	28	79
Krege et al. (19)	20	45
Farkas et al. (18)	49	0
Miranda et al. (14)	43	0
Al Bassam et al. (20)	43	15
Akbiyik et al.	29	17

requirement of revision as 100% (only one patient in their study did not need vaginal surgery) (12). Although severe vaginal stenosis was the only reason for re-vaginoplasty in our patients, cosmetic

problems, vaginal stricture, persistent urogenital sinus were reported as re-vaginoplasty reasons in other studies (9,12,16,20). These poor results have raised concern about single-stage procedures, leading to modifications of the operative approaches and delay of the vaginoplasty until puberty (9). Several researchers think that single stage surgery inevitably leads to reoperations in puberty (9,21). The British Association of Pediatric Surgeons (BAPS) has recommended a delay in vaginoplasty until puberty for these patients (22). Although new techniques or modifications were reported in operations, it is too early to evaluate the long term results (23,24).

In conclusion, if patients do not meet the objective criteria of wide vaginal introitus, and/or ability to view the cervix with cystoscopy, and /or catheterization of vagina is not possible (such as in a high opening vagina), staged genitoplasty for treatment may be the most prudent approach.

References

1. Donahoe PK, Schnitzer JJ. Ambiguous Genitalia in the Newborn In: O'neil J Jr, Rowe I Marc, Grosfeld JL, Fonkalsrud EW, Coran AG , editors. Pediatric Surgery. St Luois: Mosby Year Book; 1998; p. 1797-1817.
2. Fortunoff S, Lattimer JK, Edson M. Vaginoplasty technique for female pseudohermaphrodites. Surg Gynecol Obstet, 1964; 545-548.
3. Schober JM, Meyer-Bahlburg FL, Ransley PG . Self-assesment of genital anatomy, sexual sensitivity and function in women: implications for genitoplasty. BJU International 2004; 94: 589-594.
4. Schober JM. Sexual quality of life in an intersexual population: a needs assessment. BJU International 2004; 93: 54-56.
5. Passerini-Glazel G. Feminizing genitoplasty. Editorial J Urology 1999; 161: 1592-93.
6. Schober JM. Long-term outcomes and changing attitudes to intersexuality. BJU International 1999; 83 (Suppl 1) 1999: 39-50.
7. De Jong TPV, Boemers TML. Neonatal management of female intersex by clitorovaginoplasty. J Urology 1995; 154: 830-832.
8. Donahoe PK, Gustafson ML . Early One-stage surgical reconstruction of the extremely high vagina in patients with congenital adrenal hyperplasia. J Pediatr Surg 1994; 29: 352-358.
9. Stikkelbroeck NM, Beerendonk CC, Willemsen WN, Schreuders-Bais CA, Feitz WF, Rieu PN et al. The long term outcome of feminizing genital surgery for congenital adrenal hyperplasia: Anatomical, functional and cosmetic outcomes, psychosexual development, and satisfaction in adult female patients. J Pediatr Adolesc Gynecol 2003; 16: 289-296.
10. O'Connel HE, Sanjeevan KV, Hutson JM. Anatomy of the Clitoris. J Urology 2005; 174: 1189-1195.
11. Baskin LS. Anatomical studies of the female genitalia: surgical reconstructive implications. J Pediatr Endocrinol Metabolism 2004; 17: 581-587.
12. Alizai NK, Thomas DFM, Lilford RJ, Batchelor AGG, Johnson N Feminizing genitoplasty for congenital adrenal hyperplasia: what happens at puberty? J Urology 1999; 161: 1588-1591.
13. Coran AG, Polley TZ . Surgical management of ambiguous genitalia in the infant and child. J Pediatr Surg 1991; 26: 812-820.
14. Miranda ML, Oliveira-Filho AG, Lemos-Marini SH, Guerra G, Bustorff-Silvia JM. Labioscrotal island flap in feminizing genitoplasty. J Pediatric Surgery 2004; 39: 1030-1033.
15. Powell DM, Newman DK, Randolph J. A proposed classificatoin of vaginal anomalies and their surgical correction. J Pediatr Surgery 1995; 30: 271-276.
16. Creighton SM, Minto CL, Steele SJ. Objective cosmetic and anatomical outcomes at adolescence of feminisin surgery for ambiguous genitalia in childhood. Lancet 2001; 358: 124-125.

17. Bailez MM, Gearhart JP, Migeon C, Rock J. Vaginal reconstruction after initial construction of the external genitalia in girls with salt wasting adrenal hyperplasia J of Urology 1992; 148 : 148-680.
18. Farkas A, Chertin B, Hadas-Halpren I. 1-Stage feminizing genitoplasty: 8 years of experience with 49 cases. J Urology 2001;165: 2341-2346.
19. Krege S, Walz KH, Hauffa BP, Korner I, Rubben H. Long term follow-up of the female patient with congenital adrenal hyperplasia from 21-hydroxylase deficiency, with special emphasis on the results of vaginoplasty. BJU International 2000; 86: 253-258.
20. Al-Bassam A, Gado A. Feminizing genital reconstruction: Experience with 52 cases of ambiguous genitalia. Eur J Pediatr Surg 2004; 14: 172-178.
21. Ogilvie CM, Crouch NS, Rumsby G, Creighton SM, Liao LM, Conway SC Congenital adrenal hyperplasia in adults: a review of medical surgical and psychological Issues. Clinical Endocrinology 2006; 64: 2-11.
22. British Association of Paediatric Surgeons 2001. Statement of the British Association of Paediatric Surgeons Working Party on the surgical management of children born with ambiguous genitalia. www.baps.org.uk
23. Savanelli A, Alicchio F, Esposito C, De Marco M, Settini A. A modified approach for feminizing genitoplasty. World J Urol 2008; 26: 517-520.
24. Salle JLP, Braga LP, Macedo N, Rosito N, Bagli D Corporeal sparing dismembered clitoroplasty: An alternative technique for feminizing genitoplasty . J Urology 2007; 178: 1796-1801.