

1-1-2000

## Nonambulatory Tetraparesis Secondary to Cervical Vertebral Canal Stenosis in a Great Dane

ÖMER BEŞALTI

SAİT TONG

AHMET ÖZAK

FARUK AKIN

Follow this and additional works at: <https://journals.tubitak.gov.tr/veterinary>



Part of the [Animal Sciences Commons](#), and the [Veterinary Medicine Commons](#)

---

### Recommended Citation

BEŞALTI, ÖMER; TONG, SAİT; ÖZAK, AHMET; and AKIN, FARUK (2000) "Nonambulatory Tetraparesis Secondary to Cervical Vertebral Canal Stenosis in a Great Dane," *Turkish Journal of Veterinary & Animal Sciences*: Vol. 24: No. 2, Article 5. Available at: <https://journals.tubitak.gov.tr/veterinary/vol24/iss2/5>

This Article is brought to you for free and open access by TÜBİTAK Academic Journals. It has been accepted for inclusion in Turkish Journal of Veterinary & Animal Sciences by an authorized editor of TÜBİTAK Academic Journals. For more information, please contact [academic.publications@tubitak.gov.tr](mailto:academic.publications@tubitak.gov.tr).

## Nonambulatory Tetraparesis Secondary to Cervical Vertebral Canal Stenosis in a Great Dane

Ömer BEŞALTI, Sait TONG, Ahmet ÖZAK, Faruk AKIN

Department of Surgery, Faculty of Veterinary Medicine, University of Ankara, Ankara-TURKEY

Received: 09.03.1999

**Abstract:** A five-year-old male Great Dane was presented with nonambulatory tetraparesis and during the drip follow-up period its neurologic status became worse, despite conservative management for 10 days. Ligamentum flavum disease, dorsal bony compression and malformation of the articular process were diagnosed by magnetic resonance imaging (MRI). A dorsal laminectomy was performed. Physiotherapy, including massage, flexion and extension of the limbs, was done twice a day. Voluntary standing and walking were observed during the fourth week after the operation. From a telephone conversation with the owner it was determined that there was no problem in standing up and trotting in the 6<sup>th</sup> month after the operation.

**Key Words:** Caudal Cervical Spondylomyelopathy, Ligamentum Flavum Disease, Dorsal Laminectomy, Magnetic Resonance Imaging (MRI), Dog.

### Great Dane Irkı Bir Köpekte Servikal Kanalis Vertebralis Stenozuna Bağlı Nonambulatorik Tetraparezis

**Özet:** On gün süresince uygulanan medikal sađaltıma karşı nörolojik durumu giderek kötüleşen tetraparezisli, beş yaşlı, erkek, Great Dane ırkı bir köpek konu edildi. Manyetik rezonans görüntüleme (MRI) ile; ligamentum flavum hastalığı, dorsal kemik kompresyonu ve processus articulariste malformasyon tanısı kondu. Dorsal laminektomi uygulandı. Postoperatif dönemde fizik tedavi olarak günde iki defa arka bacaklarda fleksiyon, ekstensiyon hareketleri yaptırıldı. Köpeğin postoperatif dördüncü haftada yardım olmaksızın ayakta durup, yürüyebildiği gözlemlendi. Operasyondan 6 ay sonra hayvan sahibinden alınan bilgiye göre hayvanın ayakta durmasında ve koşmasında herhangi bir problemin olmadığı belirlendi.

**Anahtar Sözcükler:** Kaudal Servikal Spondilomyelopati, Ligamentum Flavum Hastalığı, Dorsal Laminektomi, Manyetik Rezonans Görüntüleme (MRI), Köpek.

### Introduction

Caudal cervical spondylomyelopathy (CCSM) appears to be a problem found in growing Great Danes and elderly Doberman Pinschers. The disease can be classified into five syndromes based on the location of the compressive lesions: congenital osseous malformation, cervical vertebral instability/chronic degenerative disc disease, vertebral tipping, ligamentum flavum disease or vertebral arch malformation and hourglass compression (1). The C<sub>4</sub>-C<sub>6</sub> intervertebral area is affected by the lesion, having a static or dynamic compressive effect on the spinal cord and nerve root (2).

The diagnosis of CCSM is a challenging process for veterinary surgeons. A differential diagnosis should be made precisely in order to identify the source of the symptoms, to determine whether they arise from soft

tissue compression or adjacent vertebral body lesions. In addition, the characteristic nature of the lesions, dynamic or static, should also be examined (3, 4, 5). Myelography is particularly useful in identifying herniated discs, compression of the spinal cord and tumors and vascular malformations of the spinal cord. However, MRI is rapidly replacing myelograms in the diagnosis of many human diseases due to its wider safe imaging. However, in veterinary medicine it is a new and uncommon technique because of its high cost and the limited availability and access to existing facilities. The canine spine has been assessed using MRI in some departments (6). CCSM can be treated with medical or surgical management which includes decompression or a combination of decompression and stabilization of the spinal column. In static lesions, according to the site of compression, dorsal laminectomy or disc fenestration and ventral

slotting methods are applied. It should be kept in mind that the prognosis of the disease is poor for severely tetraparetic dogs (1, 4).

The aim of this study was to report the of diagnosis by MRI and surgical treatment of nonambulatory tetraparesis secondary to cervical vertebral canal stenosis.

## Materials and Methods

A five-year-old male Great Dane was referred to the Department of Surgery, Faculty of Veterinary Medicine, University of Ankara, with a history of nonambulatory tetraparesis and unsuccessful conservative management. There was no history of trauma or medical illness. According to the referral center, progressive ataxia of the pelvic limbs had been noticed two weeks previously. The dog was found lying in its cage, and was not able to stand up. It was reported by the referral center that the neurologic condition of the dog was deteriorating despite the application of corticosteroid, analgesics and cage confinement.

The dog was evaluated for systemic disease by electrocardiography, urine, blood and cerebrospinal fluid analysis. Magnetic resonance imaging was performed and cervical vertebral canal stenosis was diagnosed.

After premedication with propionyl promazine, (Combelen - Bayer), anesthesia was induced with Thiopentone sodium (Pentothal sodium - Abott) and maintained by halothane. After 15 mg/Kg Methyl prednisolone (Prednol L - Mustafa Nevzat) and 25 mg/Kg Cefizoxime sodium (cefizox - Eczacıbaşı) had been injected intravenously, ringer lactate solution containing 15 mg/Kg methylprednisolone (Ringesol - Vilsan) was infused during the operation. A dorsal laminectomy was carried out in the C<sub>5</sub>-C<sub>6</sub> region and a fat graft was implanted into the laminectomy defect. The wound was closed according to routine methods.

The cervical area and cranial thorax were dressed, reinforced with PVC (Polyvinylchloride). Methylprednisolone (15 mg/Kg 2 bid for 3 days), cephalosporin, and B complex vitamins were administered for 7 days. Urination and defecation were managed by external compression of the bladder, catheterisation and enamel application. On the 10<sup>th</sup> day, in addition to voluntary urination and defecation, a slight neurologic recovery was detected. Physiotherapy, including massage, flexion and extension of the limbs, was done twice a day. In the second week, electrical stimulation was applied and a cart designed for tetraplegic dogs to stand in was used.

The follow-up period was 6 months, involving physical examination on an outpatient basis.

## Results

After physical and neurological examinations had been carried out, it was confirmed that the dog could not raise its head. The perineal reflex was suppressed and no voluntary urination or defecation was possible. Atrophy of the scapular muscles, LMN (Lower Motor Neuron) deficits in the thoracic limbs and UMN (Upper Motor Neuron) deficits in the pelvic limb were determined. In addition, superficial pain perception was lost, though deep pain perception was intact. It was determined that the dorsal and ventral longitudinal ligament and annulus fibrosus of the intervertebral disc were intact in MRI. Moreover, it was observed that there was static compression of the ligamentum flavum and a bony proliferation at the cranial and caudal border of the lamina. The diarthroidal joint of C<sub>5</sub>-C<sub>6</sub> appeared asymmetric in nature (Figures 1, 2).

The dorsal lamina of C<sub>5</sub> and C<sub>6</sub> was exposed and a hypertrophied ligamentous structure was observed. The ligamentum flavum was removed and the dorsal laminectomy was completed for half of each vertebra and a limited approach was made on both sides of the articular process. The remainder of the ligamentous structure, which was firmly adhered to the dura mater, was removed with Metzenbaum scissors. The lateral surface of the pedicle was excavated with a high-speed air drill and free nerve roots were observed. The bone proliferation of the diarthroidal joints was removed and curretted. The procedures were completed without evidence of any avulsion of the joints or any other complications.

In the 3<sup>rd</sup> week, the dog could sit in a prone position by itself and it made attempts to stand on its thoracic limbs. In the 4<sup>th</sup> week, the dog could stand up and walk but there was ataxia in the rear limbs. From a telephone conversation with the owner it was determined that there was no problem in standing up and trotting in the 6<sup>th</sup> month after operation.

## Discussion

In general, CCSM is first noticed by the owner with the presence of ataxia, weakness of the hind limbs and neck discomfort (7). A single lesion in the caudal cervical area is known to have a good prognosis, but when there are single caudal cervical area lesions associated with

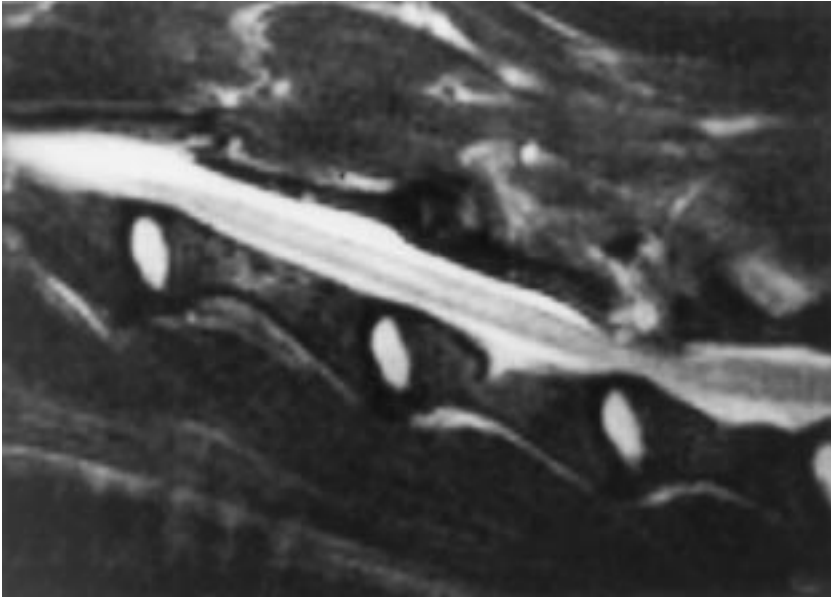


Figure 1. Vertebral canal stenosis in C<sub>5</sub>-C<sub>6</sub> and compressive effect of ligamentum flavum in midsagittal sections of MRI.

multiple lesions the prognosis is poor (2). A single lesion associated with a nonambulatory case was operated on with a successful outcome. In this case, clinical signs were observed gradually, but nonambulatory tetraparesis was observed suddenly and the neurological situation deteriorated with time despite conservative management.

The diagnosis of CCSM, which can result from many different etiological factors, is essential for determination of the operative technique to be used. Therefore, stress myelography and computed tomography myelography were used as the main diagnostic methods. Recently, MRI has been accepted as the most helpful method for diagnosis of this syndrome but its use is limited in veterinary medicine (6, 8). It has been confirmed that MRI is the best method for diagnosis of CCSM, because it allows for the differentiation of specific pathological changes of the brain, spinal cord and intervertebral disc.

The cause of ligamentous hypertrophy is thought to be instability or chronic degenerative disc disease at the affected sites (9). In our case, instability of the cervical vertebral column was not detected even though ligamentous hypertrophy was present.

Dorsal laminectomies and articular process fusions have been performed in humans but have often failed in dogs because of insufficient bone thickness and fracture of articular facets (4). Dorsal laminar elevation and stabilization of the articular process with a cancellous screw are performed for vertebral canal stenosis in the dog (10). A dorsal laminectomy was planned for the slightly affected diarthroidal joint in the present case. The

postoperative recovery period was 4 weeks, after which standing up, walking and voluntary urination and defecation occurred. The dog did not have any neurological problems in the succeeding month. The authors hope that this report of the diagnosis of ligamentum flavum disease, bone thickness at the borders of the lamina using MRI, surgical treatment and some findings in the recovery period in a 5-year-old dog may be useful as a guide to future treatment.

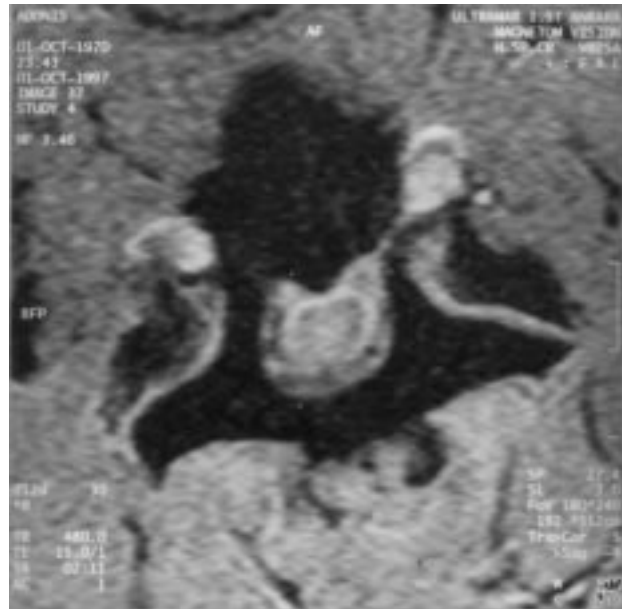

Figure 2. Degenerative appearance of articular process in transverse sections of MRI.

## References

1. Bruecker, K.A. & Seim III, H.C. Caudal Cervical Spondylomyelopathy. In Slatter D. Textbook of Small Animal Surgery 2<sup>nd</sup> ed. Vol 1 Philadelphia, W.B. Saunders Company,p.1056 1993.
2. Wheeler,S.J. and Sharp, N.H.J. Small Animal Spinal Disorders Diagnosis and Surgery, London Mosby – Wolfe 1994.
3. Parker, A.J., Park, R.D., Cusick, P.K., Small, E. Jeffers, C.B.: Cervical Vertebral Instability in the Dog: JAVMA, 163, 1, 71 – 774,1973.
4. Ellison G.W., Seim, H.B. & Clemmons, R.M. Distracted Cervical Spinal Fusion for Management of Caudal Cervical Spondylomyelopathy in Large - Breed Dogs: JAVMA 193, 4, 447, 1988.
5. Trotter, E.J. de LaHunta, A. Geary, J.C. & Brasmer, T.H. Caudal Cervical Vertebral Malformation - Malarticulation in Great Danes and Doberman Pinschers. JAVMA 168, 10, 917, 1976.
6. Sande, R.D.: Radiography, Myelography, Computed Tomography and Magnetic Resonance Imaging of the Spine. Veterinary Clinics of North America Small Animal Practice 22,4, 811,1992.
7. Lincoln, J.D. Cervical Vertebral Malformation / malarticulation Syndrome in Large Dogs,Veterinary Clinics of North America Small Animal Practice 22, 4, 923, 1992.
8. Wheeler S.J. Surgical Conditions of the Canine Spine. Br. Vet. J. 142, 95 1986.
9. Seim III H.B. Caudocervical Spondylomyelopathy in Large - Breed Dogs. In Bojrab, M.J. Current Techniques in Small Animal Surgery 3. ed. Philadelphia, Lea & Febiger p.579, 1990.
10. McKEE, W.M. Dorsal Laminar Elevation as a Treatment for Cervical Vertebral Canal Stenosis in the Dog. J. Small Anim. Pract. 29, 95, 1988.