

1-1-2011

Comparison of growth factor levels in patients with normal and hypospadiac prepuce*

TUTKU SOYER

EBRU ŞEBNEM AYVA

PINAR ATASOY

MUSTAFA KEMAL ASLAN

AHMET MURAT ÇAKMAK

Follow this and additional works at: <https://journals.tubitak.gov.tr/medical>



Part of the [Medical Sciences Commons](#)

Recommended Citation

SOYER, TUTKU; AYVA, EBRU ŞEBNEM; ATASOY, PINAR; ASLAN, MUSTAFA KEMAL; and ÇAKMAK, AHMET MURAT (2011) "Comparison of growth factor levels in patients with normal and hypospadiac prepuce*," *Turkish Journal of Medical Sciences*: Vol. 41: No. 1, Article 11. <https://doi.org/10.3906/sag-1003-718>
Available at: <https://journals.tubitak.gov.tr/medical/vol41/iss1/11>

This Article is brought to you for free and open access by TÜBİTAK Academic Journals. It has been accepted for inclusion in Turkish Journal of Medical Sciences by an authorized editor of TÜBİTAK Academic Journals. For more information, please contact academic.publications@tubitak.gov.tr.

Comparison of growth factor levels in patients with normal and hypospadiac prepuce*

Tutku SOYER¹, Ebru Şebnem AYVA², Pınar ATASOY², Mustafa Kemal ASLAN¹, Ahmet Murat ÇAKMAK¹

Aim: To compare the growth factor levels in patients with normal and hypospadiac prepuce.

Materials and methods: Patients who underwent hypospadias repair were included in the study. The prepuce was excised after achieving successful hypospadias repair with satisfactory functional and cosmetic appearance. The patients who underwent preputial reconstructions and complicated repairs were excluded. The control group consists of boys without hypospadias. Elective circumcision was performed to have normal preputial samples. The VEGF levels, VEGF receptor (VEGFR) and TGF- β receptor (TGF- β -R) expressions were evaluated in preputial tissues by immunohistochemical analysis.

Results: Fifteen patients were included in each group. The mean age of patients with normal and hypospadiac prepuce was 4.33 ± 1.39 and 4.07 ± 1.58 , respectively ($P > 0.05$). Although VEGF, VEGFR, and TGF- β -R levels were decreased in hypospadiac prepuce, statistical significance was detected only in VEGF levels ($P < 0.05$, Mann-Whitney U test).

Conclusion: The decreased levels of VEGF obtained from patients with hypospadiac prepuce suggest a structural anomaly related with angiogenesis. This structural difference can be considered one of the factors causing impaired wound healing and recurrent complications after preputial reconstructions in hypospadias repair.

Key words: Hypospadias, prepuce, vascular endothelial growth factor, transforming growth factor β

Normal ve hipospadiaslı hastaların prepisyumunda büyüme faktör seviyelerinin karşılaştırılması

Amaç: Normal ve hipospadiaslı hastaların prepisyumlarında büyüme faktör düzeylerini karşılaştırmak amacıyla ileriye dönük bir çalışma yapılmıştır.

Yöntem ve gereç: Çalışmaya hipospadias onarımı yapılmış olgular dahil edilmiştir. Prepisyumlar kozmetik ve fonksiyonel başarı elde edilen hipospadias onarımları sonrasında eksize edilmiştir. Prepisyal rekonstriksiyon yapılan ve komplikasyon gelişen olgular çalışma dışında tutulmuştur. Kontrol grubu hipospadiası olmayan olguları içermektedir. Prepisyum örnekleri elde edilmek üzere elektif sünnet yapılmıştır. Prepisyum örneklerinde vasküler endotelial büyüme faktörü (VEGF), VEGF reseptörü ve transforme edici büyüme faktör-beta reseptör (TGF- β -R) düzeyleri immunohistokimyasal yöntemlerle incelenmiştir.

Bulgular: Her grupta 15 hasta olmak üzere çalışmaya toplam 30 hasta dahil edilmiştir. Olguların yaş ortalaması normal ve hipospadiaslı gruplarda sırasıyla $4,33 \pm 1,39$ yıl ve $4,07 \pm 1,58$ yıldır ($P > 0,05$). VEGF, VEGFR ve TGF- β -R düzeyleri hipospadias grubunda normal prepisyum grubuna oranla azalmış olmakla birlikte anlamlı fark yalnız VEGF düzeylerinde saptanmıştır ($P < 0,05$, Mann-Whitney U test).

Sonuç: Hipospadiaslı hastaların prepisyumlarından elde edilen örneklerde VEGF düzeylerinin kontrol grubuna oranla azalması, bu hastaların prepisyumunda anjiyogenezis ile ilgili yapısal bir bozukluğun varlığını düşündürmektedir. Hipospadiaslı hastalardaki bu yapısal farklılıklar, prepisyum ile yapılan hipospadias onarımları sonrasında karşılaşılan iyileşme sorunlarının ve tekrarlayan komplikasyonların nedenleri arasında yer alabileceğini düşündürmektedir.

Anahtar sözcükler: Hipospadias, prepisyum, vasküler endotelial büyüme faktörü, transforme edici büyüme faktör β

Received: 04.04.2010 - Accepted: 30.06.2010

¹ Department of Pediatric Surgery, Faculty of Medicine, Kırıkkale University, Kırıkkale - TURKEY

² Department of Pathology, Faculty of Medicine, Kırıkkale University, Kırıkkale - TURKEY

Correspondence: Tutku SOYER, Department of Pediatric Surgery, Faculty of Medicine, Kırıkkale University, Kırıkkale - TURKEY

E-mail: soyer.tutku@gmail.com

* This study was supported by Kırıkkale University Scientific Projects Unit and presented at the Joint Congress of British Association of Pediatric Surgeons and European Pediatric Surgery Association on 17-20 June 2009, in Graz, Austria.

Introduction

Numerous factors account for complicated hypospadias repair. Therefore, many attempts have been made to avoid these complications by improving the surgical technique, the suture material, and postoperative follow-up (1). The fact that operative complications such as meatal regression, stenosis, and fistula formation can develop despite all precautions indicates a structural alteration in children with hypospadias.

The prepuce is used to form a neo-urethra or reconstruct the penile shaft skin in hypospadias repair (2). It is also used extensively as a skin flap. The morphological, vascular, and sensorineural features of the prepuce have been investigated but the presence of growth factors that promote wound healing has not been evaluated (2-4).

Many growth factors have been determined in the process of wound healing (5). Vascular Endothelial Growth Factor (VEGF) plays a crucial role in the proliferation, migration, and differentiation of the endothelial cell (6). It mediates angiogenesis and enhances wound healing by promoting endothelial cell survival (7). TGF- β is a well-known growth factor, having potent effects on immune modulation, endothelial adhesiveness, extracellular matrix synthesis, and tissue repair (8). TGF- β is known as the strongest stimulant of collagen synthesis and plays a key role in wound contraction (9). It participates in remodeling as it is able to organize the matrix (10). Wound healing features are widely evaluated by the levels of VEGF, TGF- β , and their receptor expressions in most of the studies.

A prospective study was performed to compare the levels of VEGF, VEGF receptor (VEGFR), and TGF- β receptor (TGF- β -R) in the prepuce of normal subjects and hypospadias patients. This study was aimed to investigate the effect of structural features of prepuce on the wound healing process by growth factor levels.

Materials and methods

Two groups of patients including children with normal prepuce and hypospadias were included in the study. The normal prepuce group consisted of 15 patients who were admitted to our department for

elective circumcision without a history of phimosis or balanitis. The other cohort of 15 patients who had undergone successful hypospadias repair from the functional and cosmetic point of view was assessed as the hypospadias group. Patients who underwent urethral reconstruction with preputial flaps and were circumcised during the repair were excluded from the hypospadias group. The prepuce was obtained by circumcision 6 months after the repair in patients with hypospadias.

Surgical method

Preputial tissue was excised from the normal subjects and hypospadias patients under general anesthesia by using a classic circumcision method.

Histopathological and immunohistochemical evaluation

The material was sampled after 24 h of fixation in 10% formalin solution and went through routine histopathology processes. Blocks were prepared after embedding in paraffin. Sections 4-6 μ thick were prepared from these paraffin blocks and transferred to adhesive slides. The sections were treated with routine hematoxylin-eosin stain and immunohistochemical material such as CD105/Endoglin/Transforming growth factor β 1/3 receptor (LabVision; 1/50), Vascular endothelial growth factor (LabVision; 1/100), and VEGF receptor (LabVision; 1/100). Immunohistochemical staining was performed with streptavidin-biotin-peroxidase (UltraVision Polyvalent [rabbit-mouse]) with horseradish peroxidase kit as reported by Kaya et al. (11).

The immune staining results for these indicators were evaluated semi-quantitatively using the immunohistochemical histological scoring system (HSCORE). The distribution and density of the specific staining were reported together as the HSCORE. The HSCORE is formulated mathematically as follows: $HS = \sum(P_i \times i/100)$. P_i coefficient in the formula represents the number of cells that stained with a density of 1-3. Overall HSCORES ranged between 0 and 300.

Statistical analysis and ethics

Data obtained from histopathological and immunohistochemical evaluations were analyzed

with SPSS 15.0. The distribution between groups was analyzed with Kruskal Wallis test and the difference between the 2 groups was evaluated with Mann-Whitney U test. The P values lower than 0.05 were considered significant

The study was approved by Kırıkkale University Local Ethical Committee (2007/001, Dated 20.02.2007). Written informed consent was obtained from parents.

Results

The median age for the normal subjects and patients with hypospadiac prepuce were 4.33 ± 1.39 (2-6 years) and 4.07 ± 1.58 (2-6 years), respectively ($P > 0.05$). In the hypospadias group, urethral meatus levels were coronal ($n = 7$), glanular ($n = 3$), subcoronal ($n = 3$), and penile ($n = 2$). The techniques chosen for hypospadias repair were tubularized incised urethroplasty ($n = 10$) and MAGPI repair ($n = 5$).

The median HSCORE of VEGF, VEGFR, and TGF- β -R for the normal subjects and patients with hypospadiac prepuce are listed in the Table.

When the median levels of growth factors were compared, there was no significant difference detected between VEGF and TGF- β -R expressions ($P > 0.05$). However, VEGF levels were significantly decreased in patients with hypospadias ($P < 0.05$) (Table).

VEGF staining in submucosal vascular endothelium in normal prepuce is shown in Figure 1. Submucosal endothelium showed decreased VEGF staining in patients with hypospadias (Figure 2).

Discussion

The high complication rates of hypospadias repair remain a significant problem despite the development of improved surgical techniques, suture materials, and postoperative care. Therefore, structural alterations in

Table. The median HSCORE VEGF, VEGFR, and TGF- β -R in normal subjects and patients with hypospadias.

	VEGF		VEGFR		TGF- β -R	
	Normal	Hypospadias	Normal	Hypospadias	Normal	Hypospadias
1	108	52	15	0	23	18
2	73	25	0	0	27	0
3	135	0	43	15	35	53
4	0	19	67	25	61	36
5	61	78	59	61	33	62
6	52	74	0	32	40	80
7	0	0	0	10	25	0
8	150	0	20	0	10	0
9	71	17	24	0	60	0
10	105	20	5	0	0	26
11	0	68	16	4	27	12
12	33	0	18	32	20	22
13	49	0	8	0	45	11
14	127	0	0	11	73	0
15	95	7	0	0	21	19
Median	71 (33-108)	17 (0-52)	15 (0-24)	4 (0-25)	18 (0-36)	27 (21-45)
P value	P < 0.05*		P > 0.05		P > 0.05	

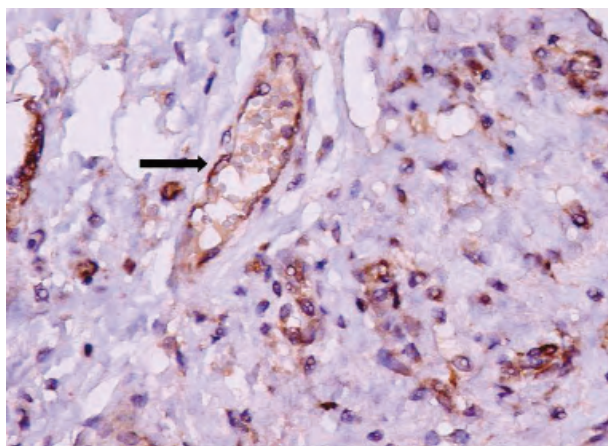


Figure 1. VEGF staining in submucosal vascular endothelium (arrow) in normal prepuce (DAB × 40).

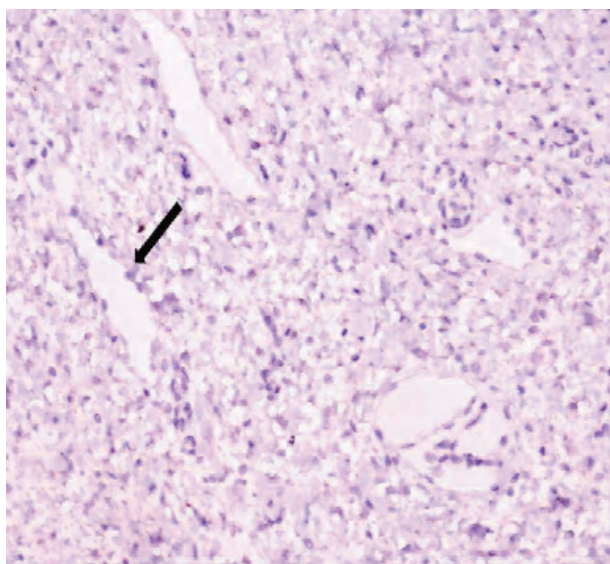


Figure 2. Decreased levels of VEGF staining in submucosal endothelium (arrow) in a patient with hypospadias (DAB × 20).

patients with hypospadias are held responsible for these complications. The prepuce is defective in most hypospadiac patients and is usually in the form of a partial prepuce that does not fully cover the glans penis (2). In hypospadias repair, skin flaps are prepared from the prepuce and used for urethral reconstruction (2). The development of complications such as meatal regression, stenosis, and fistula following these repairs has led to the investigation of the vascular, neural, and immunological features of the prepuce (2,4,12).

Vascular defects are known to be present in the prepuce in patients with hypospadias. Underdeveloped prepuces and those with unfavorable vascular pattern used for urethroplasty had higher percentages of complications (2). However, although morphologic and vascular features of hypospadiac prepuce are well documented, there is still a lack of detailed information on angiogenesis and wound healing in the preputial tissue. The epidermal growth factor (EGF) receptor measurements in the prepuce of children with hypospadias by El- Galley et al. have indicated a possible problem with wound healing in these patients (13). It has been suggested that decreased EGF levels can be considered a cause of altered wound healing in patients with hypospadias. Also investigations of other growth factors such as VEGF, VEGFR, and TGF- β -R are needed to elucidate the healing features of hypospadiac prepuce.

VEGF is an angiogenic peptide produced by endothelial cells, macrophages, and many other cells (14). It mediates angiogenesis and promotes endothelial cell survival (7). Hypoxia is the major stimulus for the release of VEGF in the acute wound setting (5). VEGF enhances angiogenesis to restore tissue perfusion, reestablish microcirculation, and increases oxygen at the wound site (5). Although VEGF and its receptor are expressed in various type of tissues, sections with poor angiogenetic activity may not express VEGF and its receptors. Therefore, some of the healthy subjects in our study showed no VEGF expression on immunohistochemical analysis. Since VEGF levels are decreased in chronic wounds, VEGF becomes a treatment alternative for some indications of chronic wounds. In the present study, we found decreased levels of VEGF in patients with hypospadias. However, receptor expression of VEGF was similar in groups, and decreased levels of VEGF indicate a possible altered vascular structure in patients with hypospadias. Therefore, we suggest that not only the vascular anatomy but also angiogenesis may be defective in hypospadiac prepuce. However, other angiogenetic features of hypospadiac prepuce need further evaluation to confirm our suggestion.

TGF- β is also a growth factor, having potent effects on immune modulation, endothelial adhesiveness, extracellular matrix synthesis, and tissue repair (8). It is shown to have increased expression with the onset

of injury (5). Furthermore, elevated TGF- β -R expression was reported as a response to ischemic injury (11). Similar to VEGF, TGF- β -R expression is also decreased in the chronic wound setting. In the present study, it was found that hypospadiac prepuce showed decreased TGF- β -R expression without a statistical difference when compared to normal prepuce.

According to the results of the present study, it can be speculated that decreased levels of VEGF in prepuce can be considered a sign of defective angiogenesis. Since we only evaluated the VEGF and TGF- β -R levels, it is difficult to draw a firm conclusion about the wound healing features of hypospadiac prepuce and its effects on complications. In addition, we think that not only the prepuce but also the glans and urethra should be evaluated for

growth factors in order to draw a conclusion about reduced angiogenesis in hypospadias.

In conclusion, the decreased levels of VEGF obtained from patients with hypospadiac prepuce suggest a structural anomaly related with angiogenesis. This structural difference can be considered one of the factors causing impaired wound healing and recurrent complications after preputial reconstructions in repairs.

Acknowledgement

This study was supported by Kırıkkale University Scientific Projects Unit and presented at the Joint Congress of British Association of Pediatric Surgeons and European Pediatric Surgery Association on 17-20 June 2009, in Graz, Austria.

References

1. Hadidi AT. Fistula repair. In: Hadidi AT, Azmy AF. Hypospadias Surgery. 1st ed. Springer-Verlag, Heidelberg, Germany; 2004; pp: 277-282.
2. Radojicic ZI, Perovic SV. Classification of prepuce in hypospadias according to morphological abnormalities and their impact on hypospadias repair. *J Urol* 2004; 172: 301-304.
3. Coulam CB, Razel AJ, Kellalis PP, Svensson J, Spelsberg TC. Androgen receptor in human foreskin II. Characterization of the receptor in hypospadiac tissue. *Am J Obstet Gynecol* 1983; 147: 513-520.
4. Yücel S, Güntekin E, Kukul E, Karagüzel G, Çiftçiöğlü A, Melikoğlu M et al. Comparison of normal and hypospadiac preputial vascular anatomy. *J Urol* 2004; 172: 1973-1976.
5. Barrientos S, Stojadinovic O, Golinko MS, Brem H, Tomic-Canic M. Growth factors and cytokines in wound healing. *Wound Repair Regen* 2008; 16: 585-601.
6. Fehrenbach A, Pufe T, Wittwer T, Nagib R, Dreyer N, Pech T et al. Reduced vascular endothelial growth factor correlates with alveolar epithelial damage after experimental ischemia and reperfusion. *J Heart Lung Transplant* 2003; 22: 967-978.
7. Leung DW, Cachianes G, Kuang WJ, Goeddel DV, Ferrara N. Vascular endothelial growth factor is secreted angiogenic mitogen. *Science* 1989; 246: 1306-1309.
8. O'Kane S, Ferguson MW. Transforming growth factor β and wound healing. *Int J Biochem Cell Bio* 1997; 23: 63-78.
9. Falaga V, Qian SW, Danielpour P. Hypoxia up-regulates the synthesis of TGF β 1 by human dermal fibroblasts. *J Invest Dermatol* 1991; 97: 634-637.
10. Wu L, Xia YP, Roth SI, Gruskin E, Mustoe TA. Animal Model, Transforming growth factor β 1 fails to stimulate wound healing and impairs its signal transduction 13 in an aged ischemic ulcer model: Importance of oxygen and age. *Am J of Pathol* 1999; 154: 301-309.
11. Kaya M, Soyer T, Ayva S, Çakmak M. Effect of penile tourniquet on growth factors in rat penile tissue. *Eur J Pediatr Surg* 2009; 19: 236-40.
12. Nazir Z, Masood R, Rehman R. Sensory innervation of normal and hypospadiac prepuce: possible implications in hypospadiology. *Pediatr Surg Int* 2004; 20: 623-627.
13. El Galley RE, Smith E, Cohen C, Petros JA, Woodard J, Galloway NT. Epidermal growth factor (EGF) and EGF receptor in hypospadias. *Br J Urol* 1997; 79: 116-119.
14. Ferrara N. VEGF: an update on biological and therapeutic aspects. *Curr Opin Biotechnol* 2000; 11: 617-624.