

1-1-2011

Efficacy of hyaluronic acid - carboxymethyl cellulose membrane (Seprafilm®) and polylactic acid barrier film (Surgiwrap™) for the prevention of adhesions after thyroid surgery: an experimental model

GÖKHAN ÇİPE

HAKAN MUSTAFA KÖKSAL

SADIK YILDIRIM

MUSTAFA FEVZİ CELAYİR

ADİL BAYKAN

Follow this and additional works at: <https://journals.tubitak.gov.tr/medical>

 Part of the [Medical Sciences Commons](#)

Recommended Citation

ÇİPE, GÖKHAN; KÖKSAL, HAKAN MUSTAFA; YILDIRIM, SADIK; CELAYİR, MUSTAFA FEVZİ; and BAYKAN, ADİL (2011) "Efficacy of hyaluronic acid - carboxymethyl cellulose membrane (Seprafilm®) and polylactic acid barrier film (Surgiwrap™) for the prevention of adhesions after thyroid surgery: an experimental model," *Turkish Journal of Medical Sciences*: Vol. 41: No. 1, Article 10. <https://doi.org/10.3906/sag-0911-400>

Available at: <https://journals.tubitak.gov.tr/medical/vol41/iss1/10>

This Article is brought to you for free and open access by TÜBİTAK Academic Journals. It has been accepted for inclusion in Turkish Journal of Medical Sciences by an authorized editor of TÜBİTAK Academic Journals. For more information, please contact academic.publications@tubitak.gov.tr.

Efficacy of hyaluronic acid - carboxymethyl cellulose membrane (Seprafilm®) and polylactic acid barrier film (Surgicwrap™) for the prevention of adhesions after thyroid surgery: an experimental model

Gökhan ÇİPE¹, Hakan Mustafa KÖKSAL², Sadık YILDIRIM², Mustafa Fevzi CELAYİR², Adil BAYKAN²

Aim: Adhesions occurring after initial surgery increase complications in secondary thyroid operations. Therefore use of anti-adhesive barriers may reduce complication rates of secondary thyroid operations. In this study, we investigated the efficacy of hyaluronic acid-carboxymethyl cellulose membrane (HA-CMC, Seprafilm®) and polylactic acid barrier film (PLA, Surgicwrap™) in reducing adhesions after thyroid surgery.

Materials and methods: A randomized-controlled experimental animal model was utilized. Forty-eight male Wistar Albino rats were randomly divided into 3 equal groups, forming study and control groups. Thyroid surgery was performed in all subjects. HA-CMC and PLA were applied between the thyroid zone and strap muscles after thyroid surgery in the HA-CMC and PLA study groups, respectively. Eight animals in each group were sacrificed and re-operated on day 7 and the rest on day 28. Two surgeons independently scored adhesion formation during the re-operation. Subsequently, thyroid and adjacent tissues were excised for histopathologic examination.

Results: Surgical adhesion scores were significantly reduced in HA-CMC group compared to the control group both on day 7 and 28 re-operations ($P = 0.005$ and $P = 0.001$, respectively); however, no significant difference was observed between control and PLA groups. Histopathologically, on day 7 re-operations, cellular markers of adhesion were more prominent in both HA-CMC and PLA groups compared to the control group; however, on day 28 re-operations, adhesion markers were similar in HA-CMC and control subjects, whereas PLA subjects still had marked adhesion.

Conclusion: Use of HA-CMC after primary thyroidectomy may reduce adhesion formation, and thereby the complication rate in secondary surgery. Similar studies are warranted to determine the clinical application of barrier agents in thyroid surgery.

Key words: Anti-adhesive barriers, thyroidectomy, adhesion

Tiroid cerrahisi sonrası oluşan yapışıklıkları önlemede hyaluronik asit - karboksimetil selülöz film (Seprafilm®) ve polilaktik asit bariyer filmin (Surgicwrap™) etkisi: Deneysel model

Amaç: İlk tiroid ameliyatlarından sonra oluşan yapışıklık ikincil tiroid ameliyatlarındaki komplikasyonları artırır. Bu nedenle yapışıklık önleyici bariyer kullanımı ikincil tiroid ameliyatlarındaki komplikasyon oranını azaltabilir. Bu çalışmada tiroid ameliyatları sonrası oluşan yapışıklıkları azaltmada hyalüronik asit-karboksimetil selülöz (HA-CMC, Seprafilm®) ve polilaktik asit bariyer filmin (PLA, Surgicwrap™) etkisi araştırılmıştır.

Yöntem ve gereç: Randomize-kontrollü deneysel hayvan modeli kullanıldı. Kırksekiz erkek Wistar Albino türü sıçan çalışma grupları ve kontrol grubu olarak 3 eşit gruba ayrıldı. Tüm deneklere tiroid cerrahisi uygulandı. Çalışma

Received: 16.01.2010 – Accepted: 21.05.2010

¹ Department of General Surgery, Faculty of Medicine, Bezmî Alem University, İstanbul - TURKEY

² Department of General Surgery, Şişli Etfal Research and Training Hospital, İstanbul - TURKEY

Correspondence: Gökhan ÇİPE, Gültepe Mahallesi 727. Cadde, C1.3 Blok D: 41, Altındağ, Ankara - TURKEY
E-mail: gokhancipe@hotmail.com

gruplarında HA-CMC ve PLA tiroid cerrahisinden sonra tiroid loju ile strap kasları arasına yerleştirildi. Her gruptan 8 denek 7. gün, kalan denekler 28. gün sakrifiye edildi. Reoperasyon esnasında iki cerrah ayrı ayrı yapışıklıkları skorladı. Bunu takiben tiroid, çevre dokularla beraber çıkarılarak histopatolojik inceleme yapıldı.

Bulgular: Cerrahi yapışıklık skoru kontrol grubuyla karşılaştırıldığında HA-CMC grubunda 7. ve 28. günde önemli oranda az bulunmuştur (7. gün $P = 0,005$ ve 28. gün $P = 0,001$). Kontrol grubuyla PLA grubu arasında ise anlamlı farklılık saptanmamıştır. Histopatolojik olarak 7. gündeki reoperasyonda hücresel yapışıklık belirteçleri çalışma gruplarında kontrol grubuna göre daha fazla saptanmıştır. 28. gündeki reoperasyonda ise HA-CMC ve kontrol grubunda benzer olup, PLA grubundan daha az bulunmuştur.

Sonuç: İlk tiroid ameliyatlarından sonra HA-CMC kullanılması, yapışıklık oluşumunu ve böylece ikincil ameliyatlarda oluşabilecek komplikasyon oranını azaltabilir. Tiroid cerrahisinde bariyer ajanların kullanımı benzer klinik çalışmalarla desteklenmelidir.

Anahtar sözcükler: Yapışıklık önleyici bariyerler, tiroidektomi, yapışıklık

Introduction

Recurrent laryngeal nerve (RLN) damage and hypoparathyroidism are 2 principal complications of thyroid surgery. They are 3 to 4 times more common in completion surgery than primary surgery with an incidence of 3%-13% and 1%-3% for RLN injury and hypoparathyroidism, respectively (1-4). To overcome that drawback of completion thyroidectomy, various methods have been undertaken, including preoperative remainder tissue determination, thyroidectomy with a lateral approach, or even preoperative electromyographic (EMG) determination of recurrent nerve trace, though all these methods fail to improve complication rates of secondary surgery (5). However, completion surgery is inevitable in certain conditions like various types of thyroid cancers and less frequently for benign thyroid diseases (6-9).

Emerging evidence from experimental and clinical studies suggests that barrier anti-adhesives could be of benefit in improving surgical adhesions (10-13); however, utility of anti-adhesive barriers in thyroid surgery has not been entirely studied. Available evidence comes from experimental animal studies that have shown efficacy of Hyaluronic acid-carboximethylcellulose (Seprafilm[®], HA-CMC) and Oxidized regenerated cellulose (Interceed, ORC) after thyroidectomy (14).

In the present study we utilized adhesive barriers of HA-CMC and Polylactic acid (PLA, Surgiwrap[™]).

HA-CMC is a transparent film formed by combination of hyaluronic acid and carboxymethylcellulose, and is approved for clinical use by the American Food and Drug Administration (FDA). Carboxymethylcellulose is a polysaccharide produced by reaction of sodium monochlorine acetate with cellulose that prevents development of adhesion by keeping the serous surfaces distant by its heavy molecular structure and viscosity (15). The hyaluronic acid component of the HA-CMC, which turns into gel form after application, is absorbed by the body within 28 days. The absorption period of its CMC component is unknown (11,16).

The chemical structure of PLA barrier film is polylactic acid and is approved for clinical use by Consultants Europe (CE) and FDA. When dry PLA is wetted, it contracts with tissues conserving its transparency. Entire polymeric molecule is hydrolyzed to lactic acid molecules, which are subsequently metabolized by the liver. It is completely absorbed by the body within 6 to 18 months after application (17-20).

Both HA-CMC and PLA are transparent, allowing monitoring of background organs or region, and can be cut into required shape and dimensions. A number of studies have demonstrated that both agents reduce postoperative adhesions (11,13,16,21). Herein, we investigated the efficacy of adhesive barriers, HA-CMC and PLA, in reducing adhesions after thyroidectomy in an animal model.

Materials and methods

Animals

The study was conducted in Cerrahpaşa Medical School Experimental Research and Animal Laboratory after approval was obtained from the Experimental Animals Ethics Board. Forty-eight male Wistar-Albino rats weighing 200 to 250 g and 4-6 months of age were utilized. The animals were kept in accordance with standard animal care requirements. They were fed standard laboratory chow and given tap water ad libitum throughout the study period. The subjects were randomly divided into 3 equal groups, namely HA-CMC, PLA, and control groups.

Surgery

All subjects were operated on after administration of ether inhalation anesthesia in supine position. The neck was cleaned with 10% povidone-iodine solution and all surgical procedures were performed under aseptic conditions. Access to the thyroid zone was achieved by means of a 2 cm horizontal cervical incision. After the thyroid zone was entirely exhibited, subtotal thyroidectomy was performed. Subsequently, strap muscles were drawn together using 4/0 chrome catguts and the skin was closed using 4/0 silk. The subjects were kept under standard laboratory conditions postoperatively.

Eight animals in each group were re-operated 7 days and remaining subjects 28 days after the initial surgery. Before re-operation, all animals were sacrificed in an ether bath. Two surgeons (GC and HMK) who were blinded to prior procedure performed the second operation from the former cervical incision. Then thyroid and adjacent tissues including trachea and strap muscles were removed for histopathological examination.

The above-mentioned procedures were performed in all subjects. In primary surgery, before surgical closure, HA-CMC membrane (Seprafilm[®], Genzyme Company, Cambridge, MA, USA) or PLA (SurgiWrap[™], Macropore Biosurgery, Cyori Therapeutics Inc., San Diego, CA, USA) was applied to the HA-CMC and PLA groups, respectively. Both agents were cut to 1 × 1 cm and then modified to fit between thyroid zone and strap muscles.

Assessment of adhesion

Two surgeons examined the former surgical site during the second surgery and independently scored the adhesion as recommended by Majuzi et al. (22) (Table 1). Inter-observer agreement of scoring was reached in 42 subjects. Average score of the 2 surgeons was used in the remaining 6 subjects.

Histopathologic examination

An experienced pathologist, blinded to surgical data, performed histopathological examinations. Removed surgical tissues were fixed in 10% neutral buffered formalin for 24 h. Then material was processed, embedded in paraffin, sectioned at 5 µm, and stained with hematoxylin-eosin. Microscopically polymorphonuclear leukocytes, histiocytes, lymphocytes, multinuclear cells, granuloma formation, fibroblasts, collagen formation, fibrosis, fat necrosis, vascular proliferation, edema, and foreign body reaction were examined. The histopathologic examination was focused on 3 parameters. First, fibrosis, fibroblast, and collagen densities were regarded as criteria for adhesion formation. Second polymorphonuclear leukocyte, histiocyte, giant cell, chronic inflammation, and granuloma formation were considered as foreign body reaction. Finally fat necrosis indicated contamination.

Statistical analysis

All analyses were performed using SPSS for Windows 14.0 (SPSS inc, Chicago, IL, USA). The Kruskal-Wallis test was used to compare the groups. Pair-wise comparisons were performed by Mann-Whitney U test. P values less than 0.05 were considered statistically significant.

Table 1. Surgical scoring of postoperative adhesion.

Score	Evaluation
0	No adhesion
1	Very fine and partial adhesion
2	Easily splitting, medium density and parted adhesion
3	Easily splitting, but intense adhesion
4	Hardly splitting and highly intense adhesion

Results

No subject died in any stage of the experiment. Upon application HA-CMC readily adapted to tissues but deformed when exposed to wet surfaces, a disadvantage compared to PLA. One subject in the HA-CMC group developed a superficial wound infection on day 7. No adverse reaction was noted in the HA-CMC or PLA groups. Application of PLA was somewhat cumbersome since it was not readily adapted tissues and it was observed in the application zone on both days 7 and 28.

Surgical findings

There was a significant difference regarding adhesion scores between study and control groups on day 7 and 28 ($P < 0.014$ and $P < 0.001$ respectively, Figure 1). In pair-wise analyses less adhesion was observed in the HA-CMC group, compared to the control and PLA groups on both days 7 and 28 ($P = 0.005$ and $P = 0.002$, HA-CMC vs. C for days 7 and 28, respectively). No significant difference was observed between the control and PLA groups either on day 7 or 28. When day 7 and 28 adhesion scores compared within groups, the only significant difference was found in the PLA group ($P = 0.02$).

Histopathological findings

Adhesion. Fibroblast, fibrosis, and collagen densities were found to be higher in the HA-CMC and PLA groups compared to the control group on day 7 re-operations (Table 2). Although the difference was

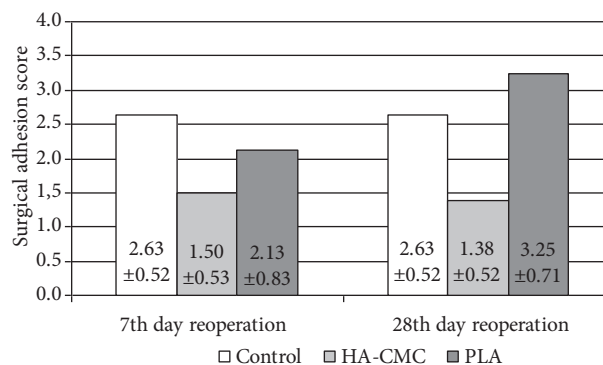


Figure 1. Surgical adhesion scores of control, HA-CMC and PLA groups. Values are given as mean ± SD.

insignificant between the HA-CMC and control group on day 28, it remained higher in the PLA group (Table 3).

Foreign body reaction. Foreign body reaction, which was determined by cellular infiltration and granuloma formation, was remarkable on day 7 re-operations in the HA-CMC group compared to the control and PLA groups. However, the reaction was reduced to comparable intensity with the control group on day 28. Although no significant difference was noted between the PLA and control groups on day 7, foreign body reaction was more evident in the PLA group than the control or HA-CMC groups on day 28. Fat necrosis was detected in none of the studied materials.

Table 2. Histopathologic characteristics of control, HA-CMC, and PLA groups on day 7 reoperations.

Histopathologic Feature	C n = 8	HA-CMC n = 8	PLA n = 8	P ₁	P ₂	P ₃	P ₄
Polymorphonuclear Leukocyte	0.88 ± 0.35	2.88 ± 1.25	0.50 ± 0.53	<0.001	0.001	ns	0.001
Histiocyte	1.00 ± 0	2.88 ± 0.35	1.38 ± 0.52	<0.001	0.001	ns	0.001
Lymphocyte	1.13 ± 0.35	2.00 ± 0	1.38 ± 0.52	0.002	0.002	ns	0.038
Multinuclear cell	0.88 ± 0.35	2.00 ± 0.53	1.38 ± 0.52	0.002	0.001	ns	0.065
Granuloma	1.00 ± 0.53	3.00 ± 0	1.38 ± 0.52	0.001	<0.001	ns	0.001
Foreign body reaction	0.88 ± 0.35	3.00 ± 0	1.38 ± 0.52	0.001	0.001	ns	0.001
Fibrocyte	1.25 ± 0.46	2.00 ± 0.53	2.00 ± 0.53	0.013	0.028	0.028	ns
Collagen	0.63 ± 0.52	1.75 ± 0.46	3.00 ± 0	0.001	0.003	0.001	<0.001
Fibrosis	0.63 ± 0.52	1.75 ± 0.46	1.88 ± 0.35	0.001	0.003	0.001	ns

Values are given as mean ± SD. P₁: Kruskal-Wallis P, P₂: HA-CMC vs. Control P₃: PLA vs. Control, P₄: HA-CMC vs. PLA, ns: nonsignificant

Table 3. Histopathologic characteristics of control, HA-CMC and PLA groups on day 28 reoperations.

Histopathologic Feature	C n = 8	HA-CMC n = 8	PLA n = 8	P ₁	P ₂	P ₃	P ₄
Polymorphonuclear Leukocyte	0.50 ± 0.53	0.25 ± 0.46	0.13 ± 0.35	ns	ns	ns	ns
Histiocyte	1.00 ± 0.93	2.38 ± 0.74	2.00 ± 0.53	0.012	0.010	0.050	ns
Lymphocyte	1.38 ± 0.74	1.38 ± 0.52	1.00 ± 0	ns	ns	ns	ns
Multinuclear cell	0.75 ± 0.71	1.13 ± 0.64	1.88 ± 0.35	0.006	ns	0.005	0.028
Granuloma	0.75 ± 0.71	1.63 ± 0.92	1.88 ± 0.35	0.013	0.065	0.005	ns
Foreign body reaction	0.88 ± 0.64	1.25 ± 0.71	2.00 ± 0	0.003	ns	0.002	0.038
Fibrocyte	0.13 ± 0.35	0.88 ± 0.64	1.25 ± 0.46	0.002	0.028	0.001	ns
Collagen	0.13 ± 0.35	0.13 ± 0.35	1.13 ± 0.35	<0.001	ns	0.001	0.001
Fibrosis	0.13 ± 0.35	0.13 ± 0.35	1.13 ± 0.35	0.001	ns	0.001	0.001

Values are given as mean ± SD. P₁: Kruskal-Wallis P, P₂: HA-CMC vs. Control
P₃: PLA vs. control, P₄: HA-CMC vs. PLA, ns: nonsignificant

Discussion

Results of our study indicated that HA-CMC significantly improved post-operative adhesions after thyroidectomy in an experimental animal model. However, histopathologically no significant difference was found between the HA-CMC and control groups. Additionally, PLA failed to improve adhesion formation in our study.

During our re-operations on day 7 we noted gel form of HA-CMC at the application zone while we could not find any detectable HA-CMC on day 28 since it was completely absorbed from the surgical site (Figure 2). However, PLA was remained unchanged at the application zone on both days 7 and 28 (Figure 3).

Histopathological examination revealed more inflammatory activity and foreign body reaction in day 7 surgery of HA-CMC applied subjects; but it was resolved and became similar with control subjects by day 28. While inflammatory activity and foreign body reaction in the PLA group were comparable with control subjects on day 7, it was more evident on day 28. Absorption periods of these 2 barriers are different due to their chemical properties (11,15-17), which may explain time specific difference regarding foreign body reaction. HA-CMC is readily absorbed in a short time and for its complete degradation a more severe reaction may be needed on day 7. PLA is more durable with a complete absorption time of 6 to 18

months (17); thereby inflammatory activity and foreign body reaction may be delayed. One month may not be adequate for true determination of foreign body reaction for PLA.

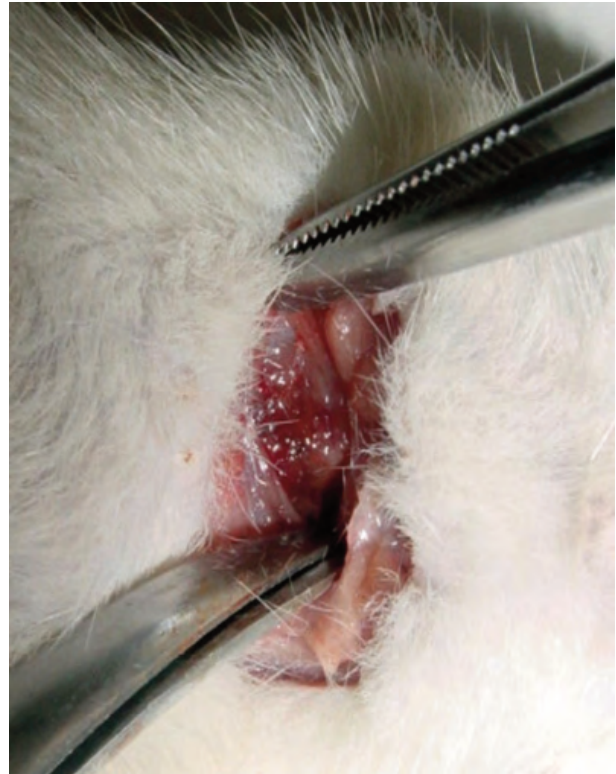

Figure 2. HA-CMC was completely absorbed from the surgical site on day 28.

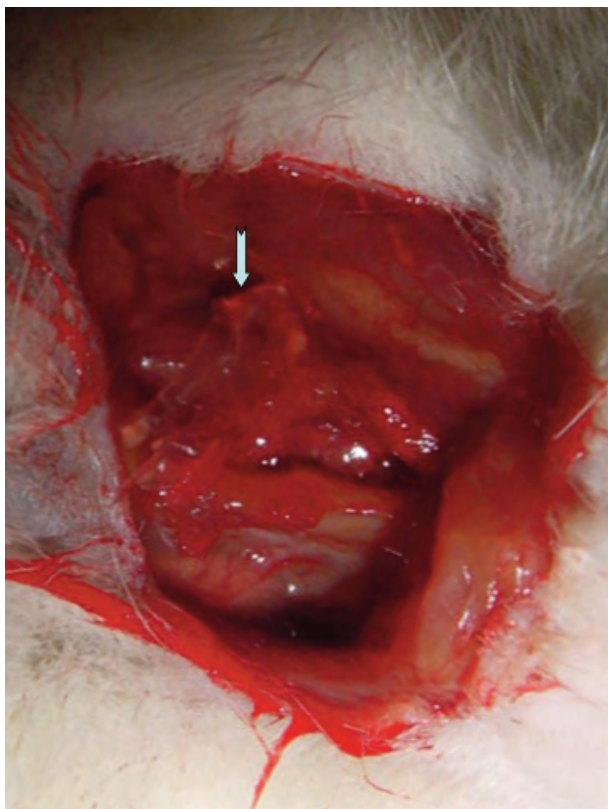


Figure 3. PLA remained unchanged at the application zone on day 28 (arrow).

Although it is not preferred, completion surgery is inevitable in certain conditions, particularly in malignant thyroid neoplasms (6-9). Major drawbacks of secondary surgery are development of RLN damage and hypoparathyroidism. Scarring and firm adhesions due to prior thyroidectomy make secondary surgery challenging, with increased complication rates (4,23). While several approaches were undertaken to reduce the complication rate, none of them was beneficial. Recent clinical and experimental studies indicated the efficacy of barrier anti-adhesives in preventing or reducing adhesions (10). Efficacy of HA-CMC has been demonstrated in abdominal surgery in animal models (15,24-26). Moreover, its efficacy was proven in humans in abdominal and gynecologic operations (11,13,16). PLA is another convenient adhesion barrier used mainly in orthopedic and spinal surgery (19,21).

Surgery-dependent factors affecting outcome of reoperation are proposed as timing of the second

surgery and loss of anatomic landmarks and adhesions due to primary surgery. Chao et al. (27) retrospectively investigated the complications of secondary thyroid operations that were primarily done for diagnosis of cancer in the paraffin block evaluation. While the period between the 2 operations varied from 1 month to 33 years, the study showed that the differences among the period between the 2 operations did not have an impact on complications. Pezzulo et al. reported complication rates of 28.5% and 23% in early and late (before and after 6 months) completion thyroidectomies, respectively, in patients with thyroid cancer (4). Likewise, Tan et al. did not find a significant difference in complication rates of re-operations performed within 10 days and after 90 days (28). These results indicated that timing of second thyroid surgery does not have a considerable impact on complications, and suggested adhesion formation as the foremost factor affecting the outcome.

We have a number of limitations in the present study. First, re-operations were performed on days 7 and 28. Seven-day period represented the average time to obtain histopathologic results of subtotal thyroidectomy material, and 28-day period represented the wound healing. However, for the above-mentioned reasons, 28-day period could not be adequate and a longer time may be needed for more accurate determination of the histopathological effects of barrier agents. Second, we did not properly perform subtotal thyroidectomy during primary surgery for technical reasons. However, thyroid and adjacent tissues were abraded until enough damage was achieved. Therefore, we do not think that it would be a major concern in our study.

In conclusion, application of HA-CMC between the thyroid zone and the strap muscles after thyroidectomy may reduce adhesion formation by its barrier function. Therefore, similar experimental and clinical studies are warranted in order to establish the clinical utility of barrier agents in thyroid surgery.

Acknowledgement

Seprafilm[®] and SurgiWrap[™] were kindly supplied by their manufacturers without any conflict of interest.

References

1. Auguste LJ, Attie NJ. Completion thyroidectomy for initially misdiagnosed thyroid cancer. *Otolaryngol Clin N Am* 1990; 23: 429-439.
2. Chao TC, Jeng LB, Lin JD, Chen MF. Completion thyroidectomy for differentiated thyroid carcinoma. *Otolaryngol Head Neck Surg* 1998; 118: 896-899.
3. Eroğlu A, Berberoğlu U, Buruk F, Yıldırım E. Completion thyroidectomy for differentiated thyroid carcinoma. *J Surg Oncol* 1995; 59: 261-266.
4. Pezzulo L, Delrio P, Losito NS, Caraco C, Mozzillo N. Postoperative complications after completion thyroidectomy for differentiated thyroid cancer. *Eur J Surg Oncol* 1997; 23: 215-218.
5. Dralle H, Sekulla C, Lorenz K, Brauckhoff M, Machens A; German IONM Study Group. Intraoperative monitoring of the recurrent laryngeal nerve in thyroid surgery. *World J Surg* 2008; 32: 1358-1366.
6. Sitreq-Serra A, Saucedo JJ. Surgical management of recurrent and intrathoracic goiters. In Clark OH, Duk AY, editors, *Textbook of Endocrine Surgery*, WB. Saunders Comp., Philadelphia, 1997; 262-274.
7. Muller PE, Jakoby R, Heinert G, Spelsberg F. Surgery for recurrent goitre: its complications and their risk factors. *Eur J Surg* 2001; 167: 816-821.
8. Pasięka JL, Thompson NW, McLeod MK, Burney RE, Macha M. The incidence of bilateral well-differentiated thyroid cancer found at completion thyroidectomy. *World J Surg* 1992; 16: 711-716.
9. De Jong SA, Demeter JG, Lawrence AM, Paloyan E. Necessity and safety of completion thyroidectomy for differentiated thyroid carcinoma. *Surgery* 1992; 112: 734-739.
10. DeCherney AH, DiZerega GS. Clinical problem of intraperitoneal postsurgical adhesion formation following general surgery and the use of adhesion prevention barriers. *Surg Clin North Am* 1997; 77: 671-688.
11. Diamond MP. Reduction of adhesions after uterine myomectomy by Seprafilm membrane: a blinded, prospective, randomized, multicenter clinical study. *Seprafilm Adhesion Study Group. Fertil Steril* 1996; 66: 904-910.
12. Diamond MP. Reduction of de novo postsurgical adhesions by intraoperative precoating with Sepracoat solution: a prospective, randomized, blinded, placebo-controlled multicenter study. *The Sepracoat Adhesion Study Group. Fertil Steril* 1998; 69: 1067-1074.
13. Zeng Q, Yu Z., You J, Zhang Q. Efficiency and safety of seprafilm for preventing postoperative abdominal adhesions: systemic review and metaanalysis. *World J Surg* 2007; 31: 2125-2131.
14. Yigit O, Uslu Coskun B., Coskun H, Yilmaz B, Alkan S, Cinar U et al. Efficacy of antiadhesive barriers in secondary thyroidectomy: an experimental study. *Laryngoscope* 2004; 114: 1668-1673.
15. Elkins TE, Ling FW, Ahokas RA, Abdella TN, Homsey CA, Malinak LR. Adhesion prevention by of sodium carboxymethyl cellulose in the rat-II. *Fertil Steril* 1984; 41: 929-932.
16. Becker JM, Dayton MT, Fazio VW, Beck DE, Stryker SJ, Wexner SD et al. Prevention postoperative abdominal adhesions by sodium hyaluronate based bioabsorbable membrane: a prospective, randomized, double blind, multicenter study. *J Am Coll Surg* 1996; 183: 406-407.
17. Brady JM, Cutright DE, Miller RA, Barristone GC. Resorption rate, route, route of elimination and ultrastructure of the implant side of polylactic acid in the abdominal wall of the rat. *J Biomed Mater Res* 1973; 7: 155-166.
18. Hollinger JO, Battistone GC. Biodegradable bone repair materials. *Synthetic polymers and ceramics. Clin Orthop Relat Res* 1986; 207: 290-305.
19. Kulkarni RK, Pani KC, Neuman C, Leonard F. Polylactic acid for surgical implants. *Arch Surg* 1966; 93: 839-843.
20. Pistner H, Gutwald R, Ordnung R, Reuther J, Mühling J. Poly(L-lactide): a long term degradation study in vivo. I. Biological results. *Biomaterials* 1993; 14: 671-677.
21. Welch WC, Cornwall GB, Toth JM, Turner AS, Thomas KA, Gerszten PC et al. Use of polylactide resorbable film as an adhesion barrier. *Orthopedics* 2002; 25: 1121-1130.
22. Majuzi MK, Kalambahati K, Paear B. Prevention of adhesions with polyvinylpyrrolidone. *Arch Surg* 1964; 89: 1011.
23. Fewins J, Simpson CB, Miller FR. Complication of thyroid and parathyroid surgery. *Otolaryngol Clin North Am* 2003; 36: 189-206.
24. Hooker GD, Taylor BM, Driman DK. Prevention of adhesion formation with use of sodium hyaluronate-based bioresorbable membrane in a rat model of ventral hernia repair with polypropylene mesh. *Surgery* 1999; 125: 211-216.
25. Alponat A, Lakshminarasappa SR, Yavuz N, Goh PM. Prevention of adhesions by Seprafilm, an absorbable adhesion barrier: an incisional hernia model in rats. *Am Surg* 1997; 63: 818-819.
26. Moreira H, Wexner SD, Yamaguchi T, Pikarsky AJ, Choi JS, Weiss EG et al. Use of bioresorbable membrane (sodium hyaluronate-carboxymethylcellulose) controlled bowel injuries in a rabbit model. *Dis Colon Rectum* 2000; 43: 182-187.
27. Chao TC, Jeng LB, Lin JD. Reoperative thyroid surgery. *World J Surg* 1997; 21: 644-647.
28. Tan MP, Agarwal G, Reeve TS, Barraclough BH, Delbridge LW. Impact of timing on completion thyroidectomy for thyroid cancer. *Br J Surg* 2002; 89: 802-804.