

1-1-2012

A combination therapy of half-dose verteporfin photodynamic therapy and intravitreal injection of ranibizumab for chronic central serous chorioretinopathy

YASİN TOKLU

HASAN BASRİ ÇAKMAK

MÜCELLA ARIKAN YORGUN

ŞULE BERK ERGUN

ŞABAN ŞİMŞEK

Follow this and additional works at: <https://journals.tubitak.gov.tr/medical>



Part of the [Medical Sciences Commons](#)

Recommended Citation

TOKLU, YASİN; ÇAKMAK, HASAN BASRİ; YORGUN, MÜCELLA ARIKAN; ERGUN, ŞULE BERK; and ŞİMŞEK, ŞABAN (2012) "A combination therapy of half-dose verteporfin photodynamic therapy and intravitreal injection of ranibizumab for chronic central serous chorioretinopathy," *Turkish Journal of Medical Sciences*: Vol. 42: No. 4, Article 18. <https://doi.org/10.3906/sag-1101-1470>
Available at: <https://journals.tubitak.gov.tr/medical/vol42/iss4/18>

This Article is brought to you for free and open access by TÜBİTAK Academic Journals. It has been accepted for inclusion in Turkish Journal of Medical Sciences by an authorized editor of TÜBİTAK Academic Journals. For more information, please contact academic.publications@tubitak.gov.tr.

A combination therapy of half-dose verteporfin photodynamic therapy and intravitreal injection of ranibizumab for chronic central serous chorioretinopathy

Yasin TOKLU, Hasan Basri ÇAKMAK, Mücella ARIKAN YORGUN, Şule Berk ERGUN, Şaban ŞİMŞEK

Aim: To study the combination treatment consisting of half-dose verteporfin photodynamic therapy (PDT) and an intravitreal injection of ranibizumab as a potential treatment for patients with chronic central serous chorioretinopathy (CSC).

Materials and methods: Six eyes of 6 patients were studied with fundus examination, fluorescein angiography, and optical coherence tomography to diagnose the maculopathy, monitor the detachments, and localize the choroidal hyperpermeability of the disorder. Half-dose verteporfin PDT was applied to areas of choroidal hyperpermeability and, the following day, 0.5 mg/0.05 mL ranibizumab was injected intravitreally. The patients were observed to determine the anatomic and functional outcomes.

Results: The combination therapy consisting of half-dose verteporfin PDT and intravitreal injection of ranibizumab was associated with complete resolution of the exudative macular detachments in all of the patients. Vision improved in the 6 eyes and remained unchanged during the follow-up examinations, for at least more than 6 months. At 4 weeks after treatment, the best corrected visual acuity had improved to 20/20 in 5 of the cases. None of the patients had any treatment-related side effects.

Conclusion: The combination therapy consisting of half-dose verteporfin PDT and intravitreal injection of ranibizumab seems to result in the resolution of exudative detachments in patients with chronic CSC. This treatment caused a rapid reduction in subretinal fluid and improvement in visual acuity. Although the follow-up time and the number of patients in this study were limited, the encouraging results and lack of complications suggest the value of further study.

Key words: Central serous chorioretinopathy, intravitreal ranibizumab, photodynamic therapy

Kronik santral seröz korioretinopatide kombine yarım doz verteporfinin fotodinamik tedavi ve intravitreal ranibizumab enjeksiyonu

Amaç: Kronik santral seröz korioretinopati (SSKR) tedavisinde yarım doz verteporfinin fotodinamik tedavisi ve intravitreal ranibizumab enjeksiyonu kombine tedavisini değerlendirmek.

Yöntem ve gereç: Altı hastanın 6 gözü çalışmaya alındı. Makulopati tanısını koymak, dekolmanı göstermek ve koroidal hiperpermeabiliteyi lokalize etmek amacıyla fundus muayenesi, floresein anjiografi, optik koherens tomografi kullanıldı. Yarım doz verteporfinin fotodinamik tedavisi koroidal hiperpermeabilite alanlarına uygulandı ve ertesi gün 0,5 mg/0,05 mL ranibizumab intravitreal olarak enjekte edildi. Hastalar anatomik ve fonksiyonel sonuçları belirlemek amacıyla takip edildi.

Bulgular: Yarım doz verteporfinin fotodinamik tedavisi ve intravitreal ranibizumab enjeksiyonundan oluşan kombine tedavi, eksudatif makula dekolmanının tamamen rezorbsiyonunda tüm hastalarda etkili bulundu. Görme keskinliği

6 hastada da artmış olarak bulundu ve en az 6 aylık takiplerde değişmedi. Tedaviden 4 hafta sonra 1 hasta dışında tüm hastalarda en iyi düzeltilmiş görme keskinliği 20/20 seviyesine yükseldi. Tedaviye bağlı hiçbir hastada yan etki görülmedi.

Sonuç: Yarım doz verteporfin fotodinamik tedavisi ve intravitreal ranibizumab enjeksiyonundan oluşan kombine tedavi kronik SSKR hastalarında eksudatif dekolmanın çözülmesinde etkin görülmüştür. Bu tedavi subretinal sıvının hızlı azalmasına ve görme keskinliğinin düzelmesine neden olmaktadır. Bu çalışmada takip süresi ve hasta sayısı az olmakla birlikte, komplikasyonların azlığı ve cesaret verici sonuçlar daha geniş, prospektif ve randomize çalışmaları gerektirmektedir.

Anahtar sözcükler: Santral seröz korioretinopati, intravitreal ranibizumab, fotodinamik tedavi

Introduction

Central serous chorioretinopathy (CSC) is characterized by an idiopathic circumscribed serous retinal detachment that is usually confined to the posterior pole, caused by leakage of fluid through the retinal pigment epithelium (1). It is a well-characterized disorder leading to serous neurosensory elevation of the retina. The acute form of the disease is associated with focal leakage at the level of the retinal pigment epithelium (RPE) demonstrated with fluorescein angiography (FA), and hyperpermeability of the choroid demonstrated with indocyanine green angiography (2). The disorder is self-limited in the majority of patients, who usually retain excellent vision. On the other hand, in some cases, CSC shows widespread alteration of pigmentation of the RPE in the posterior pole, which appears to be related to the chronic presence of subretinal fluid. This variant of CSC has been termed “diffuse retinal pigment epitheliopathy” or “chronic CSC” (3).

Recently, photodynamic therapy (PDT) with verteporfin has been used for treating CSC, and studies have demonstrated beneficial visual outcomes in most patients (4-10). The mechanism of action of PDT for treating CSC is not known, but it is postulated to be caused by short-term choriocapillaris hypoperfusion and long-term choroidal vascular remodeling, leading to a reduction in choroidal congestion, vascular hyperpermeability, and extravascular leakage (11,12). However, PDT can cause some potential complications such as RPE atrophy, choroidal ischemia, and secondary choroidal neovascularization (CNV) (13). Because patients with CSC usually have relatively good baseline visual acuity, it is important that the extent of the retinal

toxicity be limited to minimum during treatment while not losing the treatment effects. After reducing the dose of verteporfin and altering the timing of the infusion and laser application, it was reported that the potential retinal damage caused by PDT could be minimized while not lowering treatment efficacy in the treatment of chronic CSC (14,15).

Both the side effects related to PDT and the occurrence of recurrence after PDT compel the need for other treatment modalities. Antibodies to vascular endothelial growth factor (VEGF) have known antipermeability properties and therefore may theoretically reverse the changes seen in CSC. Mitzy et al. (16) reported that intravitreal injection of bevacizumab was associated with visual improvement and reduced neurosensory detachment without adverse events in patients with CSC. Moreover, PDT was shown to induce a rapid inflammatory response, including infiltration of leukocytes and increased expression of cytokines (e.g., intracellular adhesion molecule (ICAM)-1 and interleukin (IL)-6) (17). Half-dose verteporfin therapy combined with intravitreal injection of VEGF inhibitors is expected to induce fewer angiogenic and inflammatory side effects on the level of the choroid. We postulated that reducing the dose of verteporfin and the addition of intravitreal ranibizumab might minimize the potential retinal damage caused by PDT, while at the same time having sufficient therapeutic effects on the choroidal vasculature required for treating CSC. The aim of this study was to evaluate the short-term efficacy of a safety-enhanced PDT protocol with half-dose verteporfin combined with intravitreal ranibizumab injection in the treatment of chronic CSC.

Materials and methods

Patients with a diagnosis of CSC with a history of decreased visual acuity for more than 3 months were included in the study. All of the patients had an idiopathic neurosensory retinal elevation demonstrated by optical coherent tomography (OCT) (RTVue; Optovue Inc., Fremont, CA, USA) and had the presence of focal leaks at the level of the RPE on FA. Patients who received previous PDT for chronic CSC or had evidence of CNV on FA were excluded. Patients underwent a detailed informed consent process, with special attention given to the known side effects of systemic bevacizumab administration, and they were excluded from treatment if they had a significant cardiovascular or thromboembolic history or were pregnant.

The safety-enhanced PDT protocol for CSC was performed using half the normal dose of verteporfin (Visudyne; Novartis AG, Bülach, Switzerland), that is, 3 mg/m² verteporfin, with the rationale that using a lower dose has less severe collateral damage effects to the retina and choroids (14). Verteporfin was infused over 10 min, followed by the delivery of a laser at 689 nm at 15 min from the commencement of infusion to target the area of choroidal dilation and hyperpermeability. A total light energy of 50 J/cm² over 83 s was delivered to the area of choroidal hyperperfusion, as observed in fundus FA. To avoid overtreatment of the choroidal vasculature and choroidal ischemia, the laser spot size was set at a maximum of 4500 µm. After treatment, all of the patients were given protective spectacles and were instructed to avoid strong light for 3 days.

All of the patients were treated only once at baseline and no other treatment, including additional PDT or laser photocoagulation, was performed during the 12-month follow-up. All patients received an intravitreal injection of 0.5 mg/0.05 mL ranibizumab (Lucentis®; Novartis, Basel, Switzerland) under standard protocol conditions 1 day after the PDT treatment. Each patient underwent best corrected visual acuity measurements with Snellen charts, slit-lamp examination, dilated retinal funduscopy, and OCT and FA at the baseline and follow-up examinations. The demographic details, duration of symptoms, number of CSC episodes pre-PDT and post-PDT, best corrected visual acuity (BCVA), and OCT findings of the 6 cases in the study are shown in the Table.

Case reports

Case 1

A 34-year-old male with a history of 3 recurrent CSC episodes and visual acuity of 20/32 in the right eye presented with 4 months of new symptoms, including decreased vision and metamorphopsia. Ophthalmologic examination revealed neurosensory elevation of the central macula, and FA showed a focal RPE leak inferior to the fovea. OCT revealed an RPE detachment that involved the fovea. The foveal thickness was measured as 327 µm. A combination treatment of PDT and intravitreal ranibizumab was given. Visual acuity had improved to 20/20 at 1 month after treatment with improvement of both fluorescein leakage and neurosensory detachment. No changes were observed at the 6-month follow-up (Figure 1).

Table. The demographic details, duration of symptoms, number of CSC episodes pre-PDT and post-PDT, BCVA, and OCT findings of 6 cases in the study. *SRF: subretinal fluid, PED: pigment epithelial detachment.

Patient No.	Age	Sex	Eye	Duration of symptoms (months)	No. of CSC episodes	Baseline BCVA	BCVA at 1 month post-PDT	Baseline OCT foveal thickness (µm)	OCT foveal thickness at 1 month (µm)	Baseline OCT anatomical findings*
1	34	Male	Right	4	3	20/32	20/20	327	185	SRF + PED
2	45	Female	Right	11	1	20/32	20/25	776	167	SRF + PED
3	54	Male	Left	5	1	20/32	20/20	273	126	SRF + PED
4	40	Male	Left	12	1	20/50	20/20	529	234	SRF + PED
5	43	Female	Right	6	1	20/40	20/20	403	176	SRF
6	38	Male	Left	4	1	20/50	20/20	192	174	SRF + PED

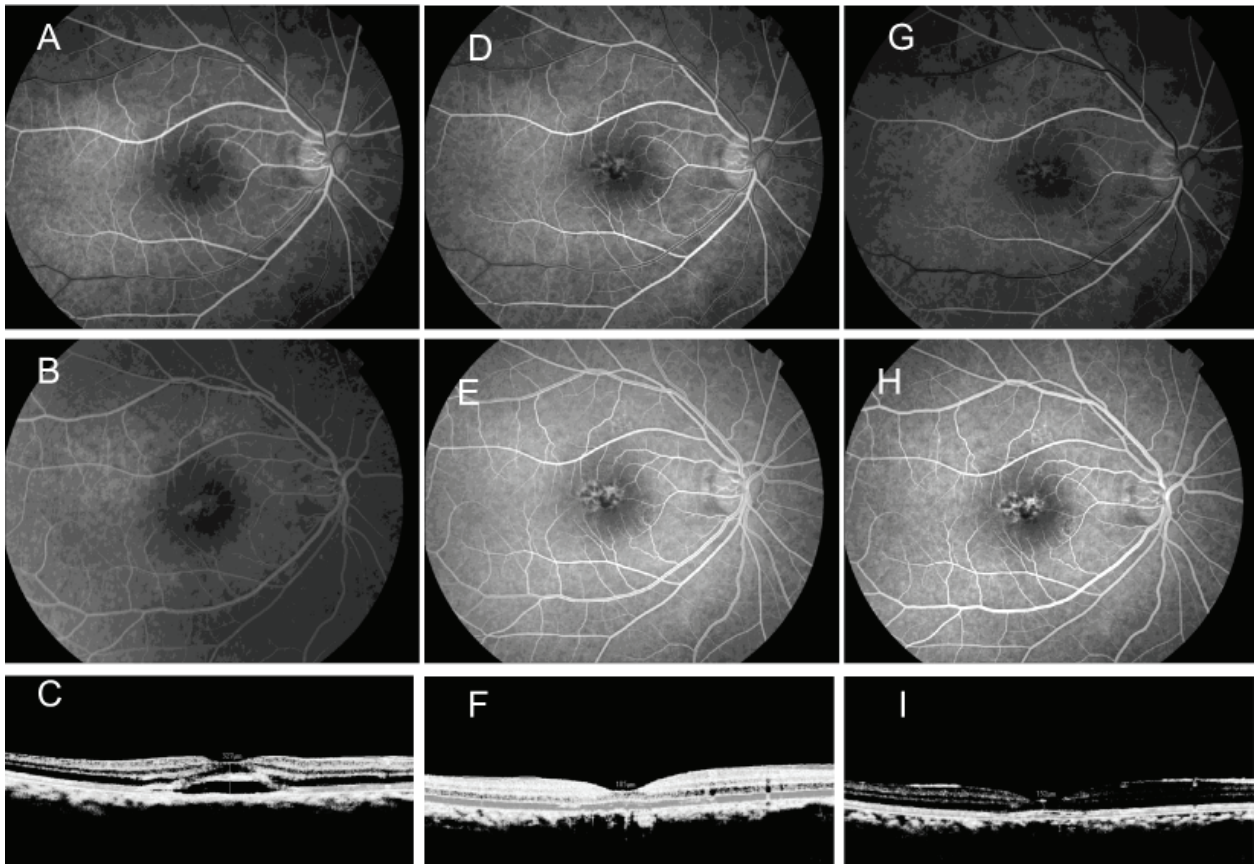


Figure 1. Right eye of a 34-year-old male with recurrent chronic CSC for 4 months, who received safety-enhanced PDT with half-dose verteporfin and intravitreal ranibizumab injection. The baseline BCVA was 20/32 in the right eye. Early-phase (A) and late-phase (B) FA images obtained at baseline show the leakage pattern of fluorescein with a mild window defect superior to the fovea. The baseline OCT image (C) shows the presence of subretinal fluid involving the fovea. At 1 month after treatment, the BCVA improved to 20/20. Early-phase (D) and late-phase (E) FA images demonstrate the absence of fluorescein leakage at the macula, with a mild window defect superior to the fovea. The OCT image (F) obtained at 1 month shows the complete resolution of the subretinal fluid. No changes were observed at the 6 month follow-up in the early-phase (G) or late-phase (H) FA images or in the OCT image (I).

Case 2

A 45-year-old female with a visual acuity of 20/32 in the right eye presented with 11 months of decreased vision and metamorphopsia. Examination revealed neurosensory elevation of the central macula, and FA showed a focal RPE leak that involved the fovea. OCT revealed an RPE and neurosensory detachment through the fovea. Visual acuity had improved to 20/25 at 1 month after combination treatment with improvement of both fluorescein leakage and neurosensory detachment. At the 6-month follow-up, no neurosensory retinal detachment or fluorescein leakage was observed (Figure 2).

Case 3

A 54-year-old male presented with complaints of decreased visual acuity in the left eye for 5 months and excessive discomfort with visual acuity that interfered with his daily activities. The best corrected visual acuity was 20/32. FA revealed a focal RPE leak just temporal to the fovea with surrounding neurosensory detachment, confirmed by OCT. Moreover, the OCT revealed RPE and neurosensory detachment adjacent to and including the fovea. Visual acuity had improved to 20/20 at 1 month after treatment with concurrent resolution of symptoms, fluorescein leakage, and RPE and neurosensory

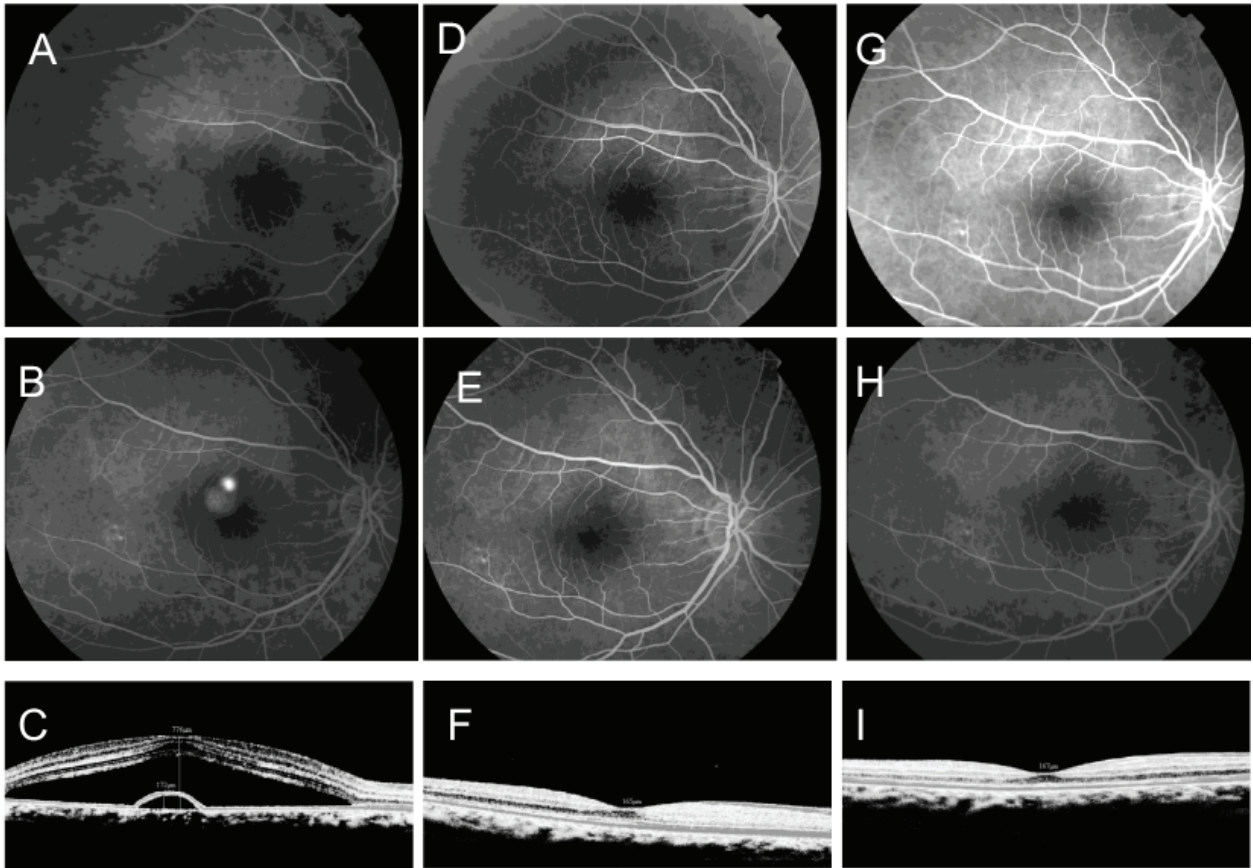


Figure 2. Right eye of a 45-year-old female with acute CSC for 11 months, who received safety-enhanced PDT with half-dose verteporfin and intravitreal ranibizumab injection. The baseline BCVA was 20/32 in the right eye. Early-phase (A) and late-phase (B) FA images obtained at baseline show pinpoint leakage with fluorescein leakage involving the fovea. The baseline OCT image (C) shows subretinal fluid involving the fovea. At 1 month after treatment, the BCVA improved to 20/20. Early-phase (D) and late-phase (E) FA images demonstrate the absence of fluorescein leakage at the macula. The OCT image (F) obtained at 1 month shows a normal foveal depression with resolution of subretinal fluid. No changes were observed at the 6-month follow-up in the early-phase (G) or late-phase (H) FA images or in the OCT image (I).

detachment. At the 6-month follow-up, results for visual acuity, OCT, and FA were unchanged.

Case 4

A 40-year-old male presented with a 12-month history of decreased visual acuity in his left eye. At the time of presentation, visual acuity was 20/50. FA revealed a focal RPE leak near the fovea with surrounding neurosensory detachment confirmed by OCT, which was treated with a combination treatment of PDT and intravitreal ranibizumab. Visual acuity had improved to 20/20 at 1 month after treatment with decreased neurosensory detachment demonstrated by OCT and improvement in symptoms. At the 3- and 6-month follow-ups, no subretinal fluid was observed by OCT.

Case 5

A 43-year-old female with a history of CSC complained of worsened vision and central scotoma in the left eye for 6 months. Visual acuity at the time of presentation was 20/40. Fluorescein angiography revealed a focal RPE leak just superior to the fovea with surrounding neurosensory detachment confirmed by OCT. Visual acuity had improved to 20/30 at 1 month after intravitreal ranibizumab, with reduction of fluorescein angiographic leakage and resolution of neurosensory detachment on OCT. At the 3- and 6-month follow-ups, visual acuity had improved to 20/20; there was resolution of the fluorescein leakage, but persistent atrophy of RPE was observed.

Case 6

A 38-year-old male presented with a 4-month history of decreased visual acuity in his left eye. In his first ophthalmological examination, visual acuity was 20/50. The FA showed a focal RPE leak near the fovea with surrounding neurosensory detachment confirmed by OCT, and this was treated with a combination treatment of PDT and intravitreal ranibizumab. Visual acuity had improved to 20/20 at 1 month after treatment with resolution of neurosensory detachment demonstrated by OCT and improvement in symptoms. At the 3- and 6-month follow-ups, no subretinal fluid was observed by OCT.

Discussion

Persistent subretinal fluid causes a decrease in visual acuity in CSC. Especially in chronic CSC, progressive chorioretinal deterioration can produce severe and irreversible visual loss (18-20). Various treatment methods, including thermal laser photocoagulation and pharmacological agents, including β -blockers, acetazolamide, and ketoconazole, have been attempted for treating CSC. However, these treatment modalities did not affect the duration of symptoms, the recurrence rate, or the final visual acuity (21).

PDT is emerging as a new treatment modality for chronic CSC. Recently, a small number of studies have examined its use in the treatment of chronic CSC (4-7,9,15). Yannuzzi et al. (7) reported that 60% of patients had complete resolution of subretinal fluid. Moreover, Cardillo Piccolino et al. (6) and Taban et al. (9) reported that patients with chronic CSC showed a marked reduction in subretinal fluid and improved visual acuity. Patients in the 3 studies described above were given verteporfin in doses of 6 mg/m². In a more recent study, Chan et al. (15) reported the use of half-dose (3 mg/m²) verteporfin for treatment of chronic CSC, and 90% of the patients had complete resolution of serous detachment at 12 months. The results of these studies support the idea that PDT appears to be an effective means of treating chronic CSC, allowing for reduction or resolution of chronic fluid leakage and subretinal fluid accumulation and stabilization or improvement in visual acuity.

The primary effect of PDT seems to be damage of the choriocapillaris endothelium: mainly

swelling, fragmentation, detachment from its basement membrane, and degeneration (12). The vascular endothelial damage is caused by the direct interaction of singlet oxygen with the lipids of the endothelial cytoplasmic membranes. Recanalization of the choriocapillaris begins to occur within a short interval after doses of therapy. Yannuzzi et al. (7) reported that reperfusion of the choriocapillaris begins as early as 2 or 3 weeks after PDT treatment; some slow perfusion exists in some patients for up to 3 months. A significant clinical or functional alteration in the RPE and neurosensory retina does not appear to occur. However, the application of conventional PDT in CSC is not without its complications, as the development of RPE atrophy, choriocapillaris ischemia, and secondary CNV have also been reported after PDT for chronic CSC (8). Moreover, clinical, electrophysiological, and laboratory studies have also demonstrated that transient reduction in macular function may develop following PDT with conventional verteporfin dosage and laser fluence (22,23). Modifying the therapy to obtain the maximal treatment effect with minimal toxicity is crucial in treating patients with CSC since these patients usually have relatively good baseline visual acuity.

PDT was shown to induce a rapid inflammatory response including infiltration of leukocytes and increased expression of cytokines [e.g., ICAM-1 and IL-6] (17). This inflammatory response may counteract the benefits of PDT treatment, causing recurrences or development of choroidal neovascular membranes. Given that PDT causes closure of the choriocapillaris (inducing ischemia) when applied in cases of CSC, it is not surprising that VEGF is upregulated in regions where PDT has been applied. It has been shown that CNV is induced by overexpression of VEGF (24). In fact, PDT using verteporfin has been shown to induce a reproducible angiogenic response in human eyes: VEGF, VEGF receptor 3, and pigment epithelium-derived factor expression are enhanced after PDT (25). Choroidal endothelial cells appear to be the primary site of angiogenic stimulation, which is why treatments aiming to controlling inflammatory reactions after PDT treatments are expected to have higher success rates. Additionally, reduced levels of VEGF may ameliorate the choroidal hyperpermeability in CSC. Recent studies showed that intravitreal anti-VEGF

monotherapy for the treatment of CSC was safe and effective, providing functional and anatomic benefits (16,26-30). Therefore, anti-VEGF therapy in combination with PDT treatment may provide additional benefit in such cases.

There are several limitations in this study, including the small number of patients, the short follow-up, and the fact that we included various forms of CSC. There are also no data available to support or refute the proposed mechanism of action. This study is a retrospective case series and several large-scale studies are needed for more clear conclusions.

We do not know the mechanism by which intravitreal ranibizumab effects CSC, but it may be related to its ability to affect vascular permeability and/or inflammatory reactions developing after PDT. In addition, no study has reported VEGF levels in patients with CSC. For this reason, the effect of intravitreal ranibizumab in CSC remains speculative.

Although the use of a combination of PDT with intravitreal ranibizumab injection for treating CSC is a rational and attractive concept, its benefits, based on this study, are not conclusive. The number of patients treated in the current study was small, and the follow-up period was limited. Although

our study examined a consecutive series of patients prospectively, it lacked matched controls. The main limitation of this study was the lack of a control group using full-dose verteporfin or a placebo group for comparison. Without head-to-head comparison, our study could not provide conclusive evidence to answer the question of whether CSC is better left with observation or treated. In addition, the positive results may be ascribable to the simple effect of the PDT. In an attempt to assess the effect of the combined therapy, outcomes between combined therapy and PDT monotherapy should be compared. Accordingly, this study was a retrospective interventional case series, not a definitive clinical trial. Further research is needed to see whether there are any late-onset adverse effects or longer-lasting benefits without the advent of recurrent disease.

In conclusion, the current study shows that a combination treatment regime of PDT and intravitreal ranibizumab resulted in significant improvement in BCVA and reduction in OCT central foveal thickness following treatment. The treatment effects were sustained at follow-up examinations, as complete resolution of serous retinal detachment was found in all of the cases.

References

1. Spaide RF. Central serous chorioretinopathy. In: Holz FG, Spaide RF, editors. Medical retina. Berlin: Springer-Verlag; 2005. p.77.
2. Gass JD. Pathogenesis of disciform detachment of the neuroepithelium. *Am J Ophthalmol* 1967; 63: 1-139.
3. Spaide RF. Central serous chorioretinopathy and other causes of serous detachment of the retina. In: Spaide RF, editor. Diseases of the retina and vitreous. Philadelphia (PA): WB Saunders; 1999. p.251.
4. Battaglia Parodi M, Da Pozzo S, Ravalico G. Photodynamic therapy in chronic central serous chorioretinopathy. *Retina* 2003; 23: 235-7.
5. Canakis C, Livir-Rallatos C, Panayiotis Z, Livir-Rallatos G, Persidis E, Conway MD et al. Ocular photodynamic therapy for serous macular detachment in the diffuse retinal pigment epitheliopathy variant of idiopathic central serous chorioretinopathy. *Am J Ophthalmol* 2003; 136: 750-2.
6. Cardillo Piccolino F, Eandi CM, Ventre L, Rigault de la Longrais RC, Grignolo FM. Photodynamic therapy for chronic central serous chorioretinopathy. *Retina* 2003; 23: 752-63.
7. Yannuzzi LA, Slakter JS, Gross NE, Spaide RF, Costa DL, Huang SJ et al. Indocyanine green angiography-guided photodynamic therapy for treatment of chronic central serous chorioretinopathy: a pilot study. *Retina* 2003; 23: 288-98.
8. Chan WM, Lam DS, Lai TY, Tam BS, Liu DT, Chan CK. Choroidal vascular remodelling in central serous chorioretinopathy after indocyanine green guided photodynamic therapy with verteporfin: a novel treatment at the primary disease level. *Br J Ophthalmol* 2003; 87: 1453-8.
9. Taban M, Boyer DS, Thomas EL. Chronic central serous chorioretinopathy: photodynamic therapy. *Am J Ophthalmol* 2004; 137: 1073-80.
10. Ober MD, Yannuzzi LA, Do DV, Spaide RF, Bressler NM, Jampol LM et al. Photodynamic therapy for focal retinal pigment epithelial leaks secondary to central serous chorioretinopathy. *Ophthalmology* 2005; 112: 2088-94.
11. Schlotzer-Schrehardt U, Viestenz A, Naumann GO, Laqua H, Michels S, Schmidt-Erfurth U. Dose-related structural effects of photodynamic therapy on choroidal and retinal structures of human eyes. *Graefes Arch Clin Exp Ophthalmol* 2002; 240: 748-57.

12. Schmidt-Erfurth U, Laqua H, Schlotzer-Schrehard U, Viestenz A, Naumann GO. Histopathological changes following photodynamic therapy in human eyes. *Arch Ophthalmol* 2002; 120: 835-44.
13. Colucciello M. Choroidal neovascularization complicating photodynamic therapy for central serous retinopathy. *Retina* 2006; 26: 239-42.
14. Lai TY, Chan WM, Li H, Lai RY, Liu DT, Lam DS. Safety enhanced photodynamic therapy with half dose verteporfin for chronic central serous chorioretinopathy: a short term pilot study. *Br J Ophthalmol* 2006; 90: 869-74.
15. Chan WM, Lai TY, Lai RY, Tang EW, Liu DT, Lam DS. Safety enhanced photodynamic therapy for chronic central serous chorioretinopathy: one-year results of a prospective study. *Retina* 2008; 28: 85-93.
16. Torres-Soriano ME, Garcia-Aguirre G, Kon-Jara V, Ustariz-Gonzales O, Abraham-Marin M, Ober MD et al. A pilot study of intravitreal bevacizumab for the treatment of central serous chorioretinopathy (case reports). *Graefes Arch Clin Exp Ophthalmol* 2008; 246: 1235-9.
17. Gollnick SO, Evans SS, Baumann H, Owczarczak B, Maier P, Vaughan L et al. Role of cytokines in photodynamic therapy-induced local and systemic inflammation. *Br J Cancer* 2003; 88: 1772-9.
18. Yannuzzi LA, Shakin JL, Fisher YL, Altomonte MA. Peripheral retinal detachments and retinal pigment epithelial atrophic tracts secondary to central serous pigment epitheliopathy. *Ophthalmology* 1984; 91: 1554-72.
19. Jalkh AE, Jabbour N, Avila MP, Trempe CL, Schepens CL. Retinal pigment epithelium decompensation. I. Clinical features and natural course. *Ophthalmology* 1984; 91: 1544-8.
20. Levine R, Brucker AJ, Robinson F. Long-term follow-up of idiopathic central serous chorioretinopathy by fluorescein angiography. *Ophthalmology* 1989; 96: 854-9.
21. Burumcek E, Mudun A, Karacorlu S, Arslan MO. Laser photocoagulation for persistent central serous retinopathy: Results of long-term follow-up. *Ophthalmology* 1997; 104: 616-22.
22. Oner A, Karakucuk S, Mirza E, Erkilic K. Electrooculography after photodynamic therapy. *Doc Ophthalmol* 2005; 111: 83-6.
23. Oner A, Karakucuk S, Mirza E, Erkilic K. The changes of pattern electroretinography at the early stage of photodynamic therapy. *Doc Ophthalmol* 2005; 111: 107-12.
24. Spilsbury K, Garrett KL, Shen WY, Constable IJ, Rakoczy PE. Overexpression of vascular endothelial growth factor (VEGF) in the retinal pigment epithelium leads to the development of choroidal neovascularization. *Am J Pathol* 2000; 157: 135-44.
25. Schmidt-Erfurth U, Schlotzer-Schrehard U, Cursiefen C, Michels S, Beckendorf A, Naumann GO. Influence of photodynamic therapy on expression of vascular endothelial growth factor (VEGF), VEGF receptor 3, and pigment epithelium-derived factor. *Invest Ophthalmol Vis Sci* 2003; 44: 4473-80.
26. Schaal KB, Hoeh AE, Scheuerle A, Schuett F, Dithmar S. Intravitreal bevacizumab for treatment of chronic central serous chorioretinopathy. *Eur J Ophthalmol* 2009; 19: 613-7.
27. Seong HK, Bae JH, Kim ES, Han JR, Nam WH, Kim HK. Intravitreal bevacizumab to treat acute central serous chorioretinopathy: short-term effect. *Ophthalmologica* 2009; 223: 343-7.
28. Lim SJ, Roh MI, Kwon OW. Intravitreal bevacizumab injection for central serous chorioretinopathy. *Retina*; 30: 100-6.
29. Artunay O, Yuzbasioglu E, Rasier R, Sengul A, Bahcecioglu H. Intravitreal bevacizumab in treatment of idiopathic persistent central serous chorioretinopathy: a prospective, controlled clinical study. *Curr Eye Res*; 35: 91-8.
30. Symeonidis C, Kaprinis K, Manthos K, Androudi S, Anastasilakis K, Dimitrakos SA. Central serous chorioretinopathy with subretinal deposition of fibrin-like material and its prompt response to ranibizumab injections. *Case Report Ophthalmol*; 2: 59-64.