

1-1-2002

Avipox in a Common Buzzard (*Buteo buteo*)

ÖZLEM ÖZMEN

GERRY M. DORRESTEIN

Follow this and additional works at: <https://journals.tubitak.gov.tr/veterinary>



Part of the [Animal Sciences Commons](#), and the [Veterinary Medicine Commons](#)

Recommended Citation

ÖZMEN, ÖZLEM and DORRESTEIN, GERRY M. (2002) "Avipox in a Common Buzzard (*Buteo buteo*)," *Turkish Journal of Veterinary & Animal Sciences*: Vol. 26: No. 5, Article 35. Available at: <https://journals.tubitak.gov.tr/veterinary/vol26/iss5/35>

This Article is brought to you for free and open access by TÜBİTAK Academic Journals. It has been accepted for inclusion in Turkish Journal of Veterinary & Animal Sciences by an authorized editor of TÜBİTAK Academic Journals. For more information, please contact academic.publications@tubitak.gov.tr.

Avipox in a Common Buzzard (*Buteo buteo*)

Özlem ÖZMEN

Akdeniz University, Burdur Veterinary Faculty, Department of Pathology, 15100 Burdur - TURKEY

Gerry M. DORRESTEIN

Utrecht University, Faculty of Veterinary Medicine, Department of Veterinary Pathology, The Netherlands

Received: 04.03.2001

Abstract: An adult, male common buzzard (*Buteo buteo*) with a leg fracture and multiple proliferative cutaneous nodules on its feet was brought to Akdeniz University Burdur Veterinary Faculty by a farmer who found the bird at his farm. There were similar small nodules on the eyelids and beak. The fractured bone ends had become necrotized. The buzzard was euthanized. On histopathological examination of nodules, large, eosinophilic intracytoplasmic inclusion bodies (Bollinger bodies) were seen. Avipox was diagnosed on the basis of the typical gross and microscopic features.

Key Words: Common buzzard, *Buteo buteo*, avipox, Bollinger bodies, hawk, raptorial birds

Bir Şahinde (*Buteo buteo*) Çiçek Hastalığı

Özet: Akdeniz Üniversitesi Burdur Veteriner Fakültesine, bir çiftçinin tarlasında tesadüfen bulunduğu bir şahin bacağına kırık ve ayaklar üzerinde şekillenmiş nodüler kitleler sebebiyle getirildi. Benzeri nodüler yapıların göz kapakları ve gaga üzerinde de olduğu gözlemlendi. Kırık kemik uçlarının nekroze olduğu görüldü. Şahine ötenazi uygulandı. Nodüler kitlelerin histopatolojik yoklamasında büyük, eozinofilik, intrasitoplazmik inklüzyonlar (Bollinger cisimcikleri) gözlemlendi. Tipik makroskobik ve mikroskobik bulgular ile çiçek hastalığı tanısı konuldu.

Anahtar Sözcükler: Şahin, *Buteo buteo*, çiçek hastalığı, Bollinger cisimcikleri, yırtıcı kuşlar

Introduction

Avipox virus affects many bird species including raptors (1-5). This disease is relatively common in captive and free-living falcons (4,6,7). Avian pox is a contagious disease and is commonly characterized by the production of nodular cutaneous lesions on the feet, cere or eyelids (1). Diagnosis is confirmed on histological examination of lesions by observing characteristic intracytoplasmic, eosinophilic inclusion bodies (Bollinger bodies) (3-5,7,8). Transmission of avipox viruses occurs by insect biting, fighting and pecking, and through contaminated food and water (9,10).

The aim of this report is to describe a case of avipox infection in a common buzzard. Although avipox infection is common in raptors, this is the first avipox report in raptors in Turkey.

Materials and Methods

A farmer brought an adult, male common buzzard to Akdeniz University Burdur Veterinary Faculty because of

a leg fracture and multiple proliferative cutaneous nodular lesions on his feet. The bird could not move due to metatarsal bone fracture. On clinical examination necrosis and osteomyelitis were observed at the broken bone ends. The bird could not use his claws because of the nodules and similar lesions were also seen on the eyelids and beak. The bird appeared weak, pale and slightly thin. Because of a poor prognosis the buzzard was euthanized and necropsy was performed. A blood sample was taken for microbiological examination.

At necropsy, tissue samples were collected from all visceral organs (lungs, heart, kidneys, liver, spleen, proventriculus, gizzard, gut and brain) and from the nodules of the feet and fixed in 10% buffered formalin for histopathological examination. These samples were routinely processed into paraffin and 7 µm slides were stained with hematoxylin and eosin.

Results

At necropsy, no pathological changes were observed in the visceral organs.

The nodules were multiple, hard brown masses of different diameters (0.5-3.5 cm). They were diffusely covering the toes (Figure 1).

On histopathological examination, there were hyperkeratosis, marked epidermal hyperplasia and ballooning degeneration of keratinocytes, many of which contained eosinophilic intracytoplasmic inclusion bodies (Figure 2). The epidermis was ulcerated and secondary bacterial infections were seen in some areas. The superficial dermis was hyperplastic, well vascularized and contained a marked infiltration of heterophils. No bacteria were isolated from the blood.

Discussion

Poxviruses are environmentally resistant viruses that cause disease in a large variety of animals. Avipox infections occur as dry pox, wet pox and systemic form in

birds (8). In raptors the dry pox-lesions are the most commonly described form and the wet form is rare (5). Dry pox-lesions affect primarily the non-feathered areas of the skin and lesions are often seen on the face, eyelids and feet. Proliferative scab-like lesions can develop and can become secondary infected by bacteria (8). In the present case, the lesions were very similar to the dry form and were localized primarily on the feet. On microscopic examination, bacterial colonies were seen in the epidermis in some areas.

The mortality from this disease is attributed to the bird's inability to capture prey because of the severity of its foot lesions and blood loss (7). At necropsy, the bird was observed to be in a very poor condition and there was no food in its gizzard. This was because of the inability to hunt, due to both the nodules on feet and the leg fracture.



Figure 1. Avipox nodules on the toes, eyelid and beak.

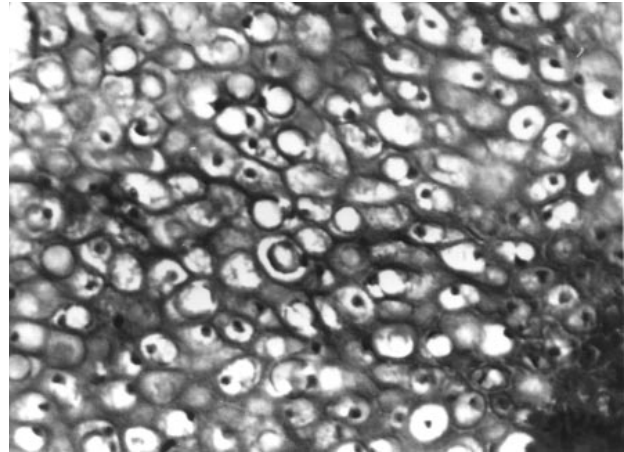


Figure 2. Microscopical appearance of nodules and intracytoplasmic Bollinger bodies H.E. x 400.

References

1. Tripathy, D.E., Reed, W.M.: Pox. in Diseases of Poultry. Iowa, Iowa State University Press. 1997; 643-659.
2. Cooper, J.E.: Two cases of pox in recently imported Peregrine falcons (*Falco peregrinus*). Vet. Rec. 1969; 85, 683-684.
3. Hill, J.R.: Epornitic of pox in a wild bird population. J. Am. Vet. Med. Assoc. 1977; 171 (9): 993-994.
4. Samour J.H., Cooper, J.E.: Avian pox in birds of prey (Order Falconiformes) in Bahrain. Vet. Rec. 1993; 132, 343-345.
5. Schoemaker, N.J., Dorrestein, G.M., Lumeij, J.T.: An avipoxvirus infection in a goshawk (*Accipiter gentilis*). Avian Pathol. 1998; 27, 103-106.
6. Morishita, T.Y., Fullerton, A.T., Lowenstine, L.J., Agardner, I., Brooks, D.L.: Morbidity and mortality in free living raptorial birds of Northern California: A retrospective study, 1983-1994. J. Avian Med. Surg. 1998; 12 (2): 78-81.

7. Morishita, T.Y., Pyone, P.A., Brooks, D.L.: A survey of raptorial birds. *J. Avian Med. Surg.* 1997; 11 (2): 77-92.
8. Spenser, E.L.: Common infectious disease of psittacine birds seen in practice, *Vet. Clin. North. Am. Small. Anim. Pract.* 1991; 21 (6): 1213-1230.
9. Perry, R.A., Gill, J., Cross, G.M.: Disorders of the Avian Integument, *Vet. Clin. North. Am. Small. Anim. Pract.* 1991; 21 (6): 1307-1327.
10. Barnes, H.J.: Disease of quail, *Vet. Clin. North. Am. Small. Anim. Pract.* 1991; 21 (6): 1109-1145.