

1-1-2013

Sarcoidosis and denim sandblasting: a case report

HÜLYA UZKESER

SALİHA KARATAY

KADİR YILDIRIM

SUAT EREN

Follow this and additional works at: <https://journals.tubitak.gov.tr/medical>



Part of the [Medical Sciences Commons](#)

Recommended Citation

UZKESER, HÜLYA; KARATAY, SALİHA; YILDIRIM, KADİR; and EREN, SUAT (2013) "Sarcoidosis and denim sandblasting: a case report," *Turkish Journal of Medical Sciences*: Vol. 43: No. 2, Article 29.

<https://doi.org/10.3906/sag-1207-92>

Available at: <https://journals.tubitak.gov.tr/medical/vol43/iss2/29>

This Article is brought to you for free and open access by TÜBİTAK Academic Journals. It has been accepted for inclusion in Turkish Journal of Medical Sciences by an authorized editor of TÜBİTAK Academic Journals. For more information, please contact academic.publications@tubitak.gov.tr.

Sarcoidosis and denim sandblasting: a case report

Hülya UZKESER^{1,*}, Saliha KARATAY², Kadir YILDIRIM², Suat EREN³

¹Department of Physical Medicine and Rehabilitation, Regional Education and Research Hospital, Erzurum, Turkey

²Department of Physical Medicine and Rehabilitation, Faculty of Medicine, Atatürk University, Erzurum, Turkey

³Department of Radiology, Faculty of Medicine, Atatürk University, Erzurum, Turkey

Received: 25.07.2012 • Accepted: 14.09.2012 • Published Online: 15.03.2013 • Printed: 15.04.2013

Abstract: In this case report we present a rare case of sarcoidosis associated with denim sandblasting. A 33-year-old male patient was admitted to our clinic with pain in his shoulders, elbows, wrists, and hips, which had started 5 months earlier. His medical history showed that he had been working in denim sandblasting for the last 4 years. Sacroiliac compression and FABER tests were both positive. Laboratory analysis reported an erythrocyte sedimentation rate of 43 mm/h and serum C-reactive protein of 11 mg/dL. Bilateral hilar and mediastinal multiple lymph nodes of about 2 cm and bilateral parenchymal nodular opacities were observed in the lungs upon computerized tomography. The serum angiotensin-converting enzyme level was 190.10 U/L and 24-h urine Ca was 370.5 mg. We diagnosed sarcoidosis in the patient and we began a steroid therapy of 30 mg/day. Improvements were observed in the patient at the clinic during the following 3-month period. A reduction was identified in the size and number of mediastinal lymph nodes in the follow-up tomography.

Key words: Sandblasting, lymphadenopathy, sarcoidosis

1. Introduction

Sarcoidosis is a multisystem disorder of unknown cause, characterized by noncaseating granulomas (1). The lungs and lymphatic system are predominantly affected. However, the eyes, skin, joints, brain, and heart may also be affected. Sarcoidosis patients are mostly admitted to hospital with a dry cough, eye or skin manifestations, enlarged peripheral lymph nodes, fever, night sweats, and erythema nodosum. Joint findings are rarer than the other symptoms. Clinical features of joint involvement are found in 25% of cases at presentation. The frequency of clinical muscle and bone involvement at presentation is low. Articular involvement may be acute or chronic and persistent (1,2). The most common form of joint involvement is an acute polyarthritis/peri-arthritis. The arthritis may be migratory and intermittent. Abnormal metabolism of vitamin D₃ within granulomatous lesions is seen in the laboratory. Hypercalcemia is present in about 11% and hypercalciuria in about 36% of cases (2). Serum angiotensin-converting enzyme (ACE) is believed to reflect the disease activity. The diagnosis of sarcoidosis is based on the clinical and radiologic findings, which are then supported by histologic evidence. As far as we know, the case presented here is the first reported case of sarcoidosis developed in a denim sandblaster anywhere in the literature.

2. Case report

A 33-year-old male patient was admitted to our clinic with pain in his shoulders, elbows, wrists, and hips, which had started 5 months previously. He had joint stiffness in the mornings, which was lasting for 25 min. The fact that for the last 4 years his work involved denim sandblasting was reported in his medical history. The range of motion was normal in his shoulders, elbows, wrist, and hips but he had minimal pain in these joints upon examination. Sacroiliac compression and FABER tests were both positive. Laboratory analysis showed an erythrocyte sedimentation rate of 43 mm/h and serum C-reactive protein of 11 mg/dL. Tests for anti-CCP antibodies and rheumatoid factor were negative. Bilateral sacroiliitis was observed on his whole-body bone scintigraphy, prominently on the right side. The respiratory sounds in both lungs were coarsening. A posteroanterior lung X-ray showed bilateral hilar enlargement and a widespread fine nodular pattern (Figure 1A). Bilateral hilar and mediastinal multiple lymph nodes of about 2 cm (Figure 1B) and bilateral parenchymal nodular opacities (Figure 1C) were observed in the lungs upon computerized tomography (CT). His serum ACE level was 190.10 U/L and 24-h urine Ca was 370.5 mg. Sputum smear and purified protein derivative (PPD) tests were negative. The patient did not agree to bronchoscopy

* Correspondence: drhulyauzkeser@gmail.com

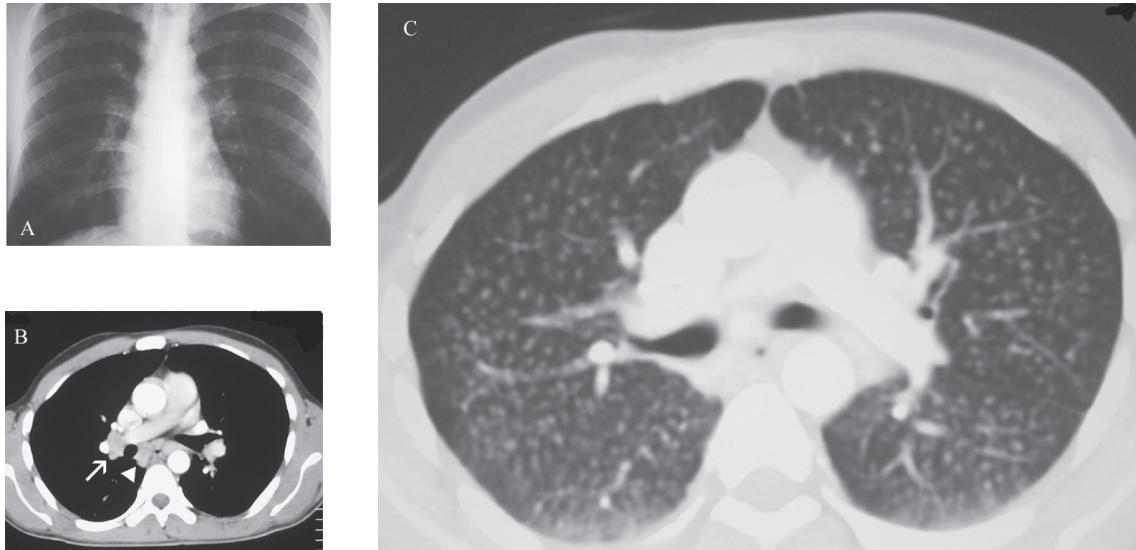


Figure 1. A) Posteroanterior chest X-ray; B) hilar lymph nodes (white arrow) and mediastinal lymph nodes (arrowhead) in CT; C) millimetric nodular lesions in CT.

or biopsy. We diagnosed sarcoidosis according to clinical, laboratory, and radiologic findings. We began a steroid therapy of 30 mg/day.

Improvements were observed in the patient at the clinic in the following 3-month period. A reduction was identified in the size and number of mediastinal lymph nodes, but bilateral parenchymal nodular lesions persisted in the follow-up CT (Figures 2A and 2B). Thus, CT confirmed for us the presence of disseminated small nodular sarcoidosis.

3. Discussion

Sarcoidosis affects primarily young and middle-aged adults. There is consensus about its pathology but the etiology of the disease is not clearly understood. In a multicenter study about sarcoidosis, very little evidence regarding environmental and occupational factors was obtained (3). A common hypothesis is that various effects, like those of infectious or unidentified environmental antigens, could trigger an immune reaction in genetically susceptible hosts (4). In this case, the patient had been working in denim sandblasting for 4 years. He was exposed to silica. Mostly, the lungs and lymphatic system are involved when sarcoidosis occurs. Other areas that may be involved are the liver, eyes, heart, kidney, skeletal system, and skin. Pulmonary fibrosis is the major cause of morbidity and mortality. Asymptomatic lymphadenopathy alone or both lymphadenopathy and pulmonary infiltrations are the main manifestations of sarcoidosis. In radiology, the most common findings are bilateral hilar lymphadenopathy and parenchymal abnormalities. In the lungs, sarcoid granulomas are typically settled around the lymphatic vessels. Typical CT findings of sarcoidosis include irregular thickening of the interstitium and multiple small

nodules in the peribronchovascular region (1). However, 25% to 30% of cases may show differences from the typical findings, making diagnosis difficult. In the present case, the patient had bilateral hilar enlargement and a widespread fine nodular pattern in his lung radiography. Bilateral hilar and mediastinal multiple lymph nodes of about 2 cm and bilateral parenchymal nodular opacities were observed in his lungs upon CT. Thus, the aforementioned findings suggested sarcoidosis to us.

Arthritis is relatively common in sarcoidosis. Two types of arthropathy have been described: the acute transient and chronic forms. While the large joints are affected in the acute form, multiple joints, especially in the knees, ankles, shoulders, and wrists and also the small joints of the hands and feet, can also be affected in the chronic form (5). These clinical presentations may be misdiagnosed as reactive arthritis, rheumatoid arthritis, or spondylarthropathies.

Sacroiliitis is an inflammation of the sacroiliac joint. Sacroiliitis causes pain and stiffness during exercise and back stiffness, particularly after resting and in the morning. Sacroiliitis is more often seen in sarcoidosis patients compared with the general population (5). Isotope bone scanning and magnetic resonance scanning can be used to assess sacroiliitis. Isotope bone scanning is more sensitive to active inflammation at the sacroiliac joints and determines the sacroiliitis before erosive changes occur (5). In this case, bilateral sacroiliitis was observed in his bone scintigraphy.

Working with denim sandblasting appears to be a new problem in developing countries. Inattention to working conditions and the results of inadequate protection cause silicosis, which affects the respiratory tract (6). Silicosis is a kind of pneumoconiosis that is caused by inhalation of crystalline silica particles. The diagnosis of silicosis is

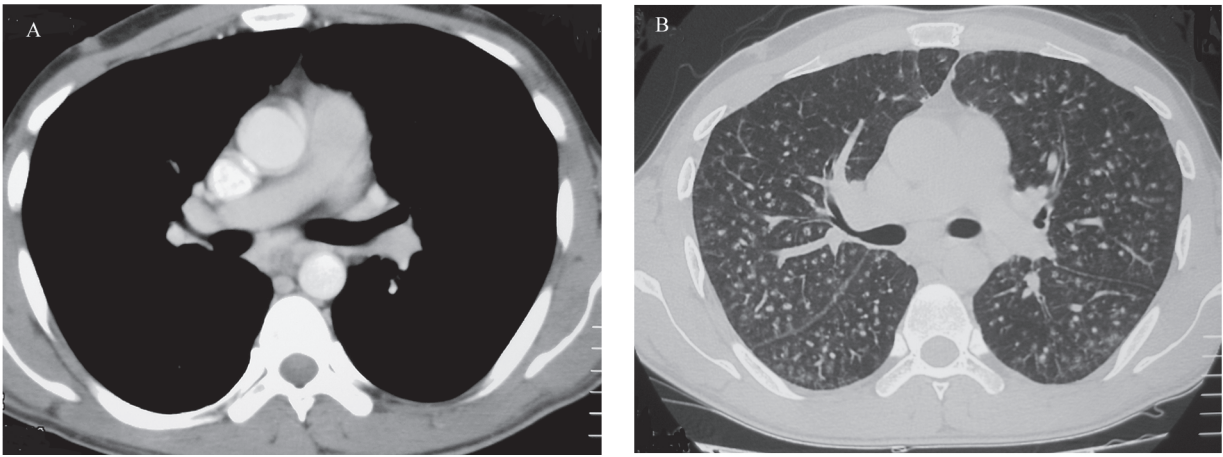


Figure 2. A) Hilar and mediastinal lymph nodes in follow-up CT; B) parenchymal nodular lesions in follow-up CT.

based on a history of exposure to silica. Generally, a chest X-ray is sufficient for diagnosis. The characteristic X-ray evidence of silicosis includes diffuse multiple nodules, smaller than 10 mm, which are located in the superior and posterior regions of the lungs. CT of the chest should only be used in cases where there is doubt about the clinical or radiological results (7). Lymphadenopathy, calcification, and progressive massive fibrosis are the radiological findings of classic silicosis. Although these findings are not very prominent, pleural involvement is higher in cases with silicosis due to denim sandblasting (8). However, we could rule out silicosis because of the CT images. We did not observe calcifications and pleural involvement in the present case.

Silica-exposed workers, with or without silicosis, are at increased risk of tuberculosis. Silica molecules can stimulate the immune response of the lungs, impair the function of pulmonary macrophages, and cause macrophage apoptosis (9). The incidence of tuberculosis is higher in workers exposed to dust than in workers not

exposed (7). Sputum and urine acid-fast bacilli tests were negative in our case. Besides these, a PPD test was also negative. We thus ruled out tuberculosis.

Abnormal metabolism of vitamin D₃ may be also seen with sarcoidosis. Hypercalciuria is presented more often than hypercalcemia. Hypercalcemia and hypercalciuria can also lead to nephrocalcinosis and chronic renal failure (2). Serum ACE levels can be twice as high as the normal upper limit. Serum ACE is believed to reflect disease activity, but it is increased in about 60% of cases (10). Increased serum ACE levels and hypercalcemia in this case supported the diagnosis of sarcoidosis. In addition, clinical improvements in the patient following a 3-month period and a reduction in the size and number of mediastinal lymph nodes upon follow-up CT also supported our diagnosis.

In conclusion, sarcoidosis should be particularly considered in those patients with joint involvement, even though the most common lung problem in denim sandblasting is known to be silicosis.

References

1. Sweiss NJ, Patterson K, Sawaqed R, Jabbar U, Korsten P, Hogarth K et al. Rheumatologic manifestations of sarcoidosis. *Semin Respir Crit Care Med* 2010; 31: 463–73.
2. Karnchanasorn R, Sarikonda M, Aldasouqi S, Gossain VV. Severe hypercalcemia and acute renal failure: an unusual presentation of sarcoidosis. *Case Report Med* 2010; 2010: 423659.
3. Newman LS, Rose CS, Bresnitz EA, Rossman MD, Barnard J, Frederick M et al. A case control etiologic study of sarcoidosis: environmental and occupational risk factors. *Am J Respir Crit Care Med*. 2004; 170: 1324–30.
4. Baughman RP, Lower EE, du Bois RM. Sarcoidosis. *Lancet* 2003; 361: 1111–8.
5. Erb N, Cushley MJ, Kassimos DG, Shave RM, Kitas GD. An assessment of back pain and the prevalence of sacroiliitis in sarcoidosis. *Chest* 2005; 127: 192–6.
6. Akgun M, Mirici M, Ucar EY, Kantarci M, Araz O, Gorguner M. Silicosis in Turkish denim sandblasters. *Occup Med (Lond)* 2006; 56: 554–8.
7. Barboza CE, Winter DH, Seiscento M, Santos Ude P, Terra Filho M. Tuberculosis and silicosis: epidemiology, diagnosis and chemoprophylaxis. *J Bras Pneumol* 2008; 34: 959–66.
8. Alper F, Akgun M, Onbas O, Araz O. CT findings in silicosis due to denim sandblasting. *Eur Radiol* 2008; 18: 2739–44.
9. Doganay S, Gocmen H, Yikilmaz A, Coskun A. Silicosis due to denim sandblasting in young people: MDCT findings. *Eurasian J Med* 2010; 42: 21–3.
10. Kruit A, Grutters JC, Gerritsen WB, Kos S, Wodzig WK, van den Bosch JM et al. ACE I/D-corrected Z-scores to identify normal and elevated ACE activity in sarcoidosis. *Respir Med* 2007; 101: 510–5.