

1-1-2013

## Do dynamic condylar screw-plates lead to iatrogenic fracture?

MAHMUT NEDİM AYTEKİN

FATİH KÜÇÜKDURMAZ

İSMAİL ÇELİK

ALİ FIRAT ESMER

FUAT AKPINAR

Follow this and additional works at: <https://journals.tubitak.gov.tr/medical>



Part of the [Medical Sciences Commons](#)

---

### Recommended Citation

AYTEKİN, MAHMUT NEDİM; KÜÇÜKDURMAZ, FATİH; ÇELİK, İSMAİL; ESMER, ALİ FIRAT; and AKPINAR, FUAT (2013) "Do dynamic condylar screw-plates lead to iatrogenic fracture?," *Turkish Journal of Medical Sciences*: Vol. 43: No. 4, Article 6. <https://doi.org/10.3906/sag-1208-44>  
Available at: <https://journals.tubitak.gov.tr/medical/vol43/iss4/6>

This Article is brought to you for free and open access by TÜBİTAK Academic Journals. It has been accepted for inclusion in Turkish Journal of Medical Sciences by an authorized editor of TÜBİTAK Academic Journals. For more information, please contact [academic.publications@tubitak.gov.tr](mailto:academic.publications@tubitak.gov.tr).

## Do dynamic condylar screw-plates lead to iatrogenic fracture?

Mahmut Nedim AYTEKİN<sup>1\*</sup>, Fatih KÜÇÜKDURMAZ<sup>2</sup>, İsmail ÇELİK<sup>3</sup>,  
Ali Fırat ESMER<sup>4</sup>, Fuat AKPINAR<sup>5</sup>

<sup>1</sup>Department of Orthopedics and Traumatology, Yıldırım Beyazıt University, Ankara Atatürk Training and Research Hospital, Ankara, Turkey

<sup>2</sup>Department of Orthopedics and Traumatology, Faculty of Medicine, Bezmialem Vakıf University, İstanbul, Turkey

<sup>3</sup>Orthopedics and Traumatology Clinic, Afşin State Hospital, Kahramanmaraş, Turkey

<sup>4</sup>Department of Anatomy, Faculty of Medicine, Ankara University, Ankara, Turkey

<sup>5</sup>Department of Orthopedics and Traumatology, Health Research and Practice Center, Abant İzzet Baysal University, Bolu, Turkey

Received: 11.08.2012 • Accepted: 30.10.2012 • Published Online: 29.07.2013 • Printed: 19.08.2013

**Aim:** Although many anatomic, morphologic, and radiologic studies have been carried out for the femur, as for all other bones of the skeletal system, we could not find any morphometric studies useful for orthopedic surgeons who want to understand the effects of dynamic condylar screw-plates (DCS-Plates) on the distal femur. The aim of this study was to determine the amount of cortex loss in the distal femur when inserting a DCS-Plate.

**Materials and methods:** The lateral cortex width of 125 adult, dry, and grossly intact right and left cadaver femora was measured for the region of the femur in which the DCS-Plate was applied, and the results were analyzed statistically.

**Results:** The mean value of the lateral cortex width (DLCW =  $\alpha$ ) of the femora was 33.5 mm (range: 44.67–24.49 mm). While inserting the DCS-Plate, 38.04% (range: 30.43%–46.09%) of the mean width of the lateral cortex was lost.

**Conclusion:** We demonstrated the amount of lateral cortex loss in the femur while inserting a DCS-Plate. If the DCS-Plate is inserted more proximally to its original entry point, the risk of fracture at the supracondylar region increases due to the defect at the lateral cortex.

**Key words:** DCS-Plate, iatrogenic fracture, lateral cortex

### 1. Introduction

The morbidity of patients in orthopedic surgery has been significantly decreased owing to new technological developments of the implants that are being used for different problems of the skeletal system. Both soft and bone tissues may be damaged significantly while installing these implants. This is why orthopedic surgeons consider many factors when choosing implants for the fixation of bones. Distal femoral fractures continue to be a challenge for orthopedic surgeons. A number of treatment modalities for distal femur fractures have been reported in the literature, including dynamic condylar screw-plate (DCS-Plates) (1–4). Although many anatomic, morphologic, and radiologic studies have been carried out for femurs, as for all other bones of the skeletal system, we could not find any morphometric study useful for orthopedic surgeons wishing to understand DCS-Plate effects on the distal femur (5–7).

In this study, lateral cortex measurements were taken for the region of the femur in which the DCS-Plate was

applied and the results were analyzed statistically. The results are useful for orthopedic surgeons who wish to apply this plate more consciously. The aim of this study was to determine the amount of cortex loss in the distal femur when inserting a DCS-Plate.

### 2. Materials and methods

The investigation was performed on 125 adult, dry, and grossly intact right and left cadaver femora in the Ankara University Department of Anatomy. We obtained these bones from the Ankara University Department of Anatomy. The race, sex, and age of the cadavers were not known. Right and left femora were enumerated.

The distal lateral cortex width (DLCW =  $\alpha$ ) of the femur was measured with an electronic vernier caliper in the region where a 12-mm-diameter hole is usually opened while inserting a 95° DCS-Plate (Figure 1). This region was approximately 1.5 cm proximal from the most prominent part of the lateral femoral epicondyle (Figure 2).

\* Correspondence: nedimaytekin@hotmail.com

Maximum, minimum, mean, and standard deviation values of the measurements were calculated using Microsoft Excel 2007. These values were compared with the diameter of the hole that was opened while inserting the DCS-Plate. The value of  $\beta$  was calculated by the percentage of the diameter of this hole to the width of the lateral cortex.

**3. Results**

The values of the distal lateral femoral cortex width where the barrel portion of the 95° DCS-Plates were inserted are given in Table 1.

The mean value of the lateral cortex width (DLCW =  $\alpha$ ) of the femora was 33.5 mm (maximum: 44.67 mm, minimum: 24.49 mm, and standard deviation: 3.0336) (Table 2).

**Table 1.** The values of the distal lateral femoral cortex width where the barrel portion of the 95° DCS-Plate was inserted.

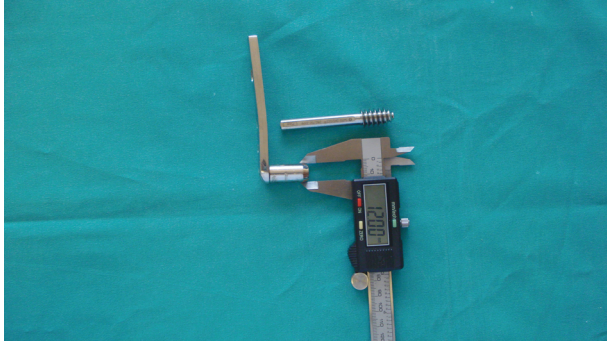
Left femora		Right femora	
No.	A (mm)	No.	A (mm)
1	28.09	1	36.11
2	34.10	2	34.48
3	34.30	3	35.51
4	32.21	4	32.43
5	32.71	5	37.54
6	31.51	6	36.19
7	34.30	7	27.12
8	31.71	8	30.61
9	33.57	9	34.39
10	33.95	10	36.61
11	32.71	11	33.13
12	34.17	12	34.24
13	30.24	13	27.90
14	35.17	14	34.77
15	34.47	15	33.38
16	36.02	16	35.13
17	33.68	17	32.41
18	30.66	18	32.11
19	33.84	19	32.12
20	34.17	20	36.58
21	34.28	21	27.48
22	32.88	22	35.13
23	33.94	23	29.24
24	32.97	24	32.60
25	35.55	25	31.46
26	37.41	26	33.23
27	32.87	27	36.40
28	33.28	28	28.03
29	32.91	29	33.04
30	30.94	30	27.56
31	28.45	31	32.11

32	33.97	32	30.04
33	34.02	33	31.40
34	33.94	34	34.49
35	32.84	35	36.25
36	34.21	36	30.78
37	35.75	37	32.66
38	35.12	38	29.06
39	37.83	39	27.14
40	32.78	40	32.70
41	31.45	41	28.94
42	34.48	42	30.67
43	38.51	43	33.84
44	36.1	44	41.07
45	33.45	45	31.37
46	37.11	46	36.37
47	30.34	47	33.46
48	36.32	48	29.00
49	34.7	49	36.97
50	31.52	50	33.10
51	32.94	51	34.56
52	34.85	52	32.97
53	33.39	53	37.33
54	32.67	54	27.95
55	24.49	55	34.42
56	35.67	56	32.49
57	38.22	57	31.77
58	38.33	58	35.70
59	26.54	59	32.52
60	36.78	60	33.54
		61	32.88
		62	41.35
		63	43.56
		64	38.23
		65	44.67

No.: Number of femur. A: The value of the distal lateral cortex width where the barrel portion of the 95° DCS-Plate was inserted.

**Table 2.** Values of the distal lateral cortex width (DLCW =  $\alpha$ ) of the femora.

	Maximum	Minimum	Mean	SD
DLCW = $\alpha$	44.67 mm	24.49 mm	33.50136 mm	3.0336



**Figure 1.** Demonstrative measurement of the barrel portion of the DCS-Plate with an electronic vernier caliper.



**Figure 2.** Distal lateral cortex width (DLCW =  $\alpha$ ) of the femur measured by an electronic vernier caliper at 1.5 cm proximal of the most prominent part of the lateral femoral epicondyle.

Moreover, our results demonstrated that while inserting a DCS-Plate, 38.04% of the mean width of the lateral cortex was lost (range: 30.43% to 46.09%) (Table 3).

**References**

1. Dar GN, Tak SR, Kangoo KA, Halwai MA. Bridge plate osteosynthesis using dynamic condylar screw (DCS) or retrograde intramedullary supracondylar nail (RIMSN) in the treatment of distal femoral fractures: comparison of two methods in a prospective randomized study. *Ulus Travma Acil Cerrahi Derg* 2009; 15: 148–53.

**Table 3 .**  $\beta$  values; percentage of the diameter of the barrels of the DCS-Plate to the lateral cortex width.

	Maximum	Minimum	Mean
$\beta$ values	46.09%	30.43%	38.04%

**4. Discussion**

Although many anatomic, morphologic, and radiologic studies have been carried out on the distal femur, we could not find any morphometric studies that would be useful for orthopedic surgeons who wanted to understand DCS-Plate effects on the distal femur. This is why we could not compare the results of our study with any others.

Because there is no study that shows the amount of cortex loss when a DCS-Plate is inserted, our study is important to help prevent fractures while installing the plates. Although we cannot determine the amount of loss that leads to fracture, it is important to demonstrate the amount of lateral cortex loss when inserting this plate. Our results demonstrated that when inserting a DCS-Plate, 38.04% of the mean width of the lateral cortex is lost. This percentage may increase up to 46.09%.

However, because the lateral cortex narrows in the supracondylar region, the DCS-Plate should not be inserted proximal to the region in which it is to be fixed. If the plate is inserted more proximally to its original entry point, the risk of fracture at the supracondylar region will increase due to the defect at the lateral cortex.

One criticism of our study would be to point out that it would have been better had we known the cadavers' epidemiologic data (8).

We demonstrated the amount of lateral cortex loss in the femur while inserting a DCS-Plate in this study. Iatrogenic damage is an important topic in all branches of the modern medicine (9). Surgeons must be very careful not to damage the anterior and posterior cortices when opening a hole in the lateral cortex for a DCS-Plate. Orthopedic surgeons who read this article will probably operate more consciously while using these plates.

2. Kao FC, Tu YK, Su JY, Hsu KY, Wu CH, Chou MC. Treatment of distal femoral fracture by minimally invasive percutaneous plate osteosynthesis: comparison between the dynamic condylar screw and the less invasive stabilization system. *J Trauma* 2009; 67: 719–26.

3. Heiney JP, Barnett MD, Vrabec GA, Schoenfeld AJ, Baji A, Njus GO. Distal femoral fixation: a biomechanical comparison of trigen retrograde intramedullary (i.m.) nail, dynamic condylar screw (DCS), and locking compression plate (LCP) condylar plate. *J Trauma* 2009; 66: 443-9.
4. Gurkan V, Orhun H, Doganay M, Salioglu F, Ercan T, Dursun M et al. Retrograde intramedullary interlocking nailing in fractures of the distal femur. *Acta Orthop Traumatol Turc* 2009; 43: 199-205.
5. Eckhoff DG, Montgomery WK, Kilcoyne RF, Stamm ER. Femoral morphometry and anterior knee pain. *Clin Orthop Relat Res* 1994; 302: 64-8.
6. Murshed KA, Cicekcibasi AE, Karabacakoglu A, Seker M, Ziyilan T. Distal femur morphometry: a gender and bilateral comparative study using magnetic resonance imaging. *Surg Radiol Anat* 2005; 27: 108-12.
7. Li K, Langdale E, Tashman S, Harner C, Zhang X. Gender and condylar differences in distal femur morphometry clarified by automated computer analyses. *J Orthop Res* 2012; 30: 686-92.
8. Ugurlu M, Yilmaz S, Deveci A, Unlu S, Tunç B, Ustü Y et al. The epidemiologic characteristics of patients that underwent surgery for hip fracture. *Turk J Med Sci* 2012; 42: 299-305.
9. Bagış S, Adam M, Leblebici ÜB, Karataş M, Güven AZ, Çeliker AR. Sciatic nerve injury due to intramuscular injection: electrophysiological findings and one-year follow-up. *Turk J Med Sci* 2012; 42: 913-7.