

1-1-2003

Immune Deficiency and Cryptosporidiosis in Rats

AHMET ÜNER

TONAY İNCEBOZ

MEDİHA UYSALCI

HANDE DAĞCI

Follow this and additional works at: <https://journals.tubitak.gov.tr/veterinary>



Part of the [Animal Sciences Commons](#), and the [Veterinary Medicine Commons](#)

Recommended Citation

ÜNER, AHMET; İNCEBOZ, TONAY; UYSALCI, MEDİHA; and DAĞCI, HANDE (2003) "Immune Deficiency and Cryptosporidiosis in Rats," *Turkish Journal of Veterinary & Animal Sciences*: Vol. 27: No. 5, Article 21. Available at: <https://journals.tubitak.gov.tr/veterinary/vol27/iss5/21>

This Article is brought to you for free and open access by TÜBİTAK Academic Journals. It has been accepted for inclusion in Turkish Journal of Veterinary & Animal Sciences by an authorized editor of TÜBİTAK Academic Journals. For more information, please contact academic.publications@tubitak.gov.tr.

Immune Deficiency and Cryptosporidiosis in Rats

Ahmet ÜNER

Department of Parasitology, Faculty of Medicine, Ege University, Bornova, İzmir - TURKEY

Tonay İNCEBOZ

Department of Parasitology, Faculty of Medicine, Dokuz Eylül University, İnciraltı, İzmir - TURKEY

Mediha UYSALCI, Hande DAĞCI

Department of Parasitology, Faculty of Medicine, Ege University, Bornova, İzmir - TURKEY

Received: 20.06.2002

Abstract: This study was intended to establish whether there is any relation between immune deficiency and cryptosporidiosis by using an animal model.

Forty *Rattus norvegicus* rats obtained from the Experimental Animal Laboratories of the Ege University Faculty of Medicine were divided into two groups. The first group (n = 20) received corticosteroids (dexamethasone, 1.5 mg, subcutaneously, twice weekly) for eight weeks for immunosuppression, while the control group (n = 20) received no treatment. Drinking water was supplemented with tetracycline (500 mg/L) to avoid secondary infections. The animals were kept in groups of five in separate cages under the same environment and conditions.

All the rats were sacrificed following the last injection, and preparations were made from the intestinal materials. All preparations were stained with Kinyoun acid-fast, modified Kinyoun acid-fast and Auramine, and were examined under light microscope.

There was no detectable change in appearance and movement in the control group. However, a significant alteration was observed in the group that received corticosteroids (Fisher's exact test, $P < 0.05$).

The results indicate that cryptosporidiosis and other opportunistic infections may represent a threat in immune deficiency situations.

Key Words: Cryptosporidiosis, immune deficiency, dexamethasone

Ratlarda İmmun Yetmezlik ve Cryptosporidiosis

Özet: Bu arařtırmada immün yetmezlik ve *Cryptosporidium* spp. infeksiyonları arasında bir iliřkinin bulunup bulunmadığının arařtırılması amaçlanmıřtır.

Deney modeli olarak sıçanlar (*Rattus norvegicus*) seçilmiřtir. Bu amaçla Ege Üniversitesi, Tıp Fakültesi Deney Hayvanları Yetiřtirme Ünitesinden 40 adet sıçan alınmıřtır. Hayvanlar 20'şerli olarak iki gruba ayrılmıřtır. I. grup arařtırma, II. grup kontrol grubu olarak kullanılmıřtır. I. gruptaki hayvanlara immünyüpresyon geliřtirmek amacıyla 2 ay boyunca haftada 2 kez subkutan olarak kortikosteroid (dekzametazon 1,5 mg) verilmiřtir. İkincil infeksiyonların önlenmesi amacıyla içme sularına tetrasiklin (500 mg/l) konmuřtur. Kontrol grubundaki hayvanlara ise herhangi bir ilaç verilmemiřtir. Arařtırma ve kontrol gruplarındaki hayvanlar aynı laboratuvarında, farklı kafeslerde bulundurulmuř ve aynı diyetle beslenmiřtir.

Her iki gruptaki hayvanlar 8. hafta sonunda öldürölmüř ve bağırsak içeriklerinden preparatlar hazırlanmıřtır. Preparatlar Kinyoun-asit fast, Modifiye Kinyoun-asit fast ve Auramin yöntemleri ile boyanmıř ışık mikroskopunda incelenmiřtir.

Kontrol gurubunun hareketlerinde ve görünümünde hiç bir deęiřiklik olmamasına karřın kortikosteroid alan grupta belirgin deęiřiklikler gözlenmiřtir (Fisher'in testi, $P < 0,05$).

Alınan sonuçlar herhangi bir nedenle immunitesi baskı altında tutulan veya immün yetmezlięi olanların cryptosporidiosis tehdidi altında bulduklarını göstermiřtir.

Anahtar Sözcükler: Cryptosporidiosis, immün yetmezlik, dekzametazon

Introduction

Cryptosporidium spp. were initially isolated in the gastric epithelial cells of mice by Clarke in 1895. He

described the former as yeast clusters on those cells. They were later identified as a new species by Tyzzer in 1907 (1,2).

There are 20 different species in the genus *Cryptosporidium*. *C. parvum* and *C. muris* are found in rodents and mammals' gut/respiratory tracts, but *C. baile* is found in birds' *bursa of fabricus* and in immunosuppressed patients. It is reported to be transmitted by oocysts, and to spread from animals to other animals, animals to humans and humans to humans. The examination of samples obtained from feces, sputum and bile determines the diagnosis (3,4).

Although cryptosporidiosis is found all around the world, it is particularly widespread in underdeveloped countries. It is known that this infection is found in patients with immunosuppression, and that it causes severe enteritis. It is reported that cryptosporidiosis is frequently seen in farmers and tourists, and also in immunodeficient patients. Children are more vulnerable than adults (4,5).

Studies performed on immunosuppressed laboratory animals (immunosuppressed/athymic mice, rats, adult hamsters and primates) have demonstrated the relation between the immune system and cryptosporidiosis (6-9). In these animals with T cell deficiency cryptosporidiosis is prolonged and severe: moreover, the shedding of oocytes increases (6,7,9-14).

In a selectively depleted adult BALB/c mouse model, CD₄⁺ T lymphocytes and interferon gamma (IFN γ) are required to prevent the onset of cryptosporium infection. It is noted that adult BALB/c mice shed larger numbers of oocytes when CD₈⁺ and CD₄⁺ T lymphocytes are deficient (9,14).

IgM, IgG and IgA play an important role in the restriction of primary cryptosporidiosis in immunocompetent humans and animals. They also protect against secondary infections (2).

As indicated above, all the previous studies were carried out by experimental exposure to the specific pathogen. Our study was intended to investigate the relation between immunodeficiency and naturally occurring cryptosporidiosis in immunocompromised rats.

Materials and Methods

Forty rats (*Rattus norvegicus*), weighing 150-200 g and obtained from the Experimental Animal Laboratories of the Ege University Faculty of Medicine, were used. For 15 days, all the rats were kept naive for adaptation to their new environment.

The animals were separated into two groups, each consisting of 20 rats. The first group, which was treated as the experimental group, was given 1.5 mg dexamethasone subcutaneously twice a week for eight weeks to develop immunodeficiency. The rats' drinking water was supplemented with tetracycline to avoid secondary infections.

The second group functioned as the control group and was given no medication. The animals were kept in different cages in the same environment and on the same diet.

Ten of the animals in the first group died by the end of the fourth week. All the remaining animals were sacrificed by ether anaesthesia at the end of the eighth week. The intestinal mucosa of all the rats was scraped off and placed into different tubes. The content of each gut sample was smeared onto slides and processed by modified Ritchie technique. Then the sediment was smeared onto slides. These slides were stained with Kinyoun acid-fast, modified Kinyoun acid-fast and Auramine staining techniques. Smears stained with Kinyoun acid fast and modified Kinyoun acid-fast were examined by light microscopy, whereas those stained with Auramine were evaluated under a fluorescent microscope.

Statistical analysis of the data number of *Cryptosporidium* spp. positive animals in each group was performed by Chi-Square by Fisher's Exact Test; a P value of less than .05 was considered significant.

Results

After two weeks of immunosuppression, we observed that the hair of the animals had deteriorated and turned yellowish. Their testicles had enlarged and their locomotion had decreased. Petechial bleeding of the skin on the ears and exophthalmia (possibly due to papillary edema and pseudotumor cerebri) developed in some animals.

Ten rats that had been given corticosteroid died of infections caused by immunosuppression by the end of week 4. After examining their gut content, two rats were detected to have *Cryptosporidium* spp. oocysts. Of the 10 rats sacrificed in the experimental group, seven were found to have oocysts in their gut content at the end of

eight weeks; this difference was significant (Fisher's exact test, $P < 0.05$) (Table, Figs. 1-4). There was no detectable change in appearance and locomotion in the control group. Two control rats had oocysts in their gut content. Although we did not compare them quantitatively, we noticed that the shedding of oocysts in the stool increased in the immunosuppressed rats. We also observed that the shedding of oocytes in general increased in the immunosuppressed rats.

Table. Incidence of *Cryptosporidium* spp. in the control and experimental groups.

Groups	<i>Cryptosporidium</i> (+)	<i>Cryptosporidium</i> (-)	Total
Control	2	18	20
Experimental	9	11	20
Total	11	29	40

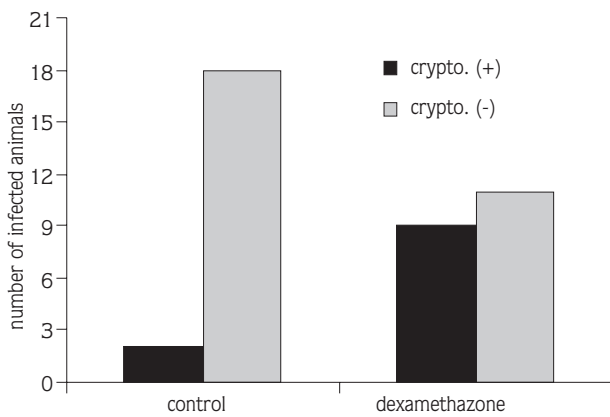


Fig. 1. Comparison of control and experimental groups. (Chi-Square, Fisher's exact test; $p < 0.05$).




Fig. 2. *Cryptosporidium* oocysts with Auramine Stain (X100).

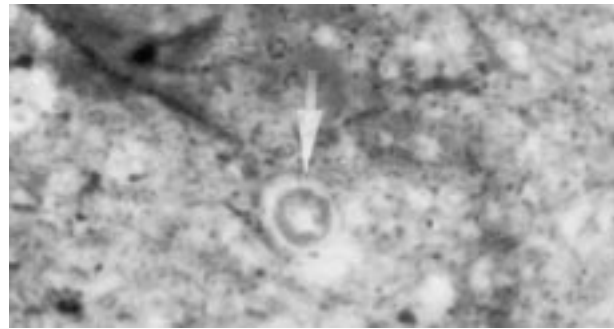


Fig. 3. *Cryptosporidium* oocysts with Kinyoun Acid Fast Stain (X100).

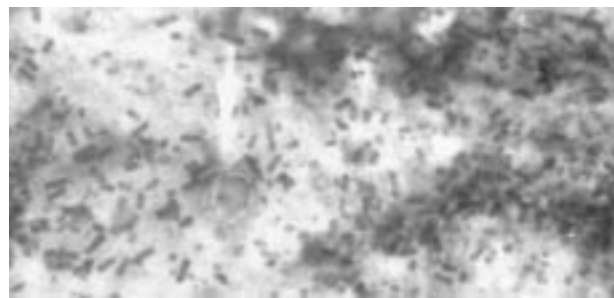


Fig. 4. *Cryptosporidium* oocysts with Modified Kinyoun Acid-Fast Stain (X100).

Discussion

Cryptosporidiosis is one of the major infectious diseases that threaten life in immunosuppressed human beings and animals (2). In studies investigating the relationship between cryptosporidiosis and immune deficiency, either immunosuppressed or T cell-defected mice and rats were used. In these studies, *Cryptosporidium* spp. oocysts were administered orally to the animals. Severe diarrhea and death caused by cryptosporidiosis have been reported in these animals (8,9,15).

It is well established that prolonged administration of dexamethasone suppresses the immune system, decreases the B cell population in the spleen, changes the ratio of CD_4^+/CD_8^+ , and subsequently results in vulnerability to cryptosporidiosis (13). In studies between 1991 and 1993 it was shown that dexamethasone decreased the response of T, B and natural killer cells and antibody production and suppressed the production of serum IgG and in vitro IgG (16,17)

Many authors have stated that *C. parvum* and *C. muris* exist naturally in rodents, and other mammals'

guts and respiratory tracts (17,18). We also detected *Cryptosporidium* spp. in the guts of two rats from the control group.

In this study we used dexamethasone for immunosuppression, and we investigated the development of naturally occurring *Cryptosporidium* spp. infection in both the experimental and control groups. In the animals treated with dexamethasone, motor activity decreased and general deterioration of the hair and enlargement of the testicles were observed; however, none of the specific symptoms of cryptosporidiosis were seen. Chai et al. (19) have reported that the activation of latent cryptosporidiosis and increased oocyst extraction were observed in mice experimentally immunosuppressed by prednisolone.

Tarazona et al. (18) have observed that in immunosuppressed mice, the incubation period of *Cryptosporidium* infection decreased, the duration of illness and shedding of oocytes were prolonged and that 44% of the animals died. In our study, nine rats out of the 10 which survived the eighth week of immunosuppression were found to be *Cryptosporidium* spp. positive. *Cryptosporidium* spp. oocysts were also detected in 20% of the immunosuppressed rats that died by week 4 of dexamethasone administration. Although we have not quantified the oocysts, it was noteworthy

that the *Cryptosporidium* spp. oocysts were much more abundant in material obtained from the immunosuppressed group than in that from the control group.

Various investigators (20-23) experimentally infected different species of mice and rats and demonstrated the positive relationship between cryptosporidiosis and immunosuppression. Our results confirm that immunosuppression increases the predisposition to cryptosporidiosis and the development of this infection in the host. Our experimental rats were not inoculated, similar to those in the control group. Willard and Bouley (24) reported a case in which "a puppy had chronic diarrhea due to simultaneous opportunistic pathogens (i.e. cryptosporidiosis, coccidiosis) and total colonic mucosal collapse. Lack of lymphoid follicles in the spleen and lymph nodes had suggested a primary underlying immunosuppression that most likely permitted infection with these pathogens". We have also established that cryptosporidiosis may readily develop in experimental conditions without *Cryptosporidium* spp. being administered to animals. We conclude that periodical examination of immunosuppressed patients for cryptosporidiosis is necessary to preserve their health and quality of life and to maintain their longevity.

References

- Unat, E.K., Yücel, A., Altaş, K., Samastı, M.: *Cryptosporidium* spp. and their parasitosis. *Unat'ın Tıp Parazitolojisi*. İstanbul Üniversitesi Cerrahpaşa Tıp Fakültesi Yayınları. 1991 p. 595-600.
- Ungar, B.L.P.: *Cryptosporidium*. In: Mandell G.L., Bennet J.E., Dolin R eds. *Principles and Practice of Infectious Diseases*. 4th Edition. Churchill Livingstone Inc. New York, 1995, p. 2500-2510.
- Ok, Ü., Üner, A., Korkmaz, M.: Cryptosporidiosis. In: Özcel M.A. eds. *İmmun Yetmezlikte Önemi Artan Parazit Hastalıkları*. Türkiye Parazitoloji Derneği Yayınları No: 12. Ege Üniv. Basımevi Bornova, İzmir 1995, p. 23-42.
- Wolfson, J.S., Richter, J.M., Waldron, M.A., Weber, D.J., McCarthy, D.M., Hopkins, C.C.: Cryptosporidiosis in Immunocompetent Patients. *New England J. Med.* 1985; 16: 1278-1282.
- Soave, R., Johnson Warren, D.: AIDS Commentary. *J. Inf. Dis.* 1988; 157: 225-229.
- Heine, J., Moon, H.W., Woodmansee, DB.: Persistent cryptosporidium infection in congenitally athymic (nude) mice. *Infec. Immun.* 1984; 43: 856-859.
- Mead, J.R., Arrowood, M.J., Sidwell, R.W., Healey, M.C.: Chronic *C. parvum* infections in congenitally immunodeficient SCID and nude mice. *J. Infect. Dis.* 1991; 163: 1297-1304.
- Rehg, J.E., Hancock, M.L., Woodmansee, D.B.: Characterisation of a Dexamethasone-treated rat model of cryptosporidial infection. *J. Infec. Dis.* 1988; 158: 1406-1407.
- Ungar, B.L.P., Burris, J.A., Quinn, C.A., Finkelman, F.D.: New mouse models for chronic cryptosporidium infection in immunodeficient hosts. *Infec. Immun.* 1990; 58: 961-969.
- Darban, H., Enriquez, J., Sterling, C.R.: Cryptosporidiosis facilitated by murine retroviral infection with LP-BM5. *J. Infect. Dis.* 1991; 164: 741-745.
- Harp, J.A., Chen, W., Harmsen, A.G.: Resistance of severe combined immunodeficient mice to infection *C. parvum*: The importance of intestinal microflora. *Infec. Immun.* 1992; 60: 3509-3512.
- Rossi, P., Pozio, E., Besse, M.G., Gomez Morales, M.A., Rosa, G.: Experimental cryptosporidiosis in hamsters. *J. Clin. Microbiol.* 1990; 28: 356-357.

13. Sherwood, D., Angus, K.W., Snodgrass, D.R., Tzipori, S.: Experimental cryptosporidiosis in laboratory mice. *Infec. Immun.* 1982; 38: 71-75.
14. Ungar, B.L.P., Kao, T.C., Burris, J.A., Finkelman, F.D.: Cryptosporidium infection in adult mouse model. Independent roles for IFN γ and CD₄⁺ T lymphocytes in protective immunity. *J. Immunol.* 1991; 147: 1014-1022.
15. Brasseur, P., Lemeteil, D., Ballet, J.J.: Rat model for human cryptosporidiosis. *J. Clin. Microbiol.* 1988; 26: 1037-1039.
16. Rasmussen, K.R., Martin, E.G., Arrowood, M.J., Healey, M.C.: Effects of dexamethasone and dehydroepiandrosterone in immunosuppressed rats infected with *C. parvum*. *J. Protozool.* 1991; 38: 157S-159S.
17. Rasmussen, K.R., Martin, E.G., Arrowood, M.J., Healey, M.C.: Effects of dehydroepiandrosterone in immunosuppressed rats infected with *C. parvum*. *J. Parasitol.* 1993; 79: 364-370.
18. Tarazona, R., Blewett, D.A., Carmona, M.D.: *C. parvum* infection in experimentally infected mice: infection dynamics and effect of immunosuppression. *Folia Parasitol (Praha)*. 1998; 45: 101-107
19. Chai, J.Y., Shin, S.M., Yun, C.K., Yu, J.R., Lee, S.H.: Experimental activation of cryptosporidiosis in mice by immunosuppression. *Kisaengchunghak Chapchi*. 1990; 28: 31-37.
20. Yang, S., Benson, S.K., Du, C., Healey, M.C.: Infection of immunosuppressed C57BL/6N adult mice with a single oocyst of *Cryptosporidium parvum*. *J. Parasitol.* 2000; 86: 884-887.
21. Yang, S., Healey, M.C., Du, C.: Infectivity of preserved *Cryptosporidium parvum* oocysts for immunosuppressed adult mice. *FEMS Immunol. Med. Microbiol.* 1996; 13: 141-145.
22. Yang, S., Healey, M.C.: Patent gut infections in immunosuppressed adult C57BL/6N mice following intraperitoneal injection of *Cryptosporidium parvum* oocysts. *J. Parasitol.* 1994; 80: 338-342.
23. Cheng, L., Rasmussen, K.R., Healey, M.C., Yang, S.: Primary and secondary infections with *C. parvum* in immunosuppressed adult mice. *Am. J. Trop. Med. Hyg.* 1996; 55: 324-329.
24. Willard, M.D., Bouley, D.: Cryptosporidiosis, coccidiosis, and total colonic mucosal collapse in immunosuppressed puppy. *J. Am. Anim. Hosp. Assoc.* 1999; 35: 405-409.