

1-1-2003

## Experimental *Aspergillus fumigatus* Infection in Dogs and Treatment with Itraconazole\*

YÜCEL ÇAM

AYHAN ATASEVER

FATMA UYANIK

K. SEMİH GÜMÜŞSOY

Follow this and additional works at: <https://journals.tubitak.gov.tr/veterinary>



Part of the [Animal Sciences Commons](#), and the [Veterinary Medicine Commons](#)

---

### Recommended Citation

ÇAM, YÜCEL; ATASEVER, AYHAN; UYANIK, FATMA; and GÜMÜŞSOY, K. SEMİH (2003) "Experimental *Aspergillus fumigatus* Infection in Dogs and Treatment with Itraconazole\*," *Turkish Journal of Veterinary & Animal Sciences*: Vol. 27: No. 5, Article 16. Available at: <https://journals.tubitak.gov.tr/veterinary/vol27/iss5/16>

This Article is brought to you for free and open access by TÜBİTAK Academic Journals. It has been accepted for inclusion in Turkish Journal of Veterinary & Animal Sciences by an authorized editor of TÜBİTAK Academic Journals. For more information, please contact [academic.publications@tubitak.gov.tr](mailto:academic.publications@tubitak.gov.tr).

## Experimental *Aspergillus fumigatus* Infection in Dogs and Treatment with Itraconazole\*

Yücel ÇAM

Department of Internal Medicine, Faculty of Veterinary Medicine, Erciyes University, Kayseri - TURKEY

Ayhan ATASEVER

Department of Pathology, Faculty of Veterinary Medicine, Erciyes University, Kayseri - TURKEY

Fatma UYANIK

Department of Biochemistry, Faculty of Veterinary Medicine, Erciyes University, Kayseri - TURKEY

K. Semih GÜMÜŞSOY

Department of Microbiology, Faculty of Veterinary Medicine, Erciyes University, Kayseri - TURKEY

Received: 23.05.2002

**Abstract:** The aim of this study was to investigate the findings of clinical, haematological, biochemical, histopathological, mycological and urine analyses and to evaluate the efficiency of itraconazole treatment in dogs experimentally infected with *Aspergillus fumigatus*. In this study, 25 healthy male dogs were used. The animals were divided into 3 groups: group I (control), group II (infected) and group III (treatment) consisting of 5, 10 and 10 dogs, respectively. Cyclophosphamide was injected into the dogs of groups II and III before the inoculation of *A. fumigatus* via intravenous (i.v.) route. Clinical findings of aspergillosis were developed after the second day following *A. fumigatus* inoculation. Three dogs died in group II. On the seventh day after the inoculation of the agent (PI), lymphocytosis, monocytosis, granulocytosis and leucocytosis were determined in groups II and III. However, the percentage of lymphocytes in white blood cells decreased. The red blood cell and platelet counts, haemoglobin and haematocrit values, glucose concentrations and the specific gravity of urine decreased while serum alkaline phosphatase activity, urea nitrogen, total protein, globulin, magnesium and phosphorus concentrations increased. Haematuria was observed in all dogs, and proteinuria, glucosuria and ketonuria were observed in some of them. Leucocyte and erythrocyte counts increased in the urine sediment. *Aspergillus fumigatus* was isolated from the urine, nasal swabs, lungs, kidney, liver, heart, spleen, nasal concha and lymphoid nodules of some of the dogs, while the hyphae of the agent and granulomatous inflammation were observed only in the lungs and kidneys by histopathological examination. The treatment of the animals started on day 10 PI. Itraconazole, at 5 mg/kg body weight per day, was orally administered for 6 weeks. Four dogs died during the treatment period. At the end of the experiment, all of the clinical signs in the 6 surviving dogs had improved except for exophthalmus, miosis, an absence of pupillary reflexes and blindness in 2 dogs. Haematological, biochemical and urine analysis findings returned to close to normal values. It was determined that itraconazole treatment was effective in 6 dogs.

**Key Words:** *Aspergillus fumigatus*, experimental aspergillosis, itraconazole, dog

### Köpeklerde Deneysel *Aspergillus fumigatus* Enfeksiyonu ve Itrakonazol ile Sağaltımı

**Özet:** Bu çalışmada, köpeklerde *Aspergillus fumigatus* ile oluşturulan deneysel enfeksiyonda; klinik, hematolojik, biyokimyasal, idrar analizi, histopatolojik ve mikolojik muayene bulgularının belirlenmesi ve itrakonazol'un sağaltım etkinliğinin değerlendirilmesi amaçlandı. Çalışmada, 25 sağlıklı erkek köpek kullanıldı. Hayvanlar I. grupta (kontrol) 5, II. grupta (enfekte) ve III. grupta (sağaltım) 10'ar köpek olacak şekilde üç gruba ayrıldı. *Aspergillus fumigatus* inokulasyonundan önce II. ve III. gruptaki köpeklere siklofosfamid verildi. Daha sonra intravenöz yolla *A. fumigatus* inokule edildi. Etken inokulasyonundan sonraki 2. günden itibaren aspergillozis'in klinik belirtileri gelişti. İkinci gruptan 3 köpek öldü. Etkenin verilmesinin 7. gününde II. ve III. gruplarda lenfositosis, monositosis, granülositosis ve lökositosis belirlendi. Ancak lenfositlerin, toplam beyaz kan hücreleri (WBC) içindeki dağılım yüzdesi düştü. Kırmızı kan hücreleri (RBC) ve trombosit (Plt) sayıları, Hgb ve Hct değerleri, glukoz konsantrasyonu ve idrarın özgül ağırlığı düşerken ALP aktivitesi, üre azotu, total protein, globulin, Mg ve P konsantrasyonları yükseldi. Köpeklerin tümünde hematuri, bazılarında proteinuri, glikozüri ve ketonuri belirlendi. İdrar sedimentlerinde lökosit ve eritrosit sayısı arttı. Köpeklerin idrar, burun eküvyonu, akciğer, böbrek, karaciğer, kalp, dalak, burun konhası ve lenf yumrularından *A. fumigatus* izole edilirken sadece akciğer ve böbreklerde histopatolojik olarak granülatöz yangı ve etken hifaları tespit edildi. Etken verilmesini takiben 10. günde sağaltıma

\* This project was supported by The Scientific and Technical Research Council of Turkey (TÜBİTAK). Project No: VHAG-1650.

başlandı. Itrakonazol III. grup köpeklere 5 mg/kg vücut ağırlığı dozunda günde bir kez 6 hafta süreyle oral verildi. Sağaltım sürecinde 4 köpek öldü. Deneme sonunda, canlı kalan 6 köpeğin ikisinde gözlenen ekzoftalmus, miyozis, pupilla refleksi kaybı ve körlük dışında tüm klinik belirtilerin düzeldiği belirlendi. Hematolojik, biyokimyasal ve idrar değerlerinin normale yakın olduğu saptandı. Itrakonazol sağaltımının 6 köpekte etkili olduğu tespit edildi.

**Anahtar Sözcükler:** *Aspergillus fumigatus*, deneysel aspergillozis, itraconazol, köpek

## Introduction

Aspergillosis has been reported in dogs, cats, sheep, cattle, alpaca, horses, rabbits and human beings (1-3). Canine aspergillosis is mostly confined to the upper respiratory tract, particularly in the nasal cavity, and the systemic form is rare (3-7). *Aspergillus fumigatus*, a ubiquitous soil saprophyte, is the most common pathogenic species (3,8-10). It probably enters the body through the respiratory tract (2,3,11). Although canine aspergillosis has been reported in every age and breed of dog, it primarily affects young to middle-aged animals (3,11,12). In the development of the infection, the spore count and depressed immunity of the host are of importance (2,7,10,11,13). Experimental infections via intratracheal and intravenous routes have been reported (14).

Various antifungal drugs have been used for the treatment of aspergillosis (3,9,10,15). Treatment of the infection with thiabendazole, ketoconazole, amphotericin-B and fluconazole has had success rates of 43 to 60% (3,9,15,16). In recent years, the administration of itraconazole has resulted in 60 to 70% success rates (3). Itraconazole have been widely used in human medicine, while this compound has only recently been used in veterinary medicine (3,10,12,17). To our knowledge, there have been limited investigations on the treatment of canine aspergillosis with itraconazole (4,10,12). Therefore, this study was conducted to investigate the findings of clinical, haematological, biochemical, histopathological, mycological and urine analysis, and to evaluate the efficiency of itraconazole treatment in dogs experimentally infected with *A. fumigatus*.

## Materials and Methods

**Experimental animals:** In this study, 25 mix-breed, male, 1-3-year-old, 17-25 kg, healthy, stray dogs were used. The dogs were observed for 14 days and selected for the study. The animals were randomly divided into 3 groups: group I (control), group II (infected) and group

III (treatment), consisting of 5, 10 and 10 dogs, respectively. The dogs were housed individually in wire cages and fed with commercial pellet food, and water was supplied ad libitum.

**Preparation of inoculum:** *A. fumigatus* Netherlands CBC strain was supplied by Dr. F.M.S. Meis Jacques, Department of Medical Microbiology, Canisus Wilhelmina Hospital, Nijmegen, The Netherlands. Sabouroud Dextrose Agar (SDA) and Czapek-Dox Agar (CDA) with 20 IU penicillin G/ml + 40 µg streptomycin/ml were used for the growth of *A. fumigatus*. Macroscopical and microscopical examinations of colonies were carried out by the method described by Arda (1). The concentration of  $2.7 \times 10^6$  spores/ml was obtained by measuring the optic density of the spore suspension, ranging from 0.09 to 0.11 at 530 nm, by Shimadzu-UV 1208 spectrophotometer for *A. fumigatus* inoculum (18).

**Induction of experimental infection:** Cyclophosphamide (Endoxan-Asta®, İ.E.Ulugay) at 2.2 mg/kg body weight/day was administered intravenously three times on 2 consecutive days with a 1-day interval to the dogs in groups II and III to suppress the immune system prior to the inoculation of the agent. Then the dogs were inoculated with 5 ml of *A. fumigatus* inoculum by i.v. route.

**Treatment:** The treatment of the dogs in group III started on day 10 PI. Itraconazole (Itraspor, Janssen-Cilag) at 5 mg/kg body weight per day was orally administered for 6 weeks.

**Clinical examination and sample collection:** Clinical findings were observed and recorded throughout the study. Rectal temperature and respiratory and heart rates were recorded and blood, urine and nasal swab samples were collected prior to infection, on day 7 PI and at the end of the experiment.

**Haematological, biochemical and urine analysis:** The white blood cell (WBC), red blood cell (RBC) and platelet (Plt) counts, lymphocyte, monocyte and

granulocyte WBC count and percentages, haemoglobin (Hgb), haematocrit (Hct), mean corpuscular volume (MCV), mean corpuscular haemoglobin (MCH), mean corpuscular haemoglobin concentration (MCHC), red blood cell distribution width (RDW), mean platelet volume (MPV) and platelet distribution width (PDW) were determined by an automated haematology cell counter (Beckman Coulter). Serum ALP, aspartate aminotransferase (AST), alanine aminotransferase (ALT), creatine kinase (CK), lactate dehydrogenase (LDH) activities (Biolabo, France), urea, creatinine, glucose, total protein, albumin, globulin, direct bilirubin, calcium, magnesium and phosphorus concentrations (Chema diagnostica, Italy) were determined with commercial kits by a Shimadzu-UV 1208 model spectrophotometer. Physical (turbidity, colour), chemical (pH, specific gravity, protein, glucose, ketones, bilirubin, blood, nitrite, haemoglobin and urobilinogen) and microscopic (WBC, RBC, epithelial cells, crystals, and casts) urine analyses were performed by a urine analyser (Iris-500).

**Mycological examination:** Samples of urine, nasal swabs and organs (lungs, liver, kidneys, heart, spleen, nasal concha, lymphoid nodules, pancreas, eye and brain) were inoculated on SDA and CDA. The isolates were identified on the basis of morphology and cultural characteristics (1).

**Necropsy:** On day 7 PI, 5 dogs from group II, and at the end of the experiment 4 dogs from groups II and III (2 dogs from each group), were euthanised with succinylcholin chloride + sodium chloride (Lysthenon® forte, Faco), 3 dogs from group II and 4 dogs from group III that died during the experiment were necropsied, and all organ systems were examined. Tissue samples were collected for histopathological examination. These were fixed in 10% neutral buffered formalin and embedded in paraffin, sectioned (5-6 µm) and mounted on glass slides. The sections were stained with haematoxylin and eosin (HE). Selected sections were also stained with periodic acid Schiff (PAS) and Gridley's methods for fungi.

**Statistical analysis:** The data were subjected to variance analysis (one-way ANOVA). Duncan's multiple range test was performed when the differences were significant. The differences between pre- and post-inoculation and at the end of the experiment were determined by paired t test (19). All data were expressed as means ± SEM.

## Results

**Clinical findings:** On days 2-5 PI, dullness, anorexia, weight loss, dehydration, sneezing, coughing, dyspnoea, hardness of respiratory sounds and crepitation rales on auscultation of the lungs in all dogs, mucoid-mucopurulent nasal discharge in 18 dogs, and vomiting in 10 dogs on days 6-7 PI were observed. On day 7 PI, heart rate and respiratory rate were increased (Table 1). In group II, 3 dogs died on days 9, 10 and 19 PI. Exophthalmos, lacrimation, corneal and conjunctival vascularisation and congestion, chemosis, increased corneal opacity, miosis, lack of pupillary reflexes and blindness were observed in 1 eye of 2 dogs on day 9, in both eyes of 1 dog on day 10 in group III, and in 1 eye of 1 dog on day 30 in group II. At the end of the experiment, the severity of the clinical findings, except for the increased respiratory rate, were diminished in 2 dogs which survived in group II. After the beginning of the treatment in group III, 2, 1 and 1 dogs died on days 4, 6 and 7, respectively. At the end of the treatment, 6 dogs had survived and recovered from all clinical findings except for exophthalmos, miosis, lack of pupillary reflexes and blindness in 2 dogs with eye lesions.

**Haematological and biochemical findings:** The haematological and biochemical data are expressed in Tables 1 and 2, respectively.

**Findings of urine analysis:** On day 7 PI, the specific gravity of urine samples was slightly reduced in group II and significantly reduced ( $P < 0.001$ ) in group III (Table 1). Eighteen of the urine samples were dark yellow and turbid. Proteinuria levels of 30 mg/dl, 100 mg/dl and  $\geq 300$  mg/dl were detected in 5, 11 and 3 urine samples, respectively. Levels of trace and 0.25 g/dl glycosuria were detected in 2 and 3 urine samples, and ketonuria was trace in 1 sample. The haematuria scores were 1<sup>+</sup> in 4, 2<sup>+</sup> in 6 and 3<sup>+</sup> in 10 urine samples. Levels of 0.1 EU/dl and 1 EU/dl urobilinogen were detected in 19 and 1 urine samples, respectively. The scores of WBC and RBC in per high power field were 1-3, 6-13, 20-30, 31-40, 41-45 and  $>50$  WBC in 2, 4, 7, 3, 2 and 2 urine samples; 9-14, 20-30, 31-35 and  $>50$  RBC in 2, 5, 3 and 10 urine samples, respectively. At the end of the experiment, both urine samples of the animals in group II were dark yellow and slightly turbid, and levels of 100 mg/dl proteinuria, 1<sup>+</sup> haematuria and 0.1 EU/dl urobilinogen were detected. In one urine sample, 25 WBC and 70 RBC, and in the other sample 23 WBC and 30 RBC were determined. In group III, the results of urine analysis returned to the values obtained prior to infection.

Table 1. Heart rate, rectal temperature, respiratory rate, urine pH and specific gravity, and haematological parameters of dogs at the beginning of the experiment, on 7 days postinoculation of *A. fumigatus* and at the end of the experiment.

Parameters	Days	Groups						p
		I		II		III		
		n	(x ± Sx)	n	(x ± Sx)	n	(x ± Sx)	
Heart rate (min.)	BE	5	110.80 ± 4.76	10	108.80 ± 3.48	10	100.00 ± 3.53	
	7 days PI	5	104.40 ± 1.69	10	127.80 ± 8.13	10	118.72 ± 4.60	
	AE	5	108.02 ± 4.29	2	110.00 ± 22.00	6	110.00 ± 3.39	
		p						
Rectal temperature (°C)	BE	5	38.70 ± 0.09	10	38.81 ± 0.20	10	38.72 ± 0.06	
	7 days PI	5	38.64 ± 0.12	10	39.16 ± 0.11	10	38.84 ± 0.33	
	AE	5	38.32 ± 0.11	2	38.80 ± 0.10	6	38.52 ± 0.12	
		p						
Respiratory rate (min.)	BE	5	20.00 ± 1.67	10	23.00 ± 2.27 <sup>B</sup>	10	19.40 ± 0.90	
	7 days PI	5	20.40 ± 1.94	10	28.80 ± 1.44 <sup>AB</sup>	10	24.40 ± 2.58	
	AE	5	19.20 ± 1.02 <sup>b</sup>	2	33.00 ± 7.00 <sup>aA</sup>	6	22.17 ± 1.11 <sup>b</sup>	**
		p		*				
Urine pH	BE	5	5.80 ± 0.37	10	6.20 ± 0.33	10	6.10 ± 0.24	
	7 days PI	5	6.20 ± 0.20	10	5.90 ± 0.18	10	5.90 ± 0.28	
	AE	5	5.60 ± 0.24	2	6.00 ± 1.00	6	6.17 ± 0.44	
		p						
Specific gravity of urine	BE	5	1.031 ± 0.005	10	1.023 ± 0.004	10	1.031 ± 0.004 <sup>A</sup>	
	7 days PI	5	1.022 ± 0.003 <sup>a</sup>	10	1.012 ± 0.003 <sup>b</sup>	10	1.011 ± 0.001 <sup>bB</sup>	*
	AE	5	1.022 ± 0.002	2	1.022 ± 0.003	6	1.024 ± 0.005 <sup>A</sup>	
		p				***		
WBC (x 10 <sup>3</sup> /μl)	BE	5	10.04 ± 2.01	10	11.29 ± 1.37 <sup>B</sup>	10	11.79 ± 1.17 <sup>B</sup>	
	7 days PI	5	10.88 ± 1.45 <sup>b</sup>	10	33.17 ± 5.74 <sup>aA</sup>	10	30.07 ± 4.56 <sup>aA</sup>	*
	AE	5	11.52 ± 1.23 <sup>b</sup>	2	25.55 ± 4.15 <sup>aAB</sup>	6	8.87 ± 1.04 <sup>bB</sup>	***
		p		**		***		
Lymphocytes (%)	BE	5	37.74 ± 2.88	10	38.27 ± 2.64	10	36.84 ± 2.16 <sup>B</sup>	
	7 days PI	5	37.60 ± 1.99	10	27.01 ± 2.39	10	29.14 ± 3.39 <sup>B</sup>	
	AE	5	37.90 ± 1.50 <sup>ab</sup>	2	34.05 ± 0.55 <sup>b</sup>	6	49.87 ± 4.48 <sup>aA</sup>	*
		p				***		
Lymphocytes (x 10 <sup>3</sup> /μl)	BE	5	3.71 ± 0.75	10	4.07 ± 0.35	10	4.21 ± 0.39 <sup>B</sup>	
	7 days PI	5	4.07 ± 0.57	10	8.89 ± 1.71	10	8.61 ± 1.43 <sup>A</sup>	
	AE	5	4.35 ± 0.47 <sup>b</sup>	2	8.72 ± 1.56 <sup>a</sup>	6	4.46 ± 0.69 <sup>bB</sup>	*
		p				**		
Monocytes (%)	BE	5	9.22 ± 0.38	10	9.37 ± 0.26 <sup>B</sup>	10	7.86 ± 0.98	
	7 days PI	5	8.48 ± 0.23	10	14.12 ± 1.45 <sup>AB</sup>	10	10.47 ± 1.89	
	AE	5	9.32 ± 0.35	2	16.75 ± 5.45 <sup>A</sup>	6	12.35 ± 1.20	
		p		**				
Monocytes (x 10 <sup>3</sup> /μl)	BE	5	0.93 ± 0.20	10	1.07 ± 0.15 <sup>B</sup>	10	1.00 ± 0.10 <sup>B</sup>	
	7 days PI	5	0.91 ± 0.11 <sup>b</sup>	10	4.46 ± 0.77 <sup>aA</sup>	10	2.95 ± 0.52 <sup>aA</sup>	**
	AE	5	1.09 ± 0.15 <sup>b</sup>	2	4.05 ± 0.70 <sup>aA</sup>	6	1.04 ± 0.15 <sup>bB</sup>	***
		p		***		***		
Granulocytes WBC (%)	BE	5	53.04 ± 3.17	10	52.33 ± 2.49	10	53.48 ± 2.57 <sup>A</sup>	
	7 days PI	5	53.92 ± 0.02	10	58.87 ± 2.80	10	60.39 ± 4.32 <sup>A</sup>	
	AE	5	52.80 ± 1.31 <sup>a</sup>	2	45.10 ± 0.80 <sup>ab</sup>	6	38.25 ± 3.34 <sup>bB</sup>	**
		p				**		

Table 1. Continued.

Parameters	Days	Groups						p
		I		II		III		
		n	(x ± Sx)	n	(x ± Sx)	n	(x ± Sx)	
Granulocytes WBC (x 10 <sup>3</sup> /μl)	BE	5	5.40 ± 1.26	10	6.15 ± 0.95 <sup>B</sup>	10	6.43 ± 0.82 <sup>B</sup>	***
	7 days PI	5	5.90 ± 0.83	10	19.86 ± 3.88 <sup>A</sup>	10	18.52 ± 3.49 <sup>A</sup>	
	AE	5	6.03 ± 0.70 <sup>b</sup>	2	12.79 ± 3.30 <sup>aAB</sup>	6	3.36 ± 0.47 <sup>bB</sup>	
	p			**		***		
RBC (x 10 <sup>6</sup> /μl)	BE	5	6.14 ± 0.16	10	6.15 ± 0.22	10	5.93 ± 0.18 <sup>A</sup>	***
	7 days PI	5	6.26 ± 0.20 <sup>a</sup>	10	5.75 ± 0.26 <sup>ab</sup>	10	5.20 ± 0.20 <sup>bB</sup>	
	AE	5	6.80 ± 0.28	2	5.51 ± 0.23	6	6.57 ± 0.38 <sup>A</sup>	
	p				**			
Hgb (g/dl)	BE	5	14.66 ± 0.55	10	14.43 ± 0.55	10	14.24 ± 0.54 <sup>AB</sup>	**
	7 days PI	5	16.72 ± 0.69 <sup>a</sup>	10	13.36 ± 0.75 <sup>b</sup>	10	12.62 ± 0.66 <sup>bB</sup>	
	AE	5	16.60 ± 0.81	2	13.00 ± 0.60	6	16.47 ± 1.69 <sup>A</sup>	
	p					*		
Hct (%)	BE	5	41.94 ± 1.60	10	40.87 ± 1.76	10	39.75 ± 1.23 <sup>B</sup>	***
	7 days PI	5	48.04 ± 1.66 <sup>a</sup>	10	38.33 ± 2.17 <sup>b</sup>	10	34.17 ± 1.63 <sup>bC</sup>	
	AE	5	47.96 ± 2.72	2	36.30 ± 2.50	6	47.03 ± 3.06 <sup>A</sup>	
	p					***		
MCV (fL)	BE	5	68.36 ± 2.29	10	66.28 ± 0.75	10	66.95 ± 1.24 <sup>B</sup>	
	7 days PI	5	70.10 ± 0.74	10	66.36 ± 1.17	10	65.85 ± 1.04 <sup>B</sup>	
	AE	5	70.58 ± 1.62	2	65.80 ± 1.80	6	71.40 ± 1.47 <sup>A</sup>	
	p					*		
MCH (pg)	BE	5	23.86 ± 0.45	10	23.44 ± 0.26	10	24.38 ± 0.42	
	7 days PI	5	25.14 ± 0.42	10	23.17 ± 0.44	10	24.30 ± 0.53	
	AE	5	24.94 ± 0.48	2	23.55 ± 0.15	6	26.02 ± 2.27	
	p							
MCHC (g/dl)	BE	5	35.00 ± 0.86	10	35.41 ± 0.51	10	36.28 ± 0.34	**
	7 days PI	5	34.78 ± 0.74 <sup>b</sup>	10	34.92 ± 0.42 <sup>b</sup>	10	36.89 ± 0.32 <sup>a</sup>	
	AE	5	34.68 ± 0.83	2	30.85 ± 5.75	6	34.58 ± 1.41	
	p							
RDW (%)	BE	5	14.90 ± 0.69	10	15.28 ± 0.53	10	14.52 ± 0.45	
	7 days PI	5	15.32 ± 0.47	10	15.90 ± 0.44	10	15.26 ± 0.53	
	AE	5	15.04 ± 0.43	2	17.15 ± 0.55	6	15.43 ± 0.55	
	p							
PLT (x 10 <sup>3</sup> /μl)	BE	5	359.60 ± 40.39	10	392.95 ± 40.56 <sup>B</sup>	10	334.30 ± 33.7 <sup>A</sup>	*
	7 days PI	5	332.40 ± 46.70 <sup>a</sup>	10	291.30 ± 34.70 <sup>aB</sup>	10	194.60 ± 13.03 <sup>bB</sup>	
	AE	5	364.40 ± 57.09	2	592.50 ± 202.50 <sup>A</sup>	6	363.00 ± 41.71 <sup>A</sup>	
	p			*		**		
MPV (fL)	BE	5	8.82 ± 0.58	10	8.30 ± 0.34	10	8.38 ± 0.34 <sup>B</sup>	**
	7 days PI	5	8.28 ± 0.62 <sup>b</sup>	10	8.59 ± 0.43 <sup>b</sup>	10	10.77 ± 0.59 <sup>aA</sup>	
	AE	5	8.94 ± 0.64	2	9.05 ± 0.15	6	9.27 ± 0.39 <sup>B</sup>	
	p					**		
PDW (%)	BE	5	15.88 ± 0.19	10	16.09 ± 0.41	10	16.27 ± 0.24 <sup>AB</sup>	
	7 days PI	5	16.22 ± 0.28	10	16.99 ± 0.33	10	17.12 ± 0.32 <sup>A</sup>	
	AE	5	16.10 ± 0.28	2	16.75 ± 1.05	6	15.87 ± 0.28 <sup>B</sup>	
	p					*		

BE: Before Experiment, AE: After Experiment

A-C: Values with different superscripts in the same column differ.

a-c Values with different superscripts in the same row differ.

\* P &lt; 0.05, \*\* P &lt; 0.01, \*\*\* P &lt; 0.001

Table 2. Serum biochemical parameters of dogs at the beginning of the experiment, on 7 days postinoculation of *A. fumigatus* and at the end of the experiment.

Parameters	Days	Groups						p
		I		II		III		
		n	(x ± Sx)	n	(x ± Sx)	n	(x ± Sx)	
ALP (IU/L)	BE	5	140.83 ± 4.51	10	140.18 ± 11.36 <sup>B</sup>	10	161.86 ± 9.76 <sup>B</sup>	
	7 days PI	5	134.82 ± 15.60 <sup>b</sup>	10	324.12 ± 52.79 <sup>aA</sup>	10	389.14 ± 55.02 <sup>aA</sup>	*
	AE	5	129.20 ± 11.76 <sup>b</sup>	2	238.98 ± 37.49 <sup>aAB</sup>	6	170.13 ± 18.22 <sup>bB</sup>	*
	p				**		*	
AST (IU/L)	BE	5	55.46 ± 11.41	10	52.52 ± 6.21	10	62.33 ± 5.00 <sup>A</sup>	
	7 days PI	5	42.17 ± 5.09	10	45.96 ± 2.93	10	46.45 ± 7.21 <sup>AB</sup>	
	AE	5	27.70 ± 2.07	2	38.29 ± 5.55	6	38.34 ± 4.00 <sup>B</sup>	*
	p						*	
ALT (IU/L)	BE	5	62.45 ± 14.48 <sup>A</sup>	10	31.96 ± 5.33	10	43.91 ± 8.28	
	7 days PI	5	29.90 ± 3.58 <sup>B</sup>	10	27.67 ± 4.13	10	36.10 ± 3.77	
	AE	5	29.67 ± 4.06 <sup>B</sup>	2	20.00 ± 5.31	6	27.37 ± 3.17	
	p		*					
CK (IU/L)	BE	5	266.37 ± 14.48 <sup>A</sup>	10	281.60 ± 41.70	10	381.04 ± 33.75	
	7 days PI	5	137.19 ± 23.76 <sup>B</sup>	10	147.87 ± 28.49	10	247.72 ± 112.96	
	AE	5	86.70 ± 8.19 <sup>bB</sup>	2	237.53 ± 11.06 <sup>a</sup>	6	127.65 ± 19.28 <sup>D</sup>	**
	p		**					
LDH (IU/L)	BE	5	459.50 ± 28.41	10	464.76 ± 12.23	10	412.96 ± 30.42	
	7 days PI	5	429.28 ± 33.39	10	562.81 ± 69.93	10	721.13 ± 192.10	
	AE	5	351.08 ± 50.06	2	477.60 ± 56.70	6	454.18 ± 20.55	
	p							
Urea (mg/dl)	BE	5	39.95 ± 4.15	10	26.9 ± 4.75 <sup>B</sup>	10	39.94 ± 4.85 <sup>B</sup>	
	7 days PI	5	40.02 ± 3.39	10	69.75 ± 11.31 <sup>A</sup>	10	86.44 ± 15.80 <sup>A</sup>	
	AE	5	41.10 ± 3.92	2	82.80 ± 17.20 <sup>A</sup>	6	65.33 ± 13.44 <sup>AB</sup>	
	p				**		*	
Creatinine (mg/dl)	BE	5	1.52 ± 0.11	10	1.42 ± 0.09	10	1.53 ± 0.09	
	7 days PI	5	1.30 ± 0.04	10	1.44 ± 0.18	10	2.98 ± 0.79	
	AE	5	1.43 ± 0.15	2	1.27 ± 0.58	6	1.23 ± 0.15	
	p							
Glucose (mg/dl)	BE	5	62.09 ± 3.49 <sup>B</sup>	10	66.17 ± 2.02 <sup>A</sup>	10	68.47 ± 4.45 <sup>B</sup>	
	7 days PI	5	64.78 ± 9.6 <sup>aB</sup>	10	29.31 ± 3.92 <sup>bB</sup>	10	27.39 ± 5.06 <sup>bC</sup>	***
	AE	5	83.88 ± 4.04 <sup>A</sup>	2	73.36 ± 6.34 <sup>A</sup>	6	87.32 ± 4.48 <sup>A</sup>	
	p		**		***		***	

Table 2. Continued.

Parameters	Days	Groups						p
		I		II		III		
		n	(x ± Sx)	n	(x ± Sx)	n	(x ± Sx)	
Direct Bilirubin (mg/dl)	BE	5	0.18 ± 0.05	10	0.19 ± 0.04	10	0.14 ± 0.03	
	7 days PI	5	0.09 ± 0.02	10	0.17 ± 0.06	10	0.17 ± 0.07	
	AE	5	0.14 ± 0.05	2	0.11 ± 0.09	6	0.12 ± 0.02	
		p						
Total Protein (g/dl)	BE	5	6.43 ± 0.34	10	5.84 ± 0.16 <sup>AB</sup>	10	6.13 ± 0.23 <sup>B</sup>	
	7 days PI	5	6.98 ± 1.72	10	6.91 ± 0.44 <sup>A</sup>	10	7.50 ± 0.49 <sup>A</sup>	
	AE	5	6.33 ± 0.33	2	5.18 ± 0.77 <sup>B</sup>	6	6.25 ± 0.32 <sup>B</sup>	
		p			*	*		
Albumin (g/dl)	BE	5	3.09 ± 0.48	10	2.53 ± 0.17	10	2.82 ± 0.17 <sup>A</sup>	
	7 days PI	5	2.51 ± 0.21	10	2.34 ± 0.23	10	2.13 ± 0.10 <sup>B</sup>	
	AE	5	2.48 ± 0.16	2	2.02 ± 0.21	6	2.58 ± 0.17 <sup>A</sup>	
		p				**		
Globulin (g/dl)	BE	5	3.32 ± 0.30	10	3.30 ± 0.13 <sup>B</sup>	10	3.30 ± 0.30 <sup>B</sup>	
	7 days PI	5	4.47 ± 0.67	10	4.57 ± 0.29 <sup>A</sup>	10	5.36 ± 0.46 <sup>A</sup>	
	AE	5	3.85 ± 0.35	2	3.16 ± 0.98 <sup>B</sup>	6	3.67 ± 0.23 <sup>B</sup>	
		p			**	***		
Ca (mg/dl)	BE	5	11.43 ± 0.46	10	11.53 ± 0.42	10	11.83 ± 0.18	
	7 days PI	5	11.97 ± 1.16	10	10.97 ± 0.42	10	11.56 ± 0.31	
	AE	5	10.27 ± 0.38	2	11.09 ± 0.75	6	10.89 ± 0.18	
		p						
Mg (mg/dl)	BE	5	2.33 ± 0.24	10	2.18 ± 0.09 <sup>AB</sup>	10	2.46 ± 0.09 <sup>B</sup>	
	7 days PI	5	2.38 ± 0.12	10	3.32 ± 0.50 <sup>A</sup>	10	3.50 ± 0.28 <sup>A</sup>	
	AE	5	1.89 ± 0.31	2	1.40 ± 0.06 <sup>B</sup>	6	1.92 ± 0.09 <sup>B</sup>	
		p			*	***		
P (mg/dl)	BE	5	4.31 ± 1.16	10	3.85 ± 0.76 <sup>B</sup>	10	3.88 ± 0.60 <sup>B</sup>	
	7 days PI	5	5.24 ± 0.25 <sup>b</sup>	10	10.51 ± 1.29 <sup>aA</sup>	10	9.17 ± 0.56 <sup>aA</sup>	*
	AE	5	5.72 ± 0.58 <sup>b</sup>	2	7.49 ± 0.08 <sup>abAB</sup>	6	7.81 ± 0.43 <sup>aA</sup>	*
		p			***	***		

BE: Before Experiment, AE: After Experiment

A-C: Values with different superscripts in the same column differ.

a-c Values with different superscripts in the same row differ.

\* P &lt; 0.05, \*\* P &lt; 0.01, \*\*\* P &lt; 0.001



**Mycological findings:** *Aspergillus fumigatus* was isolated and identified from the nasal swabs of 19 dogs and the urine samples of 18 dogs in groups II and III on day 7 PI. At the end of the experiment, the agent was isolated from nasal swabs and urine samples from 2 surviving dogs in group II. *Aspergillus fumigatus* was isolated from 14 lungs, 11 livers, 13 kidneys and spleens, 5 heart and lymph nodules and 8 nasal concha samples of 14 dogs which died in groups II and III, and which were euthanised in group II throughout the experiment. No isolation of the agent was done from any nasal swab, urine or organ samples of the 2 dogs euthanised in group III after termination of the treatment.

**Necropsy findings:** The hyperaemic areas and mucus were particularly determined in the inferior parts of the nasal concha. Hyperaemia of the subserosal vessels and petechia on the mucosa of the gastrointestinal tract and subcapsular petechia on the spleen were observed. The liver was dark red and the cut surface was bloody. Hyperaemia with lesions in eyes, opacity of the cornea and exudate with blood in the anterior and posterior parts of the camera oculi were determined. Subcapsular petechia, white foci 0.2-0.3 mm in diameter and infarcts were seen in the kidneys. On the cut surface of the cortex white foci of pinhead size and irregular yellowish necrotic areas at the border of cortex-medulla were observed. Some of the renal pelvis contained yellow, soft, friable material. In some cases, adhesion of the lungs to the costae was seen, and large subpleural haemorrhage and caseification areas were determined in some other cases. Bronchiectatic cavities were localised close to the bronchi

and bronchiole. In some of the lungs, consolidated areas and on the cut surface of these areas a grey-white-red purulent exudate were observed. A similar exudate was also detected in the lumens of the trachea and bronchi. Petechial areas were observed on the epicardia and endocardia of some dogs.

**Microscopic findings:** Hyperaemia and focal haemorrhage were determined in the cortex of the kidneys. Disseminated mononuclear cell infiltrations and large connective tissue were observed at intertubular areas. Some of the tubuli were cystic dilated, some of the tubular epithelia were degenerated and there were hyaline cylinders in some of the tubular lumens. In the medulla, there were granulomatous foci consisting of neutrophil leucocytes, macrophage cells and residues of chromatin encapsulated by a fibrous tissue (Figure 1). In the lungs, severely hyperaemic and large haemorrhagic areas and homogeneous pink necrotic areas were seen. There were a large number of neutrophil leucocytes, a fibrine mass, oedema and epithelial debris in the lumens of bronchi, bronchiole and alveoli. The granulomatous foci consisting of neutrophil leucocytes, macrophage and a few giant cells and residues of necrotic cells encapsulated with a fibrous tissue were seen particularly close to terminal bronchioles (Figures 2,3). The centres of these granulomatous foci were homogeneously pink. In the kidneys and lungs, the centres of these granulomatous foci contained hyphae with and without branching hyphae (Figures 4,5). In particular, hyphae invaded the vessels in some areas of the lungs. The hyphae branching in a radiating pattern were determined

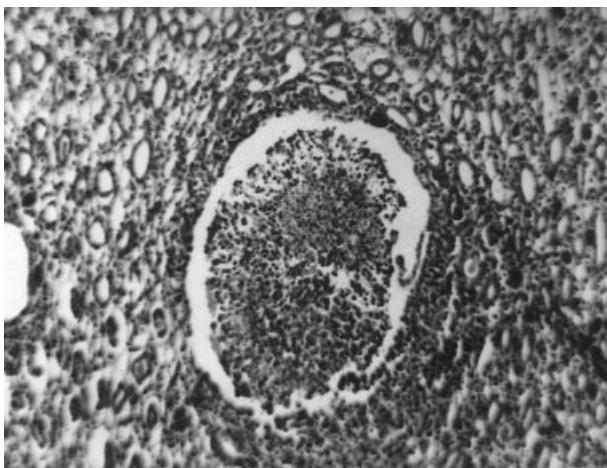


Figure 1. Granulomatous focus in medulla of kidney. H.E. stain, x 100.

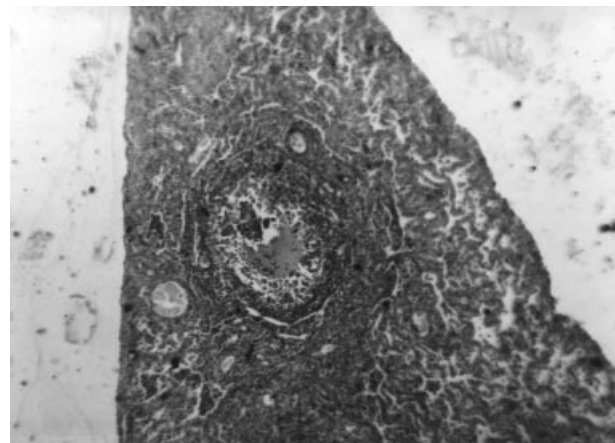


Figure 2. Granulomatous focus related to *A. fumigatus* in lung. H.E. stain, x 40.

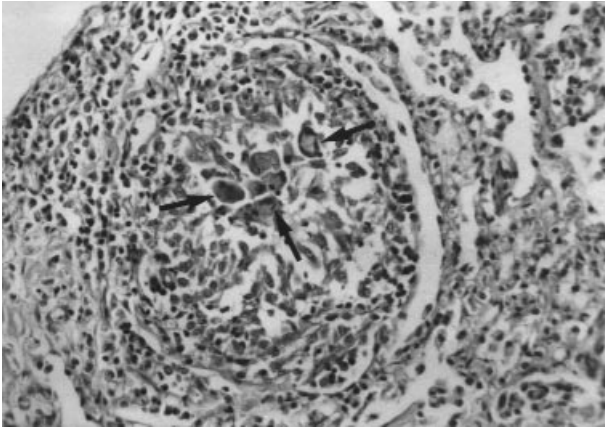


Figure 3. Giant cells in granuloma related to *A. fumigatus* in lung. H.E. stain, x 200.

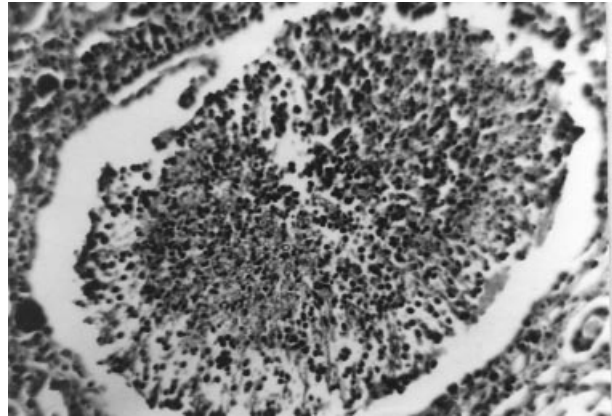


Figure 4. Hyphae of *A. fumigatus* with and without branching in granuloma in kidney. H.E. stain, x 200.

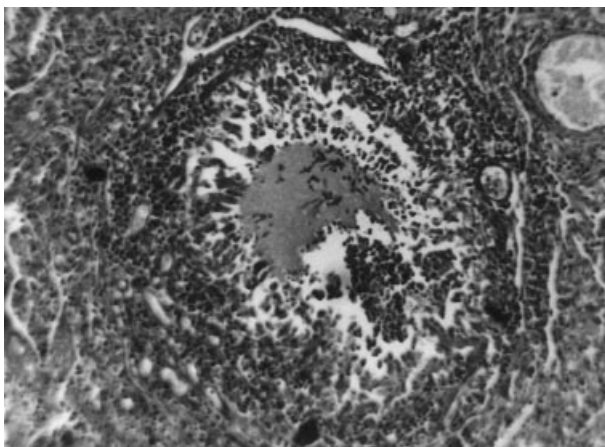


Figure 5. Hyphae of *A. fumigatus* with and without branching in granuloma in lung. H.E. stain, x 200.

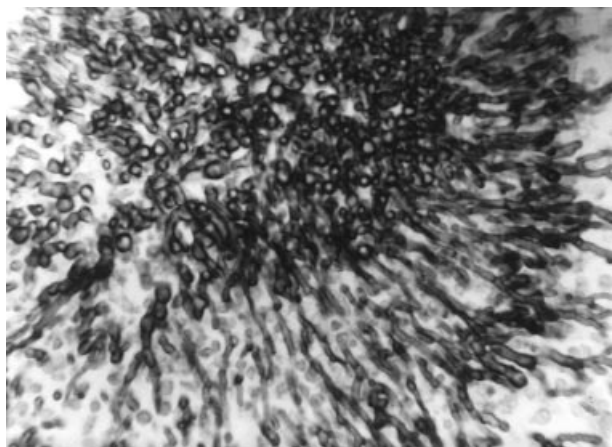


Figure 6. Hyphae of *A. fumigatus* with and without branching in granuloma in kidney. Gridley stain, x 400.

as *A. fumigatus* with the staining for differential diagnosis (Gridley and PAS) in the granulomatous foci (Figures 6-9). The hyperaemia and mononuclear cells, mostly consisting of lymphocytes and a small number of neutrophil leucocytes, were observed in the corpus ciliare of the eyes. Purple filamentous structures which could not be defined were observed in the cytoplasm or out of some cells. No lesions were observed on the sections of concha, gastrointestinal tract, liver, spleen, pancreas, brain, heart, skeletal muscle, urinary bladder, adrenal glands and lymph nodules, and no agents were determined with specific fungal staining. After the termination of the treatment, no pathological findings were observed except for the uveitis of the eyes of the dogs in group III.

## Discussion

The observed clinical findings of the present study were acute, severe and fatal, which was consistent with the findings of other researchers (3,4,10,13,14). The eye lesions, including lacrimation, corneal and conjunctival vascularisation and congestion, chemosis, corneal opacity, miosis, lack of pupillary reflexes and blindness, in 4 dogs in the present study were also observed by Gelatt et al. (2) and Willis et al. (16). In this study however, dogs exhibited exophthalmos in contrast to the findings of Gelatt et al. (2) and Willis et al. (16), who reported enophthalmos. Although *A. fumigatus* was isolated from eye tissue (2,16) in this study, a lack of the hyphae observed by PAS and Gridley staining of the eye tissue and a further absence of isolation of the agent from eye

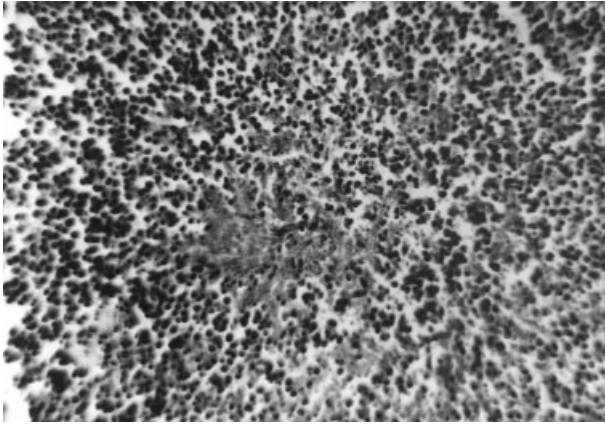


Figure 7. Hyphae of *A. fumigatus* with and without branching in granuloma in kidney. PAS stain, x 200.

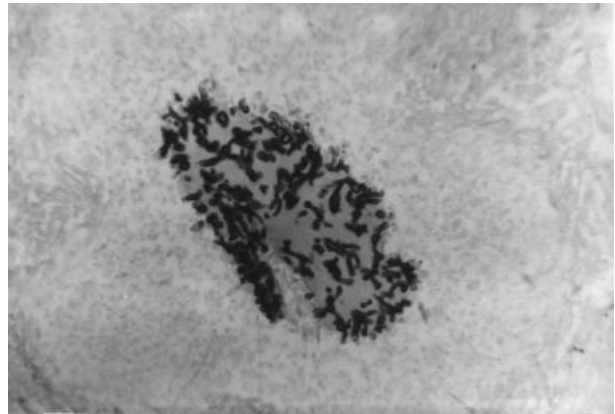


Figure 8. Hyphae of *A. fumigatus* with and without branching in granuloma in lung. Gridley stain, x 200.

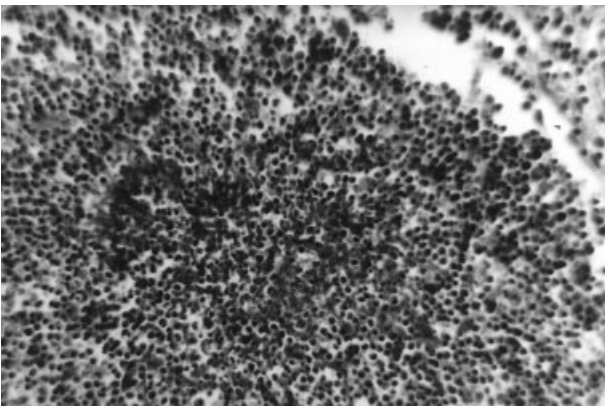


Figure 9. Hyphae of *A. fumigatus* with and without branching in granuloma in lung. PAS stain, x 200.

cultures may suggest that the eye lesions were associated with bacterial or protozoan infections.

Leucocytosis due to an increased number of monocytes, lymphocytes and granulocyte WBC was determined, as indicated in previous studies (2,14,16,20-22). This finding, which was supported by the histopathological observation of a large amount of mononuclear cell infiltration and the fewer neutrophil leucocytes in granulomatous inflammation areas, may show that cellular immunity, especially the reticuloendothelial system, is responsible for the defence against *A. fumigatus* infections (6,20,22,23). Consistent with the results of others (2,14,16,20-22), the reduction in Hgb and Hct values and RBC and PLT counts may result from severe infection. In the present study, although there were increased lymphocyte counts, the decreases in percentages of lymphocyte in WBC may result from the

suppression of lymphocyte blastogenesis by the products of *A. fumigatus* (16,24).

The results of the present study are consistent with the increases in serum ALP activity (2,20,25), urea (20,21), total protein (12,20) and globulin (25) and the decreases in the albumin (25) levels of other studies. Elevated urea, total protein and globulin levels may be the result of dehydration. The decreased glucose level may result from a lack of appetite. The hyperphosphataemia (12), proteinuria, haematuria, decreased specific gravity of the urine (2,4,12,20) and hypermagnesaemia suggest the kidneys were involved in the infection, which was supported by observation in the present study of the hyphae in the kidney tissue and isolation of the agent from the kidney cultures, and the urine samples.

Although the nasal cavity was reported as the most sensitive organ to naturally acquired *A. fumigatus* infection (2,5,9), our results showed that findings of histopathological and mycotic cultures indicate that the lungs and kidneys were more sensitive than the other organs.

Several antifungal drugs have been used for the treatment of aspergillosis (3,9-11,15), and these measures succeeded by 43-60%. Recently, itraconazole has been used in the treatment of aspergillosis (4,10,12), and is 5-100 times more effective against aspergillus spp. than ketoconazole, and has fewer side effects and a much longer half-life (15). Dallman et al. (1992) have reported that a dog with disseminated aspergillosis responded to itraconazole treatment but died due to a haemorrhage in the kidney vessel. However, Watt et al. (10) and Kelly et

al. (12) found that itraconazole was effective in treating aspergillosis in 1 out of 4 infected dogs, while the remaining dogs died for different reasons a long time after treatment. Therefore, the authors suggested that the treatment of aspergillosis with itraconazole had a positive effect on life span. Gilbert (3) reported a 60-70% success rate in the treatment of aspergillosis with itraconazole. In the present study, 4 out of 10 dogs died within the first week of treatment, and 6 dogs survived at the end of the treatment. All of the clinical signs in the surviving dogs were restored except for 2 dogs with exophthalmos, miosis, absence of pupillary reflexes and blindness, which may result from uveitis determined by histopathological examination. In all the surviving dogs, haematological, biochemical and urine analysis levels returned close to normal values. When the treatment was

stopped, 2 of the recovered dogs were euthanised for necropsy. No isolation of *A. fumigatus* from the organs, nasal swabs and urine samples, and a lack of histopathological lesions except for eye lesions confirmed that the itraconazole treatment was effective in 6 dogs.

In conclusion, since aspergillosis was located mainly in the lungs and kidneys according to observed clinical findings and changes in some of the haematological, biochemical and urine parameters supported by the histopathological findings and mycological culture, *A. fumigatus* should also be considered among the diseases of the lung and kidney. In addition, the approximately 60% success rate obtained with itraconazole in the present study may indicate that a large-scale and detailed study would be of practical value.

## References

- Arda, M.: Mikoloji, A.Ü. Basımevi, Ankara, 185-191, 1981.
- Gelatt, N.K., Chrisman, C.L., Samuelson, D.A., Shell, L., Buergelt, C.D.: Ocular and Systemic Aspergillosis in a Dog. J. Am. Anim. Hosp. Assoc. 1991; 27: 427-431.
- Gilbert, J.J.: Fungal Infections. In: The Merck Veterinary Manual, Eighth Edition. Ed. Susan, E.A. and Asa, M.A. Merck and Rhöne-Poulenc Company, Philadelphia, Pennsylvania. pp. 459-474, 1998.
- Dallman, M.J., Dew, T.L., Tobias, L., Doss, R.: Disseminated Aspergillosis in a Dog with Discospondylitis and Neurologic Deficits. J. Am. Vet. Med. Assoc. 1992; 200: 511-513.
- Jubb, K.V.F., Kennedy, P.C., Palmer, N.: Pathology of Domestic Animals, Fourth ed., Academic Press, San Diego, pp: 560-561, 660-670, 1993.
- Kabay, M.J., Robinson, W.F., Huxtable, C.R.R., McAleer, R.: The Pathology of Disseminated *Aspergillus terreus* Infections in Dogs. Vet. Pathol. 1985; 22: 540-547.
- Wood, G.L., Hirsh, D.C., Selcer, R.R., Rinaldi, M.G., Boormann, G. A.: Disseminated Aspergillosis in a Dog. J. Am. Vet. Med. Assoc. 1978; 172: 704-707.
- Am, W.: Fungal Diseases of the Nasal Cavity of the Dog and Cat. Vet. Clin. North. Am. Small Anim. Pract. 1992; 22: 1119-1132.
- Mathews, K.G., Davidson, A.P., Roplik, P.D., Richardson, E.F., Komtebedde, E.F., Papagianis, D., Hector, R.F., Kass, H.: Comparison of Topical Administration of Clotrimazole through Surgically Placed Versus Nonsurgically Placed Catheters for Treatment of Nasal Aspergillosis in Dogs. 60 Cases (1990-1996). J. Am. Vet. Med. Assoc. 1998; 213: 501-506.
- Watt, P.R., Robins, G.M., Galloway, A.M., O'Boyle, D.A.: Disseminated Opportunistic Fungal Disease in Dogs: 10 Cases (1982-1990). J. Am. Vet. Med. Assoc. 1995; 207: 67-70.
- Bedford, P.G.C.: Fungal rhinitis. In: Canine Medicine and Therapeutics, ed. Chandler, E.A., Thompsen, D.J., Suttten, J.B., Price, C.J. Third ed. Blackwell Scientific Publications., London. pp. 96-98, 1994.
- Kelly, S.E., Shaw, S.E., Clark, W.T.: Long Term Survival of Four Dogs with Disseminated *Aspergillus terreus* Infection Treated with Itraconazole. Aust. Vet. J. 1995; 72: 311-313.
- Pastor, J., Pumarola, M., Cuenca, R., Lavin, S.: Systemic Aspergillosis in a Dog. Vet. Rec. 1993; 132: 412-413.
- Mandal, P.C., Gupta, P. P.: Experimental Aspergillosis in Goats: Clinical, Haematological and Mycological Studies. J. Vet. Med. B. 1993; 40: 283-286.
- Helt, M.C., Riviere, J.M.E.: Antifungal and Antiviral Drugs. In: Veterinary Pharmacology and Therapeutics. Ed. Adams R. 7th ed. Iowa State University Press. Ames. pp. 855-883, 1995.
- Willis, A.M., Martin, C.L., Stiles, J.: Sino-Orbital Aspergillosis in a Dog. J. Am. Vet. Med. Assoc. 1999; 214: 1644-1647.
- Or, E., Dodurka, T., Ilgaz, A.: Dermatomikozisli Köpeklerin Tedavisinde Oral Itrakonazol Kullanımı. IV. Ulusal Veteriner İç Hastalıkları Kongresi., 4-6 Temmuz, Konya. 2001.
- Espinebingroff, A., Bartlett, M., Bowden, R., Chin, N.X., Cooper, C.: Multicenter Evaluation of Proposed Standardized Procedure for Antifungal Susceptibility Testing of Filamentous Fungi. J. Clin. Microbiol. 1997; 35: 139-143.
- Düzgüneş, O., Kesici, T., Gürbüz F.: İstatistik Metotları, A.Ü. Vet. Fak. Yay. 861, A.Ü. Basımevi, Ankara. 1983.

20. Day, M.J., Penhale, W.J., Eger, C.E., Shaw, S.E., Kabay, M.J., Robinson, W.F., Huxtable, C.R.R., Mills, J.N., Wyburn, R.S.: Disseminated aspergillosis in dogs. *Aust. Vet. J.* 1986; 63: 55-59.
21. Peet, R.L., Robertson, I. D.: Suspected Aspergillosis in a Dog. *Aust. Vet. J.* 1976; 52: 539-540
22. Southard, C.: Bronchopulmonary Aspergillosis in a Dog. *J. Am. Vet. Med. Assoc.* 1987; 190: 875-877.
23. Pérez, J., Mozos, E., Chacón-M. De Lara, F., Paniagua, J., Day, M.J.: Disseminated Aspergillosis in a Dog: an Immunohistochemical Study. *J. Comp. Path.* 1996; 115: 191-196.
24. Chaparas, S.D., Morgan, P.A., Holobaugh, P.: Inhibition of Cellular Immunity by Products of *Aspergillus fumigatus*. *J. Med. Vet. Mycol.* 1986; 24: 67-76.
25. Kahler, J.S., Leach, M.W., Jang, S., Wong, A.: Disseminated Aspergillosis Attributable to *Aspergillus deflexus* in a Springer Spaniel. *J. Am. Vet. Med. Assoc.* 1990; 197: 871-874.