

1-1-2014

Anti TNF- α therapy might be responsible for an increased incidence of varicocele in patients with ankylosing spondylitis

ÖMER YILMAZ

YUNUS UGAN

MAHMUT YENER

MEHMET UMUL

MUSTAFA KAYAN

See next page for additional authors

Follow this and additional works at: <https://journals.tubitak.gov.tr/medical>

 Part of the [Medical Sciences Commons](#)

Recommended Citation

YILMAZ, ÖMER; UGAN, YUNUS; YENER, MAHMUT; UMUL, MEHMET; KAYAN, MUSTAFA; AKTAŞ, AYKUT RECEP; ÜNLÜ, ELİF NİSA; KISACIK, BÜNYAMİN; DEĞİRMENCİ, BUMİN; and ÇETİN, MELTEM (2014) "Anti TNF- α therapy might be responsible for an increased incidence of varicocele in patients with ankylosing spondylitis," *Turkish Journal of Medical Sciences*: Vol. 44: No. 2, Article 24. <https://doi.org/10.3906/sag-1302-136>

Available at: <https://journals.tubitak.gov.tr/medical/vol44/iss2/24>

This Article is brought to you for free and open access by TÜBİTAK Academic Journals. It has been accepted for inclusion in Turkish Journal of Medical Sciences by an authorized editor of TÜBİTAK Academic Journals. For more information, please contact academic.publications@tubitak.gov.tr.

Anti TNF- α therapy might be responsible for an increased incidence of varicocele in patients with ankylosing spondylitis

Authors

ÖMER YILMAZ, YUNUS UGAN, MAHMUT YENER, MEHMET UMUL, MUSTAFA KAYAN, AYKUT RECEP AKTAŞ, ELİF NİSA ÜNLÜ, BÜNYAMİN KISACIK, BUMİN DEĞİRMENÇİ, and MELTEM ÇETİN

Anti TNF- α therapy might be responsible for an increased incidence of varicocele in patients with ankylosing spondylitis

Ömer YILMAZ^{1*}, Yunus UGAN², Mahmut YENER³, Mehmet UMUL⁴, Mustafa KAYAN¹, Aykut Recep AKTAŞ¹, Elif Nisa ÜNLÜ¹, Bünyamin KISACIK⁵, Bumin DEĞİRMENÇİ¹, Meltem ÇETİN¹

¹Department of Radiology, Faculty of Medicine, Süleyman Demirel University, Isparta, Turkey

²Department of Rheumatology, Faculty of Medicine, Süleyman Demirel University, Isparta, Turkey

³Department of Physical Therapy and Rehabilitation, Faculty of Medicine, Süleyman Demirel University, Isparta, Turkey

⁴Department of Urology, Faculty of Medicine, Süleyman Demirel University, Isparta, Turkey

⁵Department of Rheumatology, Faculty of Medicine, Gaziantep University, Gaziantep, Turkey

Received: 27.02.2013

Accepted: 21.04.2013

Published Online: 15.01.2014

Printed: 14.02.2014

Aim: To evaluate the effects of anti-tumor necrosis factor-alpha (TNF- α) therapy on the frequency of varicocele in patients with ankylosing spondylitis (AS) using color Doppler ultrasound.

Materials and methods: The patients were divided into 2 groups: patients with AS who were on anti-TNF- α treatment and patients with AS who were not regularly taking any antiinflammatory drugs. Thirty-one healthy volunteers were included as controls.

Results: Left-sided varicocele was determined in 14 patients of Group 1 (44%), 10 patients of Group 2 (33%), and 7 of the controls (23%). There was a statistically significant difference only between Group 1 and controls ($P = 0.009$). However, right-sided varicocele was determined in 12 patients of Group 1 (38%), 2 patients of Group 2 (6%), and 2 of the controls (6%) ($P = 0.01$ vs. Group 2, $P = 0.005$ vs. controls).

Conclusion: The present study shows that patients with AS who were taking anti-TNF- α therapy had an increased prevalence of right-sided and bilateral varicocele compared to patients with AS who were not taking any disease-modifying antirheumatic drugs and the healthy control group.

Key words: Varicocele, ankylosing spondylitis, color Doppler ultrasound

1. Introduction

Ankylosing spondylitis (AS) is a chronic systemic inflammatory disease that predominantly affects young men (1). A combination of genetic and immune factors is responsible for its pathogenesis; it often affects the axial skeleton, entheses regions, and, occasionally, peripheral joints (2). AS may incorporate extraarticular manifestations including vascular involvement (1,3). The association of AS and vascular involvement is common, but the exact causes are not fully known (3).

On the other hand, it has recently been shown that there is a relationship between AS and the development of varicocele (4,5). Varicocele is defined as the abnormal dilatation and tortuosity of the pampiniform plexus veins. It mainly occurs on the left side and can be associated with infertility in men (6). Varicocele may be clinical or subclinical. Clinical varicocele can be detected and graded by physical examination (7). However, subclinical

varicocele is not palpable and requires imaging techniques for diagnosis, especially color Doppler ultrasound (8,9). Color Doppler sonography is a much more reliable and reproducible technique and is currently considered as the gold standard for the diagnosis of varicocele (6,10). There are 2 types of varicocele. The primary type affects nearly one-sixth of the male population and its etiopathogenesis is unclear (11). The secondary form of varicocele emerges as a result of diseases that cause high pressure levels on the testicular vein, like constipation, hydronephrosis, neoplasms, and cirrhosis, or after abdominal operations (12).

Tumor necrosis factor-alpha (TNF- α) is initially synthesized by activated macrophages and T cells as a transmembrane precursor protein. TNF- α is important for macrophage and phagosome activation, differentiation of monocytes to macrophages, granuloma formation, and maintenance of granuloma integrity (13). Given the

* Correspondence: doktorlar77@hotmail.com

crucial role of TNF- α in many autoinflammatory diseases, in order to prevent damaging the signaling pathways, a protein-based soluble receptor antagonist and monoclonal antibodies are used (14). TNF- α is a major cytokine that is strongly related to disease activity and to the severity of inflammation in patients with AS (3); therefore, TNF- α blocking agents have become commonly used drugs in the treatment of AS (15). However, the effects of anti-TNF- α treatment on AS-related vascular changes has been poorly studied (16,17), and previous results are controversial. Since AS is associated with an increased incidence of varicocele and vascular involvement, and TNF- α blocking agents are commonly used in patients with AS, we aim to evaluate the effects of anti-TNF- α therapy on the frequency of varicocele in patients with AS using color Doppler ultrasound.

2. Materials and methods

2.1. Study population

The study consisted of 63 adult male patients who met the modified New York criteria for AS (18). The patients with AS were divided into 2 groups: 1) patients with AS who were on anti-TNF- α treatment according to the Assessment in AS (ASAS) group guidelines (19,20) and 2) patients with AS who were not regularly taking any antiinflammatory drugs, including nonsteroid antiinflammatory drugs. The patients that had a history of atherosclerotic diseases, such as coronary artery disease and cerebrovascular disease, or systemic diseases such as diabetes mellitus, hypertension, and renal failure, were excluded. Subjects receiving lipid-lowering drugs were also excluded. A comprehensive physical examination was applied by an expert rheumatologist, and all patients were appraised for disease characteristics. Clinical data on AS, such as disease duration and drug usage, were obtained from file records and patients' medical histories. The same clinician evaluated the patients in terms of scrotal masses or pain, and the subjects were clinically categorized as having the presence or absence of varicocele. Thirty-one healthy male volunteers with no distinct symptoms or signs associated with genitourinary system disorders were included as the control group. The local ethics committee approved the study protocol, and all participants provided written informed consent.

2.2. Sonographic assessment

A color Doppler ultrasound scanner (Aplio 80; Toshiba, Tokyo, Japan) equipped with a 5- to 10-MHz linear transducer was used for sonographic examination. The diameters of the pampiniform plexus veins on the gray-scale imaging were measured. The patient was placed in

a supine position, and all measurements were made both at rest and during the Valsalva maneuver (21). Varicocele was diagnosed based on standard sonographic criteria, including a pampiniform plexus vein diameter exceeding 2.5 mm at rest and a reversed flow duration of greater than 1 s during the Valsalva maneuver. For the same vessel, the measurements were obtained 3 times using the multiplanar scanning technique and then averaged. Sonographic examinations were performed by 2 sonographers who were experts on color Doppler ultrasound examination and were unaware of the patients' clinical data. Intra- and interobserver agreement for the measurements was evaluated in all groups. Intra- and interobserver agreement rates for the pampiniform plexus vein measurements by the 2 examiners were 97% and 94.5%, respectively.

2.3. Statistical analyses

The analyses were performed using SPSS 15.0 for Windows (SPSS, Chicago, IL, USA). Categorical variables were expressed as number and percentage, and numeric data were expressed as mean \pm SD. The groups were compared using the chi-square test regarding categorical variables. One-way ANOVA followed by Tukey's test was used to compare continuous variables. A P-value of less than 0.05 was considered significant.

3. Results

Age, duration of AS, and varicocele status of the groups are presented in the Table. Age did not significantly differ among the groups (30.28 ± 7.15 years for Group 1, 28 ± 4.81 for Group 2, and 28.25 ± 3.59 for controls). The disease durations were similar between the 2 AS groups (79.6 ± 44.0 vs. 88.8 ± 34.7 months). Group 1 patients were receiving anti-TNF- α treatment for 6 to 48 months; however, there was no significant correlation between the duration of the anti-TNF- α therapy and the development of varicocele. In physical examinations, varicocele was detected in 13 patients of Group 1 (41%), 10 patients of Group 2 (33%), and 9 controls (29%); however, these differences were not statistically significant. In the color Doppler examination, left-sided varicocele was determined in 14 patients of Group 1 (44%), 10 patients of Group 2 (33%), and 7 controls (23%). There was only a statistically significant difference between Group 1 and the controls ($P = 0.009$; Figures 1 and 2). Right-sided varicocele was determined in 12 patients of Group 1 (38%), 2 patients of Group 2 (6%), and 2 controls (6%) ($P = 0.01$ vs. Group 2, $P = 0.005$ vs. controls). The diameters of both left and right pampiniform plexus veins did not significantly differ among the groups. Similarly, reversed flows during the Valsalva maneuver were similar among the groups.

Table. Demographic characteristics and color Doppler findings of the groups.

Characteristics	Group 1 (n = 32)	Group 2 (n = 31)	Controls (n = 31)	P
Age, years	30.28 ± 7.15	28 ± 4.81	28.25 ± 3.59	NS
Varicocele in clinical examination	13/32 (40.6%)	10/31 (32.25%)	9/31 (29.03%)	NS
Color Doppler findings				
Right pampiniform plexus, rest, mm	1.83 ± 0.57	1.62 ± 0.32	1.68 ± 0.67	NS
Left pampiniform plexus, rest, mm	2.24 ± 0.61	2.04 ± 0.6	1.91 ± 0.71	NS
Right pampiniform plexus, Valsalva, mm	2.28 ± 0.56	1.95 ± 0.43	2.00 ± 0.82	NS
Left pampiniform plexus, Valsalva, mm	2.75 ± 0.68	2.42 ± 0.76	2.28 ± 0.9	NS
Right sided varicocele	12/32 (37.5%)	2/31 (6.45%)	2/31 (6.45%)	0.005 ^{1,2}
Left sided varicocele	14/32 (43.75%)	10/31 (32.25%)	7/31 (22.5%)	0.009 ¹
Bilateral varicocele	11/32 (34.37%)	2/31 (6.45%)	2/31 (6.45%)	0.01 ^{1,2}

Values are mean ± SD and number (percentage). NS indicates not significant ($P > 0.05$).

¹Between group 1 and control groups.

²Between group 1 and group 2.

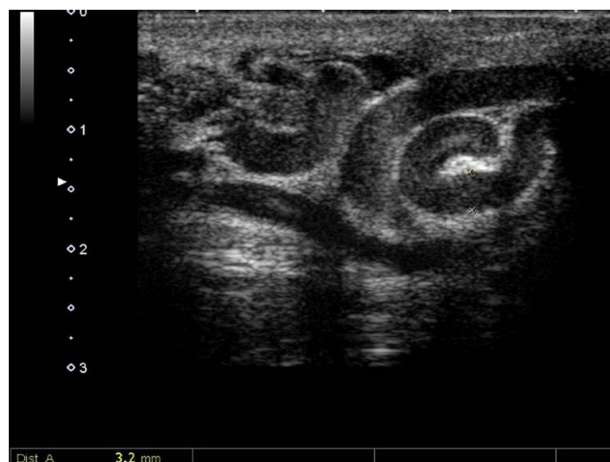

Figure 1. Varicose veins of the pampiniform plexus (arrows) in a 25-year-old male patient with ankylosing spondylitis.

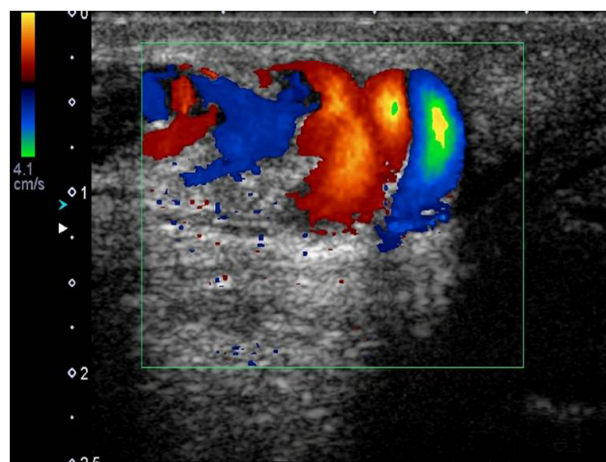


Figure 2. Color and spectral Doppler images show reversed flow during the Valsalva maneuver on left sided varicocele in a 25-year-old patient with ankylosing spondylitis.

4. Discussion

In the present study, we found that patients with AS who were taking anti-TNF- α therapy had an increased prevalence of right-sided and bilateral varicocele compared to patients with AS who were not taking any disease-modifying antirheumatic drugs and to the healthy control group. The prevalence of left-sided varicocele was also significantly higher in patients with AS who were receiving anti-TNF- α therapy. The present research is a pilot study showing a possible association between anti-TNF- α therapy and the frequency of varicocele.

Varicocele is the most common reversible cause of infertility (22,23). Anatomical variations and valvular incompetence of testicular veins are the most common etiological factors, with left-sided dominance (24). The other etiological factors of varicocele are constipation, effects of physical activity, body stature, spinal cord injury, and rheumatologic disorders such as Behçet's disease and AS (5,21,25–28).

Recently, the prevalence of varicocele in patients with AS was reported to be as high as 57% and 40% (4,5). Although the relationship between AS and an

increased frequency of varicocele has been reported, the underlying mechanisms of this association have not been clarified. Several plausible mechanisms have been suggested regarding the increased prevalence of varicocele in patients with AS. The first is endothelial dysfunction. Previous studies clearly demonstrated that patients with AS have impaired endothelial function and subclinical atherosclerosis using carotid intima-media thickness, brachial flow mediated dilatation, and aortic pulse wave velocity. Microparticles, which are mainly released from platelets, leukocytes, and endothelial cells, play an important role in pathological processes of inflammation. Therefore, they are considered as a surrogate marker of endothelial dysfunction and vascular damage. It was shown that patients with AS who are treated with biological anti-TNF- α therapy have significantly reduced endothelial and platelet microparticles (29).

The second possible mechanism is mechanical overload. It is speculated that the presence of incompetent valves within the spermatic vein results in retrograde venous flow and is primarily responsible for the development of varicocele, which is negatively affected by the Valsalva maneuver (6). Patients with AS have weak low back muscles due to chronic low back pain. Therefore, it may be much more important for patients with AS to compensate for this weakness using the Valsalva maneuver during their daily living activities. Increased abdominal pressure leads to a mechanical overload to the testicular vessels and can facilitate the development of varicocele.

The third mechanism is increased oxidative stress. It was reported that there is an association between nitric oxide (NO) levels and frequency of varicocele (30). NO is a water-soluble and lipid-soluble free radical that plays an important role in the modulation of blood flow (31). Microcirculatory stagnation of blood was found to be associated with hypoxia in testes of men with varicocele (32). The increase in nitric oxide synthase (NOS) activity in varicocele seems to be a compensatory mechanism to reduce the effect of hypoxia by increasing testicular blood flow (33). Briefly, NO is a strong vasodilator, determining vasodilatation and contributing to blood stasis, resulting in the generation and progression of varicocele. Shiraiishi et al. reported a strong correlation between nitrite concentration and the internal spermatic vein diameter (31). Ozgocmen et al. (4) reported that NO levels in the sera of individuals drawn from the dilated spermatic vein were nearly 2-fold higher than in the sera from the peripheral vein. The authors suggested that there was a high oxidative stress due to the release of NO synthase and

xanthine oxidase within the dilated spermatic vein and that spermatozoa function might be adversely affected by the rise of the NO levels in the dilated spermatic vein (34). In another study, Mitropoulos et al. (35) proposed that the formation of peroxynitrite from the reaction of NO with superoxide could be a causative factor for impaired sperm function in patients with varicocele.

TNF- α is involved in reducing vascular NO availability. This process might be a result of the activation of nicotinamide adenine dinucleotide phosphate (NAD[P]H) oxidase and inducible NOS (iNOS), or the inhibition of endothelial NOS (eNOS) activity, which causes the induction of reactive oxygen species (36). In addition, expression of phosphodiesterase type 5 has been shown to be upregulated by TNF- α , which may blunt the proerectile action of NO (37). Accordingly, it has been demonstrated that blockage of TNF- α activity by anti-TNF- α therapy may result in NOS expression, which causes cavernosal smooth muscle relaxation (38). In this respect, it can be argued that anti-TNF- α therapy induces endothelial relaxation. In the present study, we found that anti-TNF- α therapy was associated with increased frequency of varicocele in patients with AS. We believe that anti-TNF- α therapy induces endothelial eNOS activity, resulting in increased synthesis of NO. Consequently, increased levels of NO can augment dilatation of testicular veins and facilitate the development of varicocele in patients with AS.

In conclusion, the present study found that patients with AS who were receiving anti-TNF- α therapy had an increased prevalence of right-sided and bilateral varicocele as compared to patients with AS who were not taking any disease-modifying antirheumatic drugs and to the healthy control group. This pilot study shows a possible association between anti-TNF- α therapy and the frequency of varicocele. Further large prospective randomized studies are needed to determine the underlying mechanisms of the increased prevalence of varicocele and the possible association between anti-TNF- α therapy and the frequency of varicocele in patients with AS.

Several study limitations should be noted. The present study had a relatively small sample size. A larger number of subjects is needed to determine the mechanism of varicocele formation in patients with AS who are receiving anti-TNF- α therapy. Additionally, sperm analyses of patients were not done. A spermogram could have shown a possible increased incidence of sperm abnormalities in patients with AS and varicocele who were receiving anti-TNF- α therapy.

References

1. Arnett FC. Ankylosing spondylitis. In: Koopman WJ, editor. *Arthritis and Allied Conditions*. Philadelphia, PA, USA: Lippincott Williams and Wilkins; 2001. pp. 1311–1323.
2. Khan MA. Ankylosing spondylitis: clinical features. In: Klippel J, Dieppe P, editors. *Rheumatology*. 2nd ed. London: Mosby-Wolfe; 1998. pp. 6.16.1–6.16.10.
3. Mathieu S, Joly H, Baron G, Tournadre A, Dubost JJ, Ristori JM, Luson JR, Soubrier M. Trend towards increased arterial stiffness or intima-media thickness in ankylosing spondylitis patients without clinically evident cardiovascular disease. *Rheumatology* 2008; 47: 1203–1207.
4. Ozgocmen S, Kocakoc E, Kiris A, Ardicoglu A, Ardicoglu O. Incidence of varicoceles in patients with ankylosing spondylitis evaluated by physical examination and color duplex sonography. *Urology* 2002; 59: 919–922.
5. Nukumizu L, Saad CG, Ostensen M, Almeida B, Cocuzza M, Gonçalves C, Saito O, Bonfá E, Silva CA. Gonadal function in male patients with ankylosing spondylitis. *Scand J Rheumatol* 2012; 41: 476–481.
6. Meacham RB, Townsend RR, Rademacher D, Droese JA. The incidence of varicoceles in the general population when evaluated by physical examination, gray scale sonography and color Doppler sonography. *J Urol* 1994; 151: 1535–1538.
7. Dubin L, Amelar RD. Varicoectomy: 986 cases in a twelve-year study. *Urology* 1977; 10: 446–449.
8. Lee J, Binsaleh S, Lo K, Jarvi K. Varicoceles: the diagnostic dilemma. *J Androl* 2008; 29: 143–146.
9. Vurdem ÜE, Acer N, Ertekin T, Savranlar A, Topuz Ö, Keçeli M. Comparison of three volumetric techniques for estimating thyroid gland volume. *Turk J Med Sci* 2012; 42: 1299–1306.
10. Ogul H, Bayraktutan U, Yildirim OS, Suma S, Ozgokce M, Okur A, Kantarci M. Magnetic resonance arthrography of the glenohumeral joint: ultrasonography-guided technique using a posterior approach. *EAJM* 2012; 44: 73–78.
11. Mehta AL, Dogra VS. Intratesticular varicocele. *J Clin Ultrasound* 1998; 26: 49–51.
12. Turgut AT, Özden E, Koşar P, Koşar U, Çakal B, Karabulut A. Chronic constipation as a causative factor for development of varicocele in men: a prospective ultrasonographic study. *J Ultrasound Med* 2007; 26: 5–10.
13. Koo S, Marty FM, Baden LR. Infectious complications associated with immunomodulating biologic agents. *Infect Dis Clin North Am* 2010; 24: 285–306.
14. Palladino MA, Bahjat FR, Theodorakis EA, Moldawer LL. Anti-TNF-alpha therapies: the next generation. *Nat Rev Drug Discov* 2003; 2: 736–746.
15. van Eijk IC, Peters MJ, Serné EH, van der Horst-Bruinsma IE, Dijkmans BA, Smulders YM, Nurmohamed MT. Microvascular function is impaired in ankylosing spondylitis and improves after tumour necrosis factor alpha blockade. *Ann Rheum Dis* 2009; 68: 362–366.
16. Pieringer H, Stuby U, Pohanka E, Biesenbach G. Augmentation index in patients with rheumatoid arthritis and ankylosing spondylitis treated with infliximab. *Clin Rheumatol* 2010; 29: 723–727.
17. Syngle A, Vohra K, Sharma A, Kaur L. Endothelial dysfunction in ankylosing spondylitis improves after tumor necrosis factor-alpha blockade. *Clin Rheumatol* 2010; 29: 763–770.
18. Van der Linden S, Valkenburg HA, Cats A. Evaluation of diagnostic criteria for ankylosing spondylitis. A proposal for modification of the New York criteria. *Arthritis Rheum* 1984; 27: 361–368.
19. Braun J, Pham T, Sieper J, Davis J, van der Linden S, Dougados M, van der Heijde D; AS Working Group. International ASAS consensus statement for the use of anti-tumour necrosis factor agents in patients with ankylosing spondylitis. *Ann Rheum Dis* 2003; 62: 817–824.
20. Aydingoz U, Yildiz AE, Ozdemir ZM, Yildirim SA, Erkus F, Ergen FB. A critical overview of the imaging arm of the ASAS criteria for diagnosing axial spondyloarthritis: what the radiologist should know. *Diagn Interv Radiol* 2012; 18: 555–565.
21. Yilmaz O, Yilmaz S, Kisacik B, Aydogdu M, Bozkurt Y, Erdem H, Pay S, Saglam M, Dinc A. Varicocele and epididymitis in Behçet disease. *J Ultrasound Med* 2011; 30: 909–913.
22. Jarow JP, Coburn M, Sigman M. Incidence of varicoceles in men with primary and secondary infertility. *Urology* 1996; 47: 73–76.
23. Tarazov P, Prozorovskij K, Rumiantseva S. Pregnancy after embolization of an ovarian varicocele associated with infertility: report of two cases. *Diagn Interv Radiol* 2011; 17: 174–176.
24. Brugh VM 3rd, Matschke HM, Lipshultz LI. Male factor infertility. *Endocrinol Metab Clin N Am* 2003; 32: 689–707.
25. Ünsal A, Yilmaz B, Turgut AT, Taşkın F, Alaca R, Karaman CZ. Evaluation of varicocele frequency of patients with spinal cord injury by color Doppler ultrasonography: a new etiological factor for varicocele? *Eur J Radiol* 2006; 57: 154–157.
26. Akdağ T, Tiftik AM, Saryıldız L. A comparative investigation of anti-Müllerian hormone (AMH) and various biochemical parameters in patients with cryptorchidism, oligospermia, or varicocele. *Turk J Med Sci* 2012; 42: 411–415.
27. Arslan H, Tezcan FM, Algın O. Urothelial cancers: clinical and imaging evaluation. *Turk J Med Sci* 2012; 42: 1335–1364.
28. Sari S, Kara K, Verim S, Karahan N. Gastric foregut duplication cyst as a rare cause of abdominal pain. *EAJM* 2012; 44: 182–184.
29. Sari I, Bozkaya G, Kirbiyik H, Alacacioglu A, Ates H, Sop G, Can G, Taylan A, Piskin O, Yildiz Y et al. Evaluation of circulating endothelial and platelet microparticles in men with ankylosing spondylitis. *J Rheumatol* 2012; 39: 594–599.

30. Al-Nimer MSM, Al-Obaidi SAH, Al-Dulaimi KS. Serum nitric oxide and peroxy-nitrite levels in adult sero-positive rheumatoid arthritis treated with disease modifying antirheumatic drugs: a preliminary report. *Turk J Med Sci* 2010; 40: 191–197.
31. Shiraishi K, Naito K. Nitric oxide produced in the testis is involved in dilatation of the internal spermatic vein that compromises spermatogenesis in infertile men with varicocele. *BJU Int* 2007; 99: 1086–1090.
32. Chakraborty J, Sinha Hikim AP, Jhunjhunwala JS. Stagnation of blood in the microcirculatory vessels in the testes of men with varicocele. *J Androl* 1985; 6: 117–126.
33. Lissbrant E, Löfmark U, Collin O, Bergh A. Is nitric oxide involved in the regulation of the rat testicular vasculature? *Biol Reprod* 1997; 56: 1221–1227.
34. Ozbek E, Turkoz Y, Gokdeniz R, Davarci M, Ozugurlu F. Increased nitric oxide production in the spermatic vein of patients with varicocele. *Eur Urol* 2000; 37: 172–175.
35. Mitropoulos D, Deliconstantinos G, Zervas A, Villiotou V, Dimopoulos C, Stavrides J. Nitric oxide synthase and xanthine oxidase activities in the spermatic vein of patients with varicocele: a potential role for nitric oxide and peroxy-nitrite in sperm dysfunction. *J Urol* 1996; 156: 1952–1958.
36. Zhang H, Park Y, Wu J, Chen XP, Lee S, Yang J, Dellsperger KC, Zhang C. Role of TNF-alpha in vascular dysfunction. *Clin Sci* 2009; 116: 219–230.
37. Hotston MR, Jeremy JY, Bloor J, Koupparis A, Persad R, Shukla N. Sildenafil inhibits the up-regulation of phosphodiesterase type 5 elicited with nicotine and tumour necrosis factor-alpha in cavernosal vascular smooth muscle cells: mediation by superoxide. *BJU Int* 2007; 99: 612–618.
38. Carneiro FS, Sturgis LC, Giachini FR, Carneiro ZN, Lima VV, Wynne BM, San Martin S, Brands MW, Tostes RC, Webb RC. TNF-alpha knockout mice have increased corpora cavernosa relaxation. *J Sex Med* 2009; 6: 115–125.