

1-1-2015

## Two gastrointestinal conditions with similar symptoms and endoscopic appearance: irritable bowel syndrome and microscopic colitis

ZAHİDE ŞİMŞEK

NAZİFE CANDAN TUNÇER

HAKAN ALAGÖZLÜ

FATİH KARAAHMET

ŞAHİN ÇOBAN

*See next page for additional authors*

Follow this and additional works at: <https://journals.tubitak.gov.tr/medical>

 Part of the [Medical Sciences Commons](#)

---

### Recommended Citation

ŞİMŞEK, ZAHİDE; TUNÇER, NAZİFE CANDAN; ALAGÖZLÜ, HAKAN; KARAAHMET, FATİH; ÇOBAN, ŞAHİN; and DURSUN, AYŞE (2015) "Two gastrointestinal conditions with similar symptoms and endoscopic appearance: irritable bowel syndrome and microscopic colitis," *Turkish Journal of Medical Sciences*: Vol. 45: No. 2, Article 21. <https://doi.org/10.3906/sag-1401-88>  
Available at: <https://journals.tubitak.gov.tr/medical/vol45/iss2/21>

This Article is brought to you for free and open access by TÜBİTAK Academic Journals. It has been accepted for inclusion in Turkish Journal of Medical Sciences by an authorized editor of TÜBİTAK Academic Journals. For more information, please contact [academic.publications@tubitak.gov.tr](mailto:academic.publications@tubitak.gov.tr).

---

## Two gastrointestinal conditions with similar symptoms and endoscopic appearance: irritable bowel syndrome and microscopic colitis

### Authors

ZAHİDE ŐİMŐEK, NAZİFE CANDAN TUNŐER, HAKAN ALAGÖZLÜ, FATİH KARAAHMET, ŐAHİN  OBAN,  
and AYŐE DURSUN

## Two gastrointestinal conditions with similar symptoms and endoscopic appearance: irritable bowel syndrome and microscopic colitis

Zahide ŞİMŞEK<sup>1</sup>, Nazife Candan TUNCER<sup>2</sup>, Hakan ALAGÖZLÜ<sup>3</sup>,  
Fatih KARAAHMET<sup>1\*</sup>, Şahin ÇOBAN<sup>1</sup>, Ayşe DURSUN<sup>4</sup>

<sup>1</sup>Department of Gastroenterology, Dışkapı Yıldırım Beyazıt Educational and Research Hospital, Ankara, Turkey

<sup>2</sup>Department of Gastroenterology, Faculty of Medicine, Gazi University, Ankara, Turkey

<sup>3</sup>Department of Gastroenterology, Faculty of Medicine, Cumhuriyet University, Sivas, Turkey

<sup>4</sup>Department of Pathology, Faculty of Medicine, Gazi University, Ankara, Turkey

Received: 21.01.2014

Accepted: 20.06.2014

Published Online: 01.04.2015

Printed: 30.04.2015

**Background/aim:** Irritable bowel syndrome (IBS) is a gastrointestinal condition characterized by chronic abdominal pain, discomfort, bloating, and alteration of bowel habits in the absence of any organic cause. This trial investigated the presence of microscopic colitis (MC) and associated factors related to MC in patients diagnosed with IBS.

**Materials and methods:** The study group (group I) consisted of 91 consecutive patients diagnosed with IBS based on the Rome III Criteria for whom colonoscopic examination was requested. The control group (group II) had 41 patients diagnosed with IBS considered as eligible for colonoscopic investigation due to specific conditions, and for whom colonoscopic examination was recommended for screening purposes due to a familial history of colon cancer. Clinical data, endoscopic findings, and the effects of the therapy were evaluated.

**Results:** In the diarrhea-predominant IBS group, nine patients (9.89%) were diagnosed with microscopic colitis, seven with lymphocytic colitis (7.69%), and two with collagenous colitis (CC) (2.19%). None of the patients in group II were found to have MC (P = 0.007). There were no diagnoses of MC in the constipation-predominant and mixed type IBS groups.

**Conclusion:** Clinicians should keep MC in mind for patients presenting with diarrhea-predominant IBS symptoms.

**Key words:** Irritable bowel syndrome, collagenous colitis, lymphocytic colitis

### 1. Introduction

Irritable bowel syndrome (IBS) is one of the most common gastrointestinal conditions with a symptom-based diagnosis. IBS is characterized by abdominal pain and discomfort, bloating, and alteration of bowel habits in the absence of any organic cause. The pathogenesis of IBS remains uncertain, but recent studies have considered the role of inflammation, alterations in fecal flora, bacterial overgrowth, and a chronic low-grade inflammation of the gastrointestinal mucosa (1). Diagnosis is symptom-based because there are no biological, anatomical, physiological, or colonoscopic markers for IBS and diagnostic criteria should be fulfilled by the patients. Well-known algorithms for diagnosis include the Manning criteria, the obsolete Rome I and II criteria, the Kruis criteria, and the more recent Rome III process (2). Furthermore, a variety of dietary, pharmacological, and psychological treatments have been studied in patients with IBS, but there is no

proven effective management for IBS. It also has significant effects on quality of life with a high social cost. The total cost of IBS in the United States has been estimated at \$21.7–\$30 billion (3).

Several conditions with diarrhea may present as diarrhea-predominant IBS, including parasitic infections like giardiasis, fructose and bile acid malabsorption, small intestinal bacterial overgrowth, inflammatory bowel diseases, celiac disease, and microscopic colitis (MC). MC may have a role among these conditions owing to its similar symptoms and endoscopic appearance. Evaluation of such patients may lead to a misdiagnosis of MC in patients with IBS. Chronic diarrhea is the main symptom both in patients with MC and diarrhea-predominant IBS, but collagenous colitis and/or lymphocytic colitis might be related to constipation and they are often accompanied by abdominal pain (4,5). Furthermore, the mucosa appears grossly normal or nearly normal at colonoscopy

\* Correspondence: fatih\_ares@yahoo.com.tr

(6). In the presence of appropriate clinical symptoms, the diagnosis of MC is established histologically, based on the presence of intraepithelial lymphocytosis and a mixed inflammatory infiltrate in the lamina propria (7). Many cases of MC are self-limiting and silent, whereas others are symptomatic for years in a relapsing or continuous pattern. Symptoms of MC are often attributed to IBS, so histologic investigations should be performed for the above-mentioned IBS patients.

This trial was designed to investigate the presence and incidence of MC and to reveal associated factors related to MC, prospectively in patients diagnosed with IBS by Rome III criteria.

## 2. Materials and methods

### 2.1. Selection of patients and the control group

After giving informed consent, 91 consecutive patients were included in group I. These were patients presenting to the Gastroenterology Department complaining of abdominal pain, dyspepsia, distension, and changes in defecation habit who were diagnosed with IBS by Rome III Criteria and for whom a colonoscopic examination was requested. None of the patients had a systemic illness or were using any medications.

The control group for microscopic colitis (group II) consisted of 41 patients considered as eligible for colonoscopic investigation due to specific complaints despite meeting Rome III criteria. In these patients, colonoscopic examination was recommended for screening purposes due to a familial history of colon cancer. Informed consent was obtained from all patients before beginning the colonoscopic examination.

### 2.2. Endoscopic examination

For all study subjects, a total colonoscopic examination was performed using a Pentax EC 3840 endoscope following appropriate colon cleansing, and 2 biopsies were obtained from each of the cecum, ascending, transverse, descending, and rectosigmoid colon segments for histopathological investigation.

### 2.3. Pathological examination

Tissue samples obtained during colonoscopic investigation were delivered to the pathology department in solutions containing formaldehyde. After the preparation of 5- $\mu$ m-thick paraffin blocks, the colon biopsies were dyed with hematoxylin-eosin (H-E) and Gömöri trichrome stains. All biopsy specimens were reviewed by an expert gastrointestinal pathologist who was not aware of the patients' groups.

### 2.4. Criteria for microscopic colitis

Collagenous colitis (CC) and lymphocytic colitis (LC) are 2 subtypes of MC. LC is defined by the flattening of the surface epithelium, degenerative cuboidal changes,

significant intraepithelial lymphocyte infiltration (more than 20 lymphocytes for every 100 epithelial cells), and mononuclear cell infiltration in the lamina propria. CC was defined by subepithelial collagenous bands  $>10 \mu$ m in thickness that were dyed with trichrome and H-E stains (8).

### 2.5. Statistical analysis

Data from this trial were assessed using SPSS 17.0. A Student's t test and analysis of variance were used for two-group and three-group comparisons respectively. A chi-square test was used for dependence tests of the categorical data. The level of significance was 0.05, with  $P < 0.05$  considered significant and  $P > 0.05$  considered not significant.

### 2.6. Ethical considerations

This study was approved by the Gazi University Local Medical-Surgical Research and Drug Ethical Committee.

## 3. Results

The age and sex distribution of the patients are similar between the two groups ( $P > 0.05$ , Table 1). Group I had 91 consecutive patients with IBS between 16 and 72 years of age. The mean age was  $42.71 \pm 1.43$ , with 63 females and 28 males. Cases in the MC control group (group II) included 22 females and 19 males with an age range of 18–79 and a mean age of  $47.24 \pm 2.33$ .

The patients with IBS were subdivided according to Rome III criteria into three groups: 22 (24.17%) were constipation-predominant, 55 (60.43%) were diarrhea-predominant, and 14 (15.38%) were mixed diarrhea and constipation. Symptom duration was found to be significantly shorter in the diarrhea-predominant IBS patients compared to the constipation-predominant and mixed type patients ( $P = 0.0001$ ,  $P = 0.005$ , and  $P < 0.05$ , respectively)

In the diarrhea-predominant IBS group, nine patients (9.89%) were histopathologically found to have MC; seven were found to have LC (7.69%), and two had CC (2.19%). None of the patients in group II were diagnosed with MC ( $P = 0.007$ ). No MC was diagnosed in the constipation-predominant and mixed type IBS group.

**Table 1.** Age and sex distribution of the patients with IBS and the control group.

	IBS (group I) n = 91	Control (group II) n = 41	
Age (years) mean $\pm$ sd	$42.71 \pm 1.43$	$47.24 \pm 2.33$	$P > 0.05$
Sex (M/F)	28/63	19/22	$P > 0.05$

The distribution of the seven cases with LC revealed two in the rectosigmoid, two in the descending colon and rectosigmoid, one in the cecum and ascending colon, one in the ascending, transverse, descending and rectosigmoid colon, and one with whole colon involvement. The rectum was spared in one case.

In the two patients with CC, descending colon involvement was observed in one case, and rectosigmoid colon involvement was observed in the other.

An evaluation of the nine patients with MC based on demographic and clinical characteristics revealed that six of the LC patients were female and one was male, with a mean age of  $44.6 \pm 1.7$ ; furthermore, one of the CC cases was male while one was female, with a mean age of  $57 \pm 3.0$ . Their mean symptom duration was  $44.6 \pm 1.7$  months. All of these patients had been diagnosed with diarrhea-predominant IBS. Their mean symptom duration was  $36.6 \pm 4.1$  months (Table 2).

#### 4. Discussion

In this study we found that some patients presenting with IBS symptoms can be diagnosed with MC. MC shows a clinical similarity to IBS. LC and/or CC may be related to constipation, although chronic diarrhea is the main symptom in patients with both MC and diarrhea-predominant IBS. In the literature, some studies reported that many patients suffered not from episodes of watery diarrhea but chronic constipation (5). In a trial assessing symptomatic similarities between IBS and MC, diarrhea-predominant IBS was reported in 28% of the MC cases as per the Rome II criteria (8). The present trial shows that all patients with MC were included in the diarrhea-predominant IBS patient group (Figure).

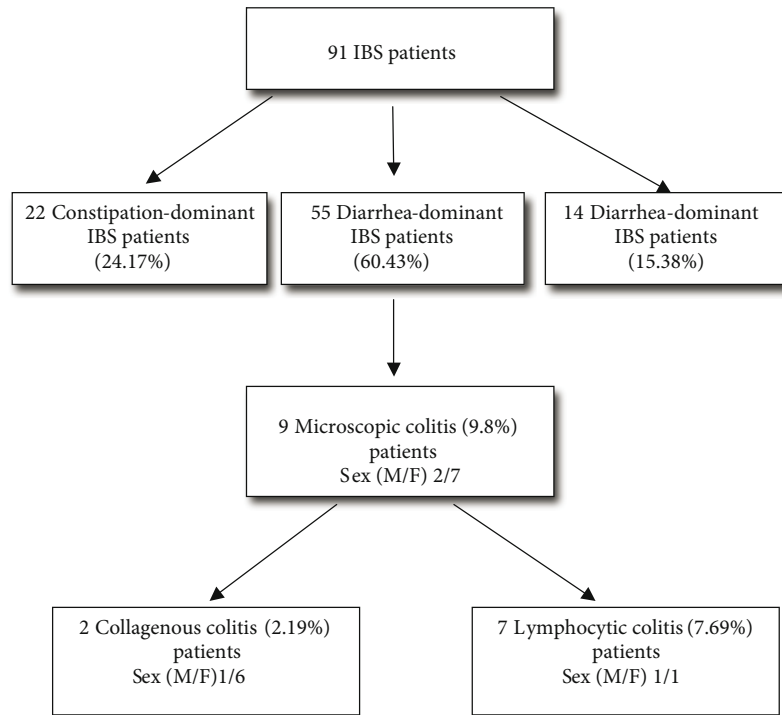
In a previous study, it was reported that alternative diagnoses should be investigated for IBS patients who

lack response to treatment and are followed up over an extended period (9). In our study, in all cases where MC was detected, the symptoms were found to last for a minimum of 6 months to a maximum of 144 months. This indicates that some of our patients were under monitoring with a misdiagnosis of IBS for over 10 years. In female diarrhea-predominant IBS patients with symptoms persisting over an extended period, the potential presence of MC should be kept in mind. There have been a few trials in the literature that investigated the coexistence of MC and IBS. In a recent trial, colon biopsy samples and clinical data of 131 patients diagnosed with MC (84 LC and 47 CC) and 110 patients without an MC diagnosis from whom a biopsy was obtained due to chronic diarrhea were evaluated retrospectively (10). In that study, the presence of symptoms required for IBS diagnosis by Rome II was demonstrated in 56% of the histologically diagnosed MC cases. Retrospectively, 43 of these patients (33%) were found to have been monitored with a diagnosis of IBS prior to biopsy. In the patient group consisting of 110 diarrhea patients without MC, a rate of 34% was detected for IBS diagnostic criteria. Intergroup comparison showed a statistically significant higher IBS diagnosis in the MC group compared to the others.

A prospective trial by Chadwick et al. evaluated colonoscopic biopsies of 77 patients diagnosed with IBS as per the Rome I criteria and established a histologic diagnosis of MC in 10% (11). In another trial, seven of 30 patients (23.3%) were diagnosed with IBS according to the Manning criteria and one patient out of 20 in the control group (5%) was found to have LC; the difference was statistically significant. None of the patients were found to have CC (12). A Turkish study reported the prevalence of microscopic colitis in 30 patients diagnosed with IBS by the Manning criteria to be 23% compared with 5% in

**Table 2.** Demographic and clinical characteristics of the patients diagnosed with MC.

Patient no.	Sex	Age	Symptom	Symptom duration (months)	Histology
5	F	41	Diarrhea	96	LC
10	F	44	Diarrhea	12	LC
24	M	50	Diarrhea	60	LC
25	F	60	Diarrhea	8	CC
29	F	40	Diarrhea	108	LC
34	M	54	Diarrhea	24	CC
52	F	52	Diarrhea	26	LC
69	M	41	Diarrhea	36	LC
80	M	44	Diarrhea	42	LC



**Figure.** The number of IBS patients and distribution of MC patients in the diarrhea-predominant IBS group.

a control group of 20 patients to be screened for colon cancer or nonulcer dyspepsia (12).

In our study, investigation of biopsy samples obtained by total colonoscopy from patients diagnosed with IBS using the Rome III criteria revealed MC in nine patients (9.89%) with seven found to have LC (7.69%) and two CC (2.19%). None of the patients in the control group had MC. In our study, all of the patients with MC were in the diarrhea-predominant IBS group.

To rule out MC in patients diagnosed with diarrhea-predominant IBS, a histopathological assessment of colonoscopic biopsies is required. Some trials recommend only rectal biopsy (13,14) while some report that rectal biopsy alone is insufficient due to the variable anatomic distribution of MC cases (15,16) and the higher level of proximal colon involvement compared to distal involvement (17). In our series, assessment of the seven cases with LC by colon segment revealed cecum involvement in one case, a combination of cecum, transverse colon, descending colon, and rectosigmoid colon involvement in two cases, a combination of descending colon and rectosigmoid colon involvement

in two cases, and rectosigmoid colon involvement in two cases. In the two patients with CC, descending colon and rectosigmoid colon involvement was observed in one, and rectosigmoid colon involvement was observed in the other. Based on the literature data and the results from our trial, we think that right colon biopsies are necessary for diagnosis in diarrhea-predominant IBS patients with a negative rectal biopsy in the event of suspicion of MC.

In conclusion, among patients diagnosed with IBS, those with symptoms persisting for a long period, those with diarrhea-predominant IBS and a short duration of symptoms, or those with a poor response to treatment, the actual diagnosis may be MC with symptoms overlapping with IBS. As is also indicated in the literature and by our trial, we conclude that histological investigations should be performed in the above-mentioned IBS patients by obtaining biopsies from the whole colon, as biopsies obtained only from the rectosigmoid are not adequate for the diagnosis of MC. This is important to avoid unnecessary, excessive, and long-term drug use by patients as well as to prevent losses in workforce efficiency and to reduce morbidity.

## References

1. Soares NC, Ford AC. Diagnosis and treatment of irritable bowel syndrome. *Discov Med* 2011; 11: 425–433.
2. Whitehead WE, Drossman DA. Validation of symptom-based diagnostic criteria for irritable bowel syndrome: a critical review. *Am J Gastroenterol* 2010; 105: 814–820.
3. Hulisz D. The burden of illness of irritable bowel syndrome: current challenges and hope for the future. *J Manag Care Pharm* 2004; 10: 299–309.
4. Brown WR, Tayal S. Microscopic colitis: a review. *J Dig Dis* 2013; 14: 277–281.
5. Barta Z, Mekkel G, Csípo I, Tóth L, Szakáll S, Szabó GG, Bakó G, Szegedi G, Zeher M. Microscopic colitis: a retrospective study of clinical presentation in 53 patients. *World J Gastroenterol* 2005; 11: 1351–1355.
6. Ianiro G, Cammarota G, Valerio L, Annicchiarico BE, Milani A, Siciliano M, Gasbarrini A. Microscopic colitis. *World J Gastroenterol* 2012; 18: 6206–6215.
7. Aust DE. Histopathology of microscopic colitis. *Pathologe* 2012; 3: S221–S224 (article in German).
8. Madisch A, Bethke B, Stolte M, Miehlke S. Is there an association of microscopic colitis and irritable bowel syndrome – a subgroup analysis of placebo-controlled trials. *World J Gastroenterol* 2005; 11: 6409.
9. El-Salhy M. Irritable bowel syndrome: diagnosis and pathogenesis. *World J Gastroenterol*. 2012; 18: 5151–5163.
10. Limsui D, Pardi DS, Camilleri M, Loftus EV Jr, Kammer PP, Tremaine WJ, Sandborn WJ. Symptomatic overlap between irritable bowel syndrome and microscopic colitis. *Inflamm Bowel Dis*. 2007; 13: 175–181.
11. Chadwick VS, Chen W, Shu D, Paulus B, Bethwaite P, Tie A, Wilson I. Activation of the mucosal immune system in irritable bowel syndrome. *Gastroenterology* 2002; 122: 1778–1783.
12. Tuncer C, Cindoruk M, Dursun A, Karakan T. Prevalence of microscopic colitis in patients with symptoms suggesting irritable bowel syndrome. *Acta Gastroenterol Belg*. 2003; 66: 133–136.
13. MacIntosh DG, Thompson WG, Patel DG, Barr R, Guindi M. Is rectal biopsy necessary in irritable bowel syndrome? *Am J Gastroenterol* 1992; 87: 1407–1409.
14. Robinson RJ, Stone M, Mayberry JF. Normal rectal mucosa. Should we biopsy? *Hepatogastroenterology* 1997; 44: 703–705.
15. Carpenter HA, Tremaine WJ, Batts KP, Czaja AJ. Sequential histologic evaluations in collagenous colitis: correlations with disease behavior and sampling strategy. *Dig Dis Sci* 1992; 37: 1903–1909.
16. Goff JS, Barnett JL, Pelke T, Appelman HD. Collagenous colitis: histopathology and clinical course. *Am J Gastroenterol* 1997; 92: 57–60.
17. Offner FA, Jao RV, Lewin KJ, Havelec L, Weinstein WM. Collagenous colitis: a study of the distribution of morphological abnormalities and their histological detection. *Hum Pathol* 1999; 30: 451–457.