

1-1-2005

Fundoscopic Normal Variations of the Retina in Turkish Sheepdogs and Multifocal Retinal Dysplasia: A Comparative Study in Akbash and Kangal Breeds

MURAT SAROĞLU

YALÇIN DEVECİOĞLU

KEMAL ALTUNATMAZ

Follow this and additional works at: <https://journals.tubitak.gov.tr/veterinary>



Part of the [Animal Sciences Commons](#), and the [Veterinary Medicine Commons](#)

Recommended Citation

SAROĞLU, MURAT; DEVECİOĞLU, YALÇIN; and ALTUNATMAZ, KEMAL (2005) "Fundoscopic Normal Variations of the Retina in Turkish Sheepdogs and Multifocal Retinal Dysplasia: A Comparative Study in Akbash and Kangal Breeds," *Turkish Journal of Veterinary & Animal Sciences*: Vol. 29: No. 2, Article 54. Available at: <https://journals.tubitak.gov.tr/veterinary/vol29/iss2/54>

This Article is brought to you for free and open access by TÜBİTAK Academic Journals. It has been accepted for inclusion in Turkish Journal of Veterinary & Animal Sciences by an authorized editor of TÜBİTAK Academic Journals. For more information, please contact academic.publications@tubitak.gov.tr.

Fundoscopic Normal Variations of the Retina in Turkish Sheepdogs and Multifocal Retinal Dysplasia: A Comparative Study in Akbash and Kangal Breeds

Murat SAROĞLU, Yalçın DEVECİOĞLU, Kemal ALTUNATMAZ
Department of Surgery, Faculty of Veterinary Medicine, İstanbul University, Avcılar, İstanbul - TURKEY

Received: 18.02.2004

Abstract: In this study, normal fundoscopic variations and genetic retinal diseases of Turkish sheepdogs (Akbash and Kangal) have been assessed. According to comparative results obtained from 35 Akbash and 35 Kangal dogs, it was determined that blue tapetal regions were present at a rate of 65% in the Akbash breed and yellow-green tapetal regions were present at a rate of 60% in the Kangal breed. No fundoscopic or clinical sign suggesting albunism, subalbunism or progressive retinal atrophy was observed in either group. However, multifocal retina dysplasia was seen at a rate of 17.1% in the Akbash breed and 5.4% in the Kangal breed. The fact that all of these lesions, which presented typical fundoscopic appearance, were seen in females was interpreted as coincidental. It was of particular interest that these retinal dysplasias, which did not disrupt sight, occurred 3 times more in the Akbash breed compared to the Kangal breed.

Key Words: Akbash, Kangal, Turkish Sheepdogs, multifocal retinal dysplasia, fundus

Türk Çoban Köpeklerinde Retinanın Fundoskopik Normal Varyasyonları ve Multifokal Retinal Displazi: Akbaş ve Kangal Irklarında Karşılaştırmalı Çalışma

Özet: Bu çalışmada Türk çoban köpeklerinin (Akbaş ve Kangal) normal fundoskopik varyasyonları ve genetik retinal hastalıkları değerlendirildi. Otuzbeş Akbaş ve 35 Kangalda karşılaştırmalı olarak elde edilen sonuçlara göre, Akbaşlarda % 65 oranında mavi renkli, Kangallarda % 60 oranında sarı-yeşil renkli tapetal bölgelerin bulunduğu saptandı. Her iki grupta da albunizm, subalbunizm ve progresif retinal atrofiyi düşündürecek fundoskopik ve klinik belirtilere rastlanmadı. Ancak Akbaşlarda % 17,1, Kangallarda % 5,4 oranında multifokal retina displazisi gözlemlendi. Tipik fundoskopik görünümünde olan bu lezyonların tamamının dişi köpeklerde bulunması rastlantı olarak yorumlandı. Herhangi bir görüş kusuruna yol açmayan bu primer retina displazilerinin, Akbaşlarda Kangallara göre 3 kat fazla olması dikkate değer bulundu.

Anahtar Sözcükler: Akbaş, Kangal, Türk çoban köpeği, multifokal retinal displazi, fundus

Introduction

While fundoscopic appearances among different breed dogs may present distinct changes, minor variations considered to be normal within breeds can also be seen. Dogs with different iris and coat colour may have marked changes in the appearance of their fundus. However, a definite relationship between iris and coat colour and tapetal fundus colour can not be suggested. Knowledge of the variations in normal fundus structure is important to determine the possible pathological changes (1-3).

Primary retinal dysplasias are congenital development abnormalities of the retina (2-8) and can be seen in many breeds. Hereditary factors have been reported in breeds such as Bedlington Terrier (9), Sealyham Terrier (10),

Yorkshire Terrier (11), Rottweiler (4), English Springer Spaniel (12), American Cocker Spaniel (7) and Labrador Retriever (13,14).

Retinal dysplasias are examined in 3 different clinical forms (2,3). In focal or multifocal retinal dysplasias, retinal fold and rosettes present themselves with decreased tapetal reflectability. Grey-green spots or linear rods (when 2-3 rods are side-by-side they appear as V or Y) are noticed. It may be present anywhere in the tapetal region. However, it is more frequently seen in the central retina, region of the dorsal retinal blood vessels and origin of the optic nerve (1-4,7,8). Retinal folds in the non-tapetal regions are observed as grey-white, linear or irregular rods (1-4,7). Multifocal retinal dysplasia has

been reported in American Cocker Spaniels (7), English Springer Spaniels (12), Beagles (15), Rottweilers (4) and Labrador Retrievers (14).

In geographic retinal dysplasias, irregular and horseshoe-shaped areas can be seen in the central tapetal fundus. Partial retinal thinning and retinal displacement is present in these areas (2,3). Geographic retinal dysplasia is observed in English Springer Spaniels, Cavalier King Charles Spaniels and Golden Retrievers (12).

In total retinal dysplasias, which occur together with displacement of the retina, the neuroretina usually separates from the optic disc and floats freely in the vitreous (1-3,8). This form can also be described as vitreoretinal dysplasia. In this kind of dysplasia, vitreal haemorrhage, cataract and secondary glaucoma may develop (1-5). These are observed in English Springer Spaniels, Bedlington, Sealyham and Yorkshire Terriers (5,10,12).

In breeds such as the Australian Shepherd Dog (16,17), Chow Chow (18), Dobermann Pinscher (19-21) and Akita (6), retinal dysplasias have been observed together with other severe ocular defects (such as microphthalmia and congenital cataract). There are also cases seen occurring together with skeletal chondrodysplasia in Labrador Retrievers (22) and Samoyeds (23).

Generally, multifocal retinal dysplasia does not affect eyesight and it may not even be noticed until routine fundus examination. In some cases, the lesion recedes with time and the folds become invisible. The other two forms of retinal dysplasia cause severe loss of sight and blindness (2-6).

When their growth characteristics and physical properties are compared, Akbash and Kangal dogs are regarded as two different breeds (24). No report has been found about retinal diseases of these two breeds, which have been used as sheepdogs and watchdogs for centuries.

This study has been planned in order to examine normal retinal variations of Akbash and Kangal dogs, compare the fundoscopic findings and assess possible retinal diseases.

Materials and Methods

The material of our study consisted of 140 eyes in 70 Turkish Sheepdogs. Of the 70 dogs, 35 were Akbashes

and 35 were Kangals. Akbash dogs were distributed as 24 females and 11 males, while Kangal dogs were distributed as 20 females and 15 males. Ages ranged between 5 months and 10 years among Akbash dogs and 4 months and 13 years among Kangal dogs. Of the dogs in the study group, 28 Akbashes and 22 Kangals belonged to the Karacabey Stud Farm, Dog Breeding Unit. The remaining 7 Akbashes and 13 Kangals were routine cases brought to Istanbul University, Veterinary Faculty, Surgery Department.

Firstly, routine eyesight tests were carried out on the dogs included in the study, after which a midriatic, tropicamide (Tropamid[®], Bilim, Istanbul, Turkey) was applied to each eye before ophthalmoscopic examination. Following retinal examination with direct and indirect ophthalmoscope, images were obtained of all cases using the fundus camera (Kowa[®], RC 2 model, Japan).

Using these findings, normal retina variations of Kangal and Akbash breed Turkish Sheepdogs were comparatively examined and genetic retinal diseases were assessed.

Results

The findings showed that the tapetal region was of different shades of blue in 22 of the 35 Akbash dogs and that it darkened as it neared the non-tapetal region (Figure 1); however, that in the remaining 13 dogs the colour was blue around the optic disc and near the tapetal region and that towards the peripheral fundus the colour was yellow in a wider area (Figure 2). The proportion of Akbash dogs with blue tapetal region was 65%, while those with yellow-blue was 35%.

In 21 of the Kangal dogs, the fundus was yellow-green (Figure 3). The green colour was in the optic disc and in the area close to the non-tapetal region, whereas the yellow colour was over a wider area on the periphery. Blue tapetal region was observed in 9 Kangal dogs and as with Akbash dogs, the shade of the colour darkened close to the non-tapetal region border. The structure of the fundus, which was blue in areas near the non-tapetal region and yellow towards the periphery, was similar to Akbash dogs in 5 cases. In Kangal dogs, the proportion of those with yellow-green tapetal region was 60%, those with blue was 25% and those with yellow-blue was 15%.

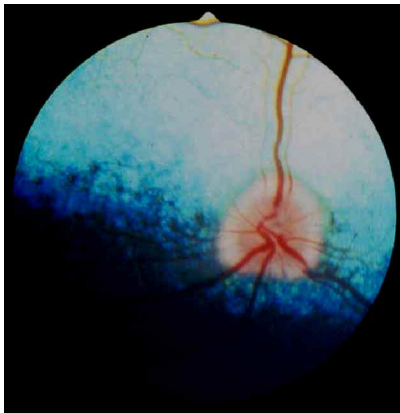


Figure 1. Blue type fundoscopic view in a two-year-old Akbash.

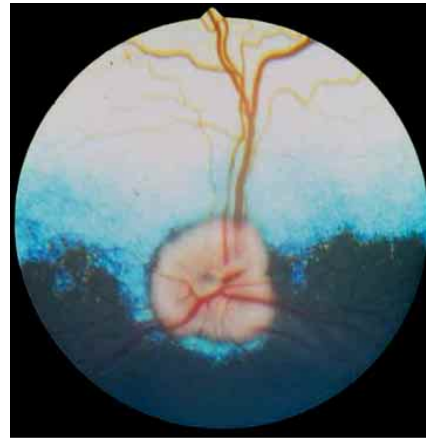


Figure 2. Blue-yellow type fundoscopic view in a three-year-old Akbash.

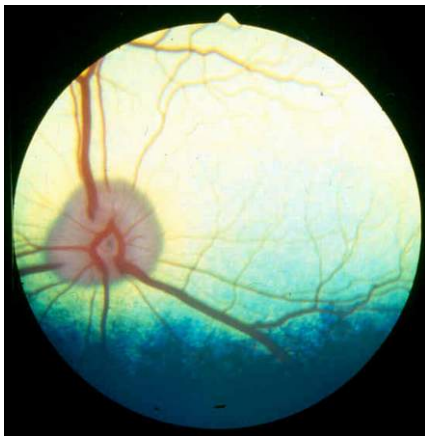

Figure 3. Yellow-green type fundoscopic view in a five-year-old Kangal.

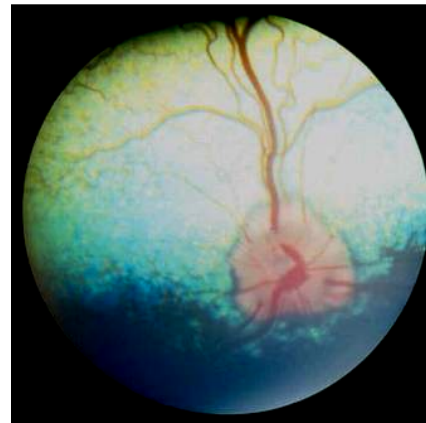


Figure 4. Multifocal retinal dysplasia in a six-year-old female Akbash.

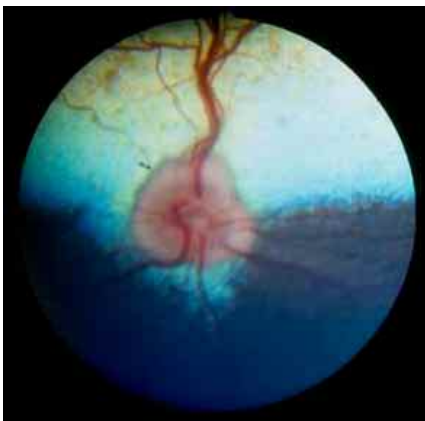


Figure 5. Yellow-green type fundoscopic view in a five-year-old Kangal.

The optic disc of dogs in both groups developed well. The physiological cavity in the centre could be observed and completed venous circulation was evident. In all of the cases, the optic nerve head was either in the tapetal region or on the border of the tapetal-non-tapetal region. The nerve head was not seen in the non-tapetal region in any of the cases. The structure of the retinal blood vessels could easily be seen in the tapetal region. There were no cases of albinism, subalbinism or heterochromie.

In the tapetal fundus of 6 cases in the Akbash group, multiple brown-grey spots were noticed (Figure 4). These were generally located in the central fundus, the proximal of the optic disc and around blood vessels. All of these dogs had yellow-blue tapetal regions and the lesions were observed in the yellow area forming a large part of the tapetal region.

In the Kangal group, distinct and multiple brown-grey spots were observed in the yellow-green tapetal region of 2 cases. As in Akbash dogs, these structures were located in the central fundus, the proximal of the optic disc, around the blood vessels and in the yellow area (Figure 5).

There was no tapetal hyperreflexia, vascular thinning or optic nerve head atrophy suggesting progressive retinal atrophy in either group. Night and day vision of all dogs was normal clinically.

Due to their fundoscopic appearances, retinal abnormalities in 6 cases in the Akbash group and 2 cases in the Kangal group were described as multifocal retinal dysplasia (MRD). All of the dysplastic Akbash dogs were female and aged between 2 and 6 years. Mean age was determined to be 5.1. MRD rate within the whole of the Akbash group was 17.1%. Both of the dysplastic Kangal dogs were female and aged 6 and 11 years. Their mean age was 8.5 years. MRD rate was found to be 5.4% within the Kangal group. No other ocular or skeletal development abnormality was observed in any of these cases.

Discussion

The appearance of the tapetal fundus can be yellow, orange, green or blue in dogs. Frequently, it is multi-coloured. The widespread combination is mainly yellow, gradually changing into green and eventually blue on the non-tapetal region border, as in Retrievers and Spaniels. A green fundus with a blue edge is generally seen in Doberman Pinschers and Miniature Schnauzers. There is no tapetal region in some breeds such as Blue Merle Collies or Shetland Sheepdogs. In all of the Turkish Sheepdogs, tapetal regions were seen to be present with colour combinations of blue, yellow-green and yellow-blue. A definite relationship is not present between breed and fundus colour. It is possible to speak of a close relationship between iris and coat colour and fundus colour. There can also be different colour distributions between animals of the same breed (2). However, the blue appearance of the fundus in 65% of Akbash dogs and the yellow-blue appearance in 60% of Kangal dogs were thought to be of interest.

Subalbino fundus can be observed in some dogs belonging to breeds such as Shetland Sheepdogs, harlequin-coloured Great Danes, Cardigan Welsh Corgis

and Siberian Huskies (2). In our study, no subalbino fundus was encountered in Turkish Sheepdogs.

Optic nerve heads were seen to be of normal dimension and shape (oval, round, triangle, polygonal). Their colour was pinkish-white or pink. In most of them, the physiological cavities were grey. Structure, diameter and distribution of retinal blood vessels were normal, as described in the literature (1,2).

Breeding of Turkish Sheepdogs as working dogs has been going on for centuries. Progressive retinal atrophy (PRA) is seen in many breeds across the world. So far no PRA cases have been reported in Kangal or Akbash dogs. During our study, we did not encounter any PRA cases either in Kangal or in Akbash dogs. We attribute this fact to the possibility of breeders using the selection method for centuries on these sheepdogs.

Primary retinal dysplasias are congenital development abnormalities of the retina (2-4,6,8) and occur in 3 different forms. Focal or multifocal retinal dysplasias are the mildest of these 3 forms. There is no sight destruction in this form. They are usually noticed during routine fundus examination (2,3). Primary retinal dysplasias, found in 17.1% of the Akbash dogs and 5.4% of the Kangal dogs in our study groups, were observed in dogs with no loss of sight. There were no previous complaints from the dog owners or breeders concerning sight deterioration. The fact that the multiple brown-grey spots noticed in the tapetal regions of these cases were generally localised in the central fundus, the proximal of the optic disc and around the blood vessels, are similar to previous reports (1-4,7). When retinal folds are in the non-tapetal region, they can be observed as grey-white, linear or irregular rods (1-4). However, no such condition was observed in any of the 8 cases with MRD in either group.

Multifocal retinal dysplasia has been reported in American Cocker Spaniels (7), English Springer Spaniels (12), Beagles (15), Rottweilers (4), and Labrador Retrievers (14). Our fundoscopic findings have revealed the presence of MRD in Akbash and Kangal dogs. The fact that the incidence of multifocal retinal dysplasia in Akbash dogs was 3 times higher than Kangal dogs was interesting.

Geographic form is seen in English Springer Spaniels, Cavalier King Charles Spaniels and Golden Retrievers, while complete retinal dysplasia developing with retinal

displacement is seen in Bedlingtons, English Springer Spaniels, Sealyhams and Yorkshire Terriers (2). These forms, which can have dramatic clinical results, were not observed in Akbash or Kangal dogs.

Retinal dysplasias have been reported to occur together with intraocular defects in breeds such as Akita (6), Australian Shepherd Dog (16,17), Chow Chow (18) and Dobermann Pinscher (19-21); and together with skeletal chondrodysplasia in Labrador Retrievers (22) and Samoyeds (23). While these disorders were not encountered in our study groups, neither was a report found on genetic retinal diseases in the two dog breeds constituting our study.

MacMillan and Lipton determined the incidence of multifocal retinal dysplasia in American Cocker Spaniels as approximately 19.1% uni- and bilaterally. They observed the dysplasia foci as 3 different types formed by 2-3 ovals, linear and linear structures arranging side-by-side to produce V-Y shapes (7). In our study, cases with MRD were only seen as oval and round structures. There were no unilateral cases.

Bedford determined MRD in 5 Rottweilers out of 34, which were undergoing routine fundoscopic examination. Fundoscopic appearances of cases with MRD were similar to the fundus appearance in American Cocker Spaniels (4).

There is no proven gender predisposition in multifocal retinal dysplasias (1-3). We interpret the fact that all of the dysplastic dogs in both groups in the findings of this study were female as a coincidence.

Hereditary factors have been reported for MRD seen in breeds such as Bedlington Terrier (9), Sealyham Terrier (10), Yorkshire Terrier (11), Rottweiler (4), English Springer Spaniel (12), American Cocker Spaniel (7) and Labrador Retriever (13,14). The fact that 3 of the 6 dysplastic cases in the Akbash group were siblings suggests that multifocal retinal dysplasias in Turkish Sheepdogs can be hereditary. However, to prove the presence of hereditary factors in Turkish Sheepdogs, pedigree registers need to be widely examined and studies should be carried out over long periods of time by comparing matings.

Acknowledgement

This work was supported by the Research Fund of Istanbul University (Project no. 1610/30042001). Authors are grateful to Prof. Roberto Koestlin for his assistance during the study, and would like to thank İsmail Karatas, Mustafa Avci and Seydi Vakkas Karaoğlan for their help in Karacabey Stud Farm.

References

1. Curtis, R., Lightfoot, R.M.: Condition of the Fundus. In: Peterson-Jones, S.M., Crispin, S.M., Eds. *Manual of Small Animal Ophthalmology*. B.S.A.V.A. Publication, West Sussex, 1993; 237-258.
2. Narfström, K., Ekesten, B.: Diseases of the canine ocular fundus. In: Gelatt, K.G., Ed. *Veterinary Ophthalmology*, 3rd ed., Williams and Wilkins, Baltimore, 1999; 869-932.
3. Slatter, D.: Retina. Chapter 16. In: *Fundamentals of Veterinary Ophthalmology*. 3rd ed., W.B. Saunders Co., Philadelphia. 2001; 419-456.
4. Bedford, P.G.C.: Multifocal retinal dysplasia in the Rottweiler. *Vet. Rec.*, 1982; 111: 304-305.
5. Kaya, M.: Diseases of the retina in dogs and cats. *J. Turk. Vet. Surg. Assoc.*, 2000; 6: 89-94.
6. Laratta, L.J., Riis, R.C., Kern, T.J., Koch, S.A.: Multiple congenital ocular defects in Akita Dog. *Cornell Vet.*, 1985; 75: 381-392.
7. MacMillan, A.D., Lipton, D.E.: Heritability of multifocal retinal dysplasia in American Cocker Spaniels. *J. Am. Vet. Med. Assoc.*, 1978; 172: 568-572.
8. Narfström, K., Bjerkas, E., Ekesten, B.: Visual impairment In: Peiffer, R.L., Peterson-Jones, S.M., Eds. *Small Animal Ophthalmology- A Problem-Oriented Approach*. 2nd ed., Saunders Co., Philadelphia. 1997; 85-165.
9. Rubin, L.F.: Hereditary retinal detachment in Bedlington Terriers. *Small Anim. Clin.*, 1963; 3: 387-389.
10. Ashton, N., Barnett, K.C., Sachs, D.D.: Retinal dysplasia in Sealyham Terrier. *J. Pathol. Bacteriol.*, 1968; 96: 269-272.
11. Stades, F.C.: Hereditary retinal dysplasia (RD) in a family of Yorkshire Terriers. *Tijdschr. Diergeneesk.*, 1978; 103: 1087-1090.
12. Schimidt, G.M., Ellersieck, M.R., Wheeler, C.A., Blanchard, G.L., Keller, W.F.: Inheritance of retinal dysplasia in the English Springer Spaniel. *J. Am. Vet. Med. Assoc.*, 1979; 174: 1989-1990.

13. Barned, K.C., Björck, G.R., Kock, E.: Hereditary retinal dysplasia in the Labrador Retriever in England and Sweden. *J. Small Anim. Pract.*, 1970; 10: 755-759.
14. Nelson, D.L., Macmillian, A.D.: Multifocal retinal dysplasia in field trial Labrador Retrievers. *J. Am. Vet. Med. Assoc.*, 1983; 19: 388-392.
15. Heywood, R., Wells, G.A.H.: Retinal dysplasia in the Beagle dog. *Vet. Rec.*, 1970; 87: 178-180.
16. Gelatt, K.N., Veith, L.A.: Hereditary multiple ocular anomalies in Australian Shepherd Dogs. *Vet. Med.*, 1970; 65: 39-42.
17. Gelatt, K.N., McGill, L.D.: Clinical characteristics of microphthalmia with colobomas of the Australian Shepherd dog. *J. Am. Vet. Med. Assoc.*, 1973; 162: 393-396.
18. Collins, B.K., Collier, L.L., Johnson, G.S., Shibuya, H., Moore, C.P., Curiel, S.: Familial cataracts and concurrent ocular anomalies in Chow Chows. *J. Am. Vet. Med. Assoc.*, 1992; 200: 1485-1491.
19. Bergsjö, T., Arensen, K., Heim, P., New, N.: Congenital blindness with ocular developmental anomalies, including retinal dysplasia, in Doberman Pinscher dogs. *J. Am. Vet. Med. Assoc.*, 1984; 184: 1383-1386.
20. Lewis, D.G., Kelly, D.F., Sansom, J.: Congenital microphthalmia and other developmental ocular anomalies in the Doberman. *J. Small Anim. Pract.*, 1986; 27: 559-566.
21. Peiffer, R.L., Fisher, C.A.: Microphthalmia, retinal dysplasia, and anterior segment dysgenesis in a litter of Doberman Pinschers. *J. Am. Vet. Med. Assoc.*, 1983; 183: 875-878.
22. Carrig, C.B., MacMillan, A., Brundage, S., Pool, R.R., Morgan, J.P.: Retinal dysplasia associated with skeletal abnormalities in Labrador Retrievers. *J. Am. Vet. Med. Assoc.*, 1977; 170: 49-57.
23. Meyers, V.N., Jezyk, P.F., Aguirre, G.D., Patterson, D.F.: Short-limbed dwarfism and ocular defects in the Samoyed dog. *J. Am. Vet. Med. Assoc.*, 1983; 183: 975-979.
24. Tepeli, C., Çetin, O.: Growth Characteristics of Kangal and Akbash Turkish Shepherd Dogs. 2nd National Small Animal Veterinary Medicine Congress. Bursa-Turkey. 2003; 101.