

1-1-2005

A Retrospective Study: Evaluation of Patellar Luxation Cases in Cats

OKTAY DÜZGÜN

Follow this and additional works at: <https://journals.tubitak.gov.tr/veterinary>



Part of the [Animal Sciences Commons](#), and the [Veterinary Medicine Commons](#)

Recommended Citation

DÜZGÜN, OKTAY (2005) "A Retrospective Study: Evaluation of Patellar Luxation Cases in Cats," *Turkish Journal of Veterinary & Animal Sciences*: Vol. 29: No. 2, Article 14. Available at: <https://journals.tubitak.gov.tr/veterinary/vol29/iss2/14>

This Article is brought to you for free and open access by TÜBİTAK Academic Journals. It has been accepted for inclusion in Turkish Journal of Veterinary & Animal Sciences by an authorized editor of TÜBİTAK Academic Journals. For more information, please contact academic.publications@tubitak.gov.tr.

A Retrospective Study: Evaluation of Patellar Luxation Cases in Cats

Oktay DÜZGÜN

Department of Surgery, Faculty of Veterinary Medicine, İstanbul University, Avcılar 34840, İstanbul - TURKEY

Received: 13.03.2003

Abstract: Patellar luxation is an orthopedic disorder seen rarely in cats. In this study, patellar luxation was encountered in 8 of 7744 cats brought to the Department of Surgery of Faculty of Veterinary Medicine of İstanbul University between the years of 1995-2001. The rate of patellar luxation was 0.10% of feline cases. The patellar luxation incidence in 5145 orthopedic lesions in cats was 0.15%. Clinical symptoms such as difficulty in walking, running with a hop and abnormal stance in the hindlimb were seen in patients diagnosed using skyline radiography technique. The aim of the present study was the clinical diagnosis and early treatment of this low incidence disease of cats. Treatment procedures have been determined in these early-diagnosed cases according to the degree of the disease. Two of these cases were treated conservatively and 6 operatively. It was concluded that capsuloraphy combined with sulcoplasty increased the success rate.

Key Words: Cat, patellar luxation

Bir Retrospektif Çalışma: Kedilerde Patella Luksasyonu Olgularının Değerlendirilmesi

Özet: Patella Luksasyonu kedilerde oldukça ender rastlanılan bir ortopedik bozukluktur. Bu çalışmada 1995-2001 yılları arasında İstanbul Üniversitesi Veteriner Fakültesi Cerrahi Anabilim Dalı kliniğine getirilen toplam 7744 kediden 8'inde patella luksasyonuna rastlanıldı. Bu patella luksasyonuna oranı kedilerde % 0,10 gibi oldukça düşük bir değer olarak saptandı. Aynı süreçte 5145 kedide rastlanan ortopedik lezyon arasındaki patella luksasyonu insidansı % 0,15 olarak belirlendi. Yürürken zorlanma zıplayarak koşma ve arka ayaklarda anormal basış pozisyonu gibi klinik semptomlar gösteren hastalarda tanıya ulaşmak için skyline radyografi görüntüleme tekniği de kullanıldı. Bu çalışmanın amacı, kedilerde insidansı çok düşük olan hastalığın klinik muayenede teşhisi ve erken sağıltımıdır. Erken dönemde teşhis edilen olguların tedavilerinde hastalık derecesine göre sağıltım yöntemi belirlendi. Bu olguların 2'si konservatif 6'sı operatif olarak sağıltıldı. Sulkoplasti ile birlikte kapsulorafi uygulamasının, başarı şansını arttırdığı sonucuna varıldı.

Anahtar Sözcükler: Kedi, patella luksasyonu

Introduction

Patellar luxation is an intermittent or permanent fixing of the patella by changing the position towards the lateral, medial or upper portion of the femoral trochlea. This disorder is most commonly seen in horses, cattle, oxen and dogs (1-3) and rarely in cats (4-8).

Patellar luxation may be either congenital or acquired. Congenital patellar luxation may happen due to various congenital malformations of coxa-vara, coxa-valga, genu-vara, lateral torsion or bending of the distal third of the femur, medial dislocation of the quadriceps muscle group, dysplasia of the femoral epiphysis, rotational instability of the stifle joint, medial rotation of the tibia, medial dislocation of the tibial tuberosity, shallowness of the femoral trochlea, false trochlea formation on the medial

condyle of the femur and DJD (2,5,8-13). On the other hand, acquired patellar luxations are caused by indirect or direct trauma (1,2). Indirectly, it is caused by sudden inward rotation of the tibia while the stifle joint is extended (jumping or falling from a height). Direct trauma occurs by following fractures of the joint or areas close to the joint (2). In one study, Davis and Gill (4) encountered patellar luxation of cats in only 6 cases over a period of 11 years. Patellar luxation may occur in Devon-Rex, British Shorthaired and Siamese cats (4,5,7,14). While Fleknel (6) determined congenital patellar luxation in 29 (90.6%) of the 32 Devon-Rex cats, they observed patellar luxation in only 10 (10.3%) of the 97 cats belonging to other breeds. Davis and Gill (4) have stressed that the possibility of congenital patellar luxation formation by as a result of mating with British

Shorthaired cats is reasonably low. Houlton and Meynink (15) have reported that patellar luxation in cats usually originate from trauma. Patellar luxations in cats mostly occur medialis and may be either unilateral or bilateral (4,6,7,15,16). Lameness may not occur. Abnormal hindlimb stances, kneeling stance and lack of confidence can be observed (4,6). It has also been stressed that the stifle joint may become locked in some cats when walking (17). Definitive diagnosis is based upon radiographic evaluation. The patella can be seen in position to move away from its normal location within the trochlear groove in antero-posterior and medio-lateral radiographs. The diagnosis is confirmed by the use of skyline imaging technique (Figure 1), which is specific for patellar luxations, taken with the joint in full flexion (18). Avascular necrosis of the femoral head, coxo-femoral luxation and joint distortions must be eliminated in differential diagnosis (8,9,11). Prognosis is good for stationary dislocations. In habitual dislocations, reoccurrence may occur in the post-operative period (1).

Narrowing of the joint capsule (capsuloraphy), sulcoplasty in young animals (trochleoplasty), fixation from the fabella to the patellar ligament (patelloplasty), wedge osteotomy in adult small animals (wedge resection), transposition of the tibial tuberosity is used individually or in combination (2,3,5,8-11,13,17,19). The best surgical technique in cats is either sulcoplasty or tibial tuberosity transpositions or the combination of these (19). Ruptures of the cranial cruciate ligament and degenerative changes on joint surface of femoral condyles

of tibia may occur in animals that have not undergone surgery (2,8,10,15,17). The aim of the present study was to discuss the patella luxation in cats over 7 years and to reflect on it.

Materials and Methods

Eight cats with a complaint of inability to use their hindlimb or difficulty in walking were brought to the University of Istanbul Veterinary Medicine Department of Surgery between the years of 1995-2001. Clinical and radiological examinations confirmed patellar luxation. Of the cases, 2 were treated conservatively and 6 operatively. The first of the two cases treated conservatively (case no. 5) had congenital and permanent bilateral luxation with lateral torsion and bending of the distal third of the femur together with medial rotation of the tibia. The patella in the second case treated conservatively (case no. 6) had intermittent and bilateral luxation along with subluxation of the coxo-femoral joint. Analgesic and non-steroid anti-inflammatory drug carprofen (Rimadyl® 20 mg Tb) was administered orally at a dose of 2 mg/kg in conservatively treated cats. Six cases were treated surgically. While capsuloraphy was performed in only one case (case no. 1), sulcoplasty together with capsuloraphy was carried out in the remaining five cases (cases no. 2, 3, 4, 7 and 8). Following fixation, a bandage was not used during the postoperative period but the owners were advised to restrict the animal's movements.

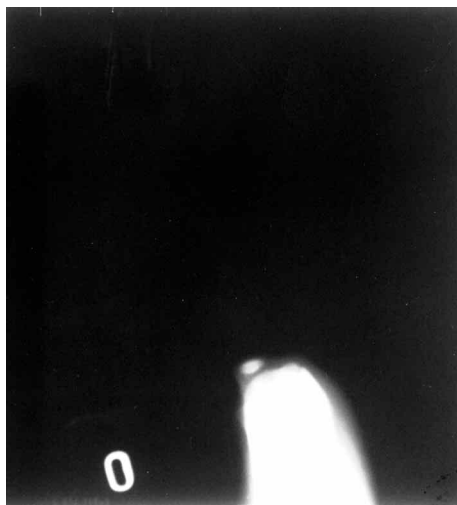


Figure 1. Skyline imaging technique

Results

Patellar luxation was diagnosed in only 8 cats out of 7744 with various complaints brought to the University of Istanbul, Veterinary Medicine, and Department of Surgery after clinical and radiological examination between the years 1995-2001. (Table 1). The rate of patellar luxation in cats was 0.10%.

The rate of patellar luxation was 0.15% among the orthopedic disorders (5145) in cats. All the cats except one (case no. 6) were under the age of 2. Three cats were female and the rest of them were male. Complaints consisted of difficulty in walking (cases no. 5, 6, 7 and 8) or lameness (cases no. 1, 2, 3 and 4). Three of the patients (cases no. 1, 3 and 8) had left patellar luxation (LPL), two (cases no. 2 and 4) had right patellar luxation (RPL) and three (cases no. 5, 6 and 7) had bilateral

Table 1. Evaluation of patellar luxation in cats.

Case	Breed	Age (M)	Gender	History	Side	Grade	Diagnosis	Treatment	Follow-up
1	SHD	24	F	stretching left leg backwards from time to time	L	I	LPL (medial)	C	3 months later (+)
2	SHD	4	M	sudden lameness in right leg	R	P	RPL (medial) Congenital	S + C	4 months later (+)
3	SHD	7	M	lameness in left leg	L	P	LPL (medial) Congenital	S + C	6 months later (+)
4	LHD	7	M	stretching left leg backwards from time to time	R	I	RPL (medial)	S + C	3 months later (+)
5	LHD	7	F	difficulty in walking	R-L	P	BPL (medial) Congenital	Co	6 months later (-)
6	SHD	144	F	difficulty in walking	R-L	I	BPL + CFS (medial)	Co	3 months later (±)
7	LHD	8	M	difficulty in walking	R-L	P	B (PL + HD) (medial)	S + C	3 months later (+)
8	LHD	8	M	difficulty in walking	L	I	LPL (medial)	S + C	4 months later (+)

SHD: Short-haired domestic, LHD: Long-haired domestic, M: Month, I: Intermittent, P: Permanent, LPL: Left patella luxation, RPL: Right patella luxation, BPL: Bilateral patellar luxation, HD: Hip dysplasia, CFS: Coxa-femoral subluxation, C: Capsuloraphy, S: Sulcoplasty, Co: Conservative, PL: Patella luxation, (+): Clinically and radiologically no problems, (-): Euthanasia, (±): Radiologically bad, clinically no problem.

patellar luxation (BPL). One of the cases diagnosed with BPL (case no. 7) also had hip dysplasia (HD). [B(PL+HD)]. The other case (case no. 6) had coxo-femoral subluxation. Of the cases, 4 were intermittent and 4 permanent. Three cases (cases no. 2, 3 and 5) were decided to have occurred congenitally. In case no. 5, which was treated conservatively, bilateral locking of the stifle occurred 6 months later and euthanasia was carried out upon the owner's request (Figure 2). The other case (case no. 6) had periodical check-ups and following one year the owner reported that the cat did not have much difficulty

in walking. Complete recovery was achieved in all of the cats treated surgically (cases no. 1, 2, 3, 4, 7 and 8). There were no post-operative complications in any of the cases (Figures 3-7).

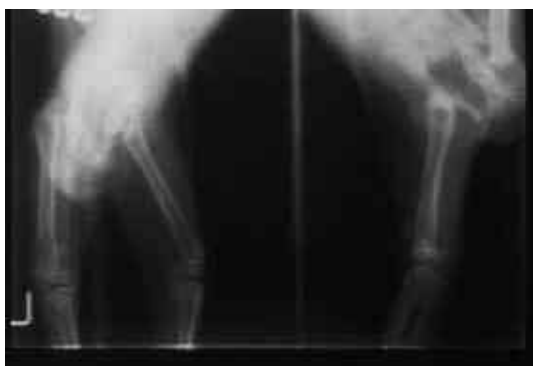

Figure 2. Case no. 5, 6 month follow up

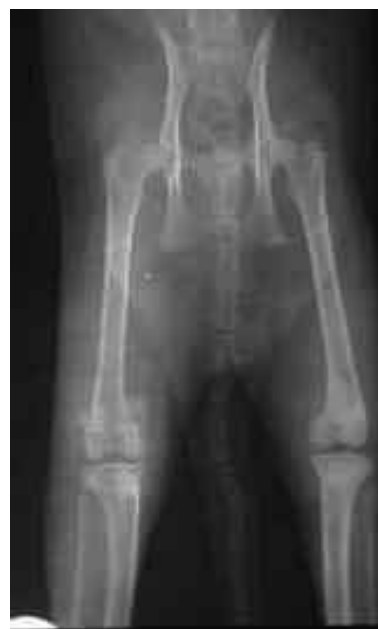

Figure 3. Case no. 4 (Pre-operative)

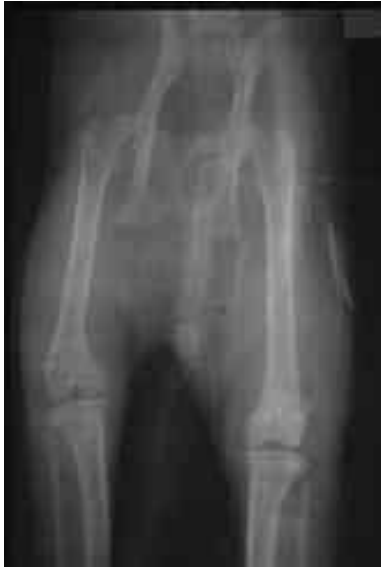

Figure 4. Case no. 4 (Post-operative)

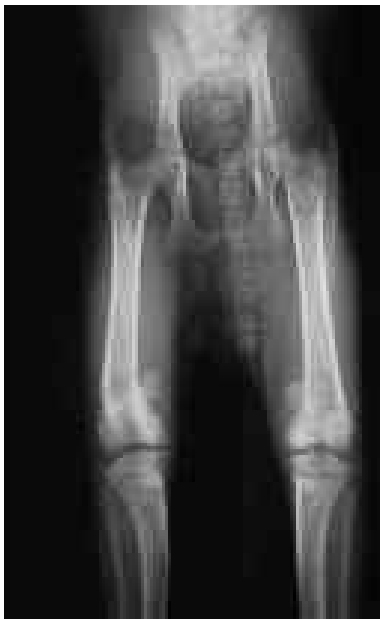

Figure 5. Case no. 7 (Pre-operative)

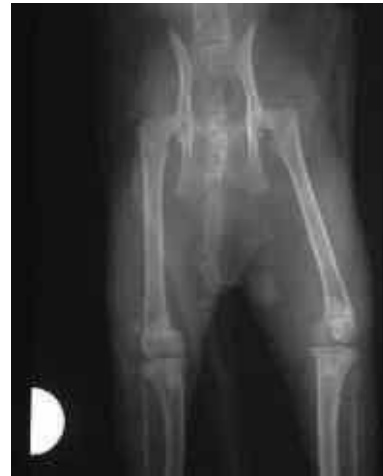

Figure 6. Case no. 7 (Post-operative right stifle joint)

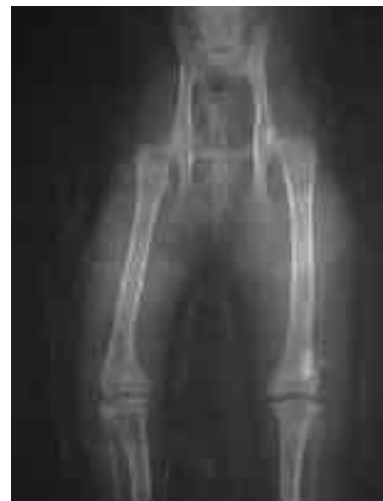

Figure 7. Case no. 7 (Post-operative-bilateral luxations)

Discussion

Patellar luxation cases are very rare in cats. Occurrence of only 8 cases (a rate of 0.10%) in this study confirms the published reports (3-6). A rate of 0.15% among all the orthopedic disorders in cats is a rather low incidence compared to other diseases in cats. All the cats were under the age of two except one, which was 12 years old, which is in agreement with the literature (15).

The patellar luxation in the 12-year-old cat occurred following subluxation of the femoral head. Patellar luxations have been reported to be either congenital or acquired (2,5,9,11). In this study, congenital patellar luxation was observed in 3 cases. Lateral torsion of the distal of the femur in one in these cases (case no. 5) confirms the literature stating that dysplasia of the femoral epiphysis and medial dislocation of the tibial tuberosity is a congenitally originating etiological factor (8,9,11,13). Acquired patellar luxations in cats are reported to have a traumatic origin (15). In this study, only 1 of the 5 cases of acquired origin was suspected to have occurred due to trauma. The presence of obvious capsule laxity in other 4 cases suggested that the luxation

had occurred gradually. Hereditary patellar luxation can occur as a breed disposition in Devon-Rex, British Shorthaired and Siamese cats (4-7). It was revealed that the congenital patellar luxations occurring in 3 cases with different breed characteristics were not present in the littermates, which had the same genotype. This finding is parallel to the conclusions of Davis and Gill (4), who suggest that patellar luxations in cats are not hereditary. Radiographic examination is used to determine the position of the patella within the trochlear groove of the femur and the degree of trochlear depth (1,2,5,9,10). It is recommended that the skyline imaging technique be used to confirm radiological diagnosis (18). Radiographs taken by skyline technique were much better at confirming the diagnosis and determining the depth of the trochlear groove compared to the antero-posterior position. The prognosis of patellar luxations in cats has been reported to be good (1,19). Similar to our findings Houlton and Meynink (15) have reported that treatment

of patellar luxation in cats is either conservative or operative. Considering the fact that the desired positive result from the conservatively treated 2 cases has not been achieved, we do not agree with the researchers claiming conservative treatment could be a preferable method. Operatively, different techniques described earlier have been used (2,5,8-11). Koch and Montavon (19) have recommended sulcoplasty and tibial tuberosity transposition or the combination of these methods. In this study, while capsuloraphy was carried out in only one case (case no. 1), sulcoplasty together with capsuloraphy was applied to the remaining 5 cases. Successful surgical results were achieved in all cases due to less traumatizing techniques without an osteotomy.

It was concluded that skyline-imaging technique along with clinical examination must be used for the diagnosis and of patellar luxation and combining the sulcoplasty and capsuloraphy techniques can increase the success rate of surgical treatment.

References

1. Anteplioğlu, H., Samsar, E., Akin, F.: Veteriner Özel Şirurji. Ankara Üniversitesi, Veteriner Fakültesi Yayınları. Ders Kitabı. 1986; 406: 708-711.
2. Aslanbey, D.: Veteriner Ortopedi ve Travmatoloji. Medisan Yayınevi. Ankara. 1996; 195-207.
3. Yücel, R.: Veteriner Özel Cerrahi. İkinci basım. Pethask Yayınları. İstanbul. 1998; 350-351.
4. Davis, M., Gill, I.: Congenital patellar luxation in the cat. *Vet. Rec.*, 1997; 121: 474-475.
5. Denny, H.R., Butterworth, S.: A guide to canine and feline orthopaedic surgery. Fourth Edition. Blackwell Science. 2000; 512-554.
6. Flecknell, P.A.: Luxation of the patella in cats. *Vet. Rec.*, 1977; 100: 536.
7. Flecknell, P.A., Gruffydd-Jones, T.J.: Congenital luxation of the patellae in the cat. *Feline Prac.*, 1979; 9: 18-20.
8. Wasseur, P.B.: Stifle Joint In: Textbook of small animal surgery. Second Edition. W.B. Saunders Company. 1994; 1885-1862.
9. Dueland, R.T.: Orthopedic disorders of the stifle. In: Saunders Manuel of Small Animal Practice. W.B. Saunders Company. Philadelphia. 1994; 1031-1034.
10. Piermatei, D.I., Flo, G.L.: Handbook of Small Animal Orthopedics and Fracture Repair. W.B. Saunders Company. Philadelphia. 1997; 516-581.
11. Slocum, B, Slocum, T.D.: Knee. In: Current Techniques in Small Animal Surgery. W.W. A Waverly Company. 1998; 1222-1244.
12. Özer, K., Bakır, B., Şadalak, D.: Hip dysplasia in two cats. *J. Turkish Vet. Surg. Assoc.*, 1997; 3: 53-55.
13. Fossum, T.W., Hedlund, C.S., Hulse, D.A., Johnson, A.L., Seim, H.B., Willard, M.D., Carroll, G.L.: Small Animal Surgery. Mosby-Year Book Inc. St Louis. 1997; 976-986.
14. Prior, J.E.: Luxating patellae in Devon Rex cats. *Vet. Rec.*, 1985; 117: 154-155.
15. Houlton, J.E.F., Meynink, S.E.: Medial patellar luxation in the cat. *J. Small Anim. Prac.*, 1989; 30: 349-352.
16. Smith, G.K., Langenbach, A., Green, P.A., Rhodes, W.H., Gregor, T.P., Giger, U.: Evaluation of the association between medial patellar luxation and hip dysplasia in cats. *J. Am. Vet. Med. Assoc.*, 1999; 215: 40-45.
17. Bennett, D.: Feline Medicine and Therapeutics. Eds, E.A. Chandler, C.J. Gaskell, and A.D.R. Hilbery. Blackwell Scientific Publications. Oxford. 1985; 102.
18. Kealy, K.J.: Diagnostic radiology of the dog and cat. Second Edition. Philadelphia. 1987; 306-351.
19. Koch, D.A., Montavon, P.M.: Klinische Erfahrungen bei der Therapie der Patellarluxation des Kleintieres mittels Sulkoplastik und seitlicher und kranialer verschiebung der Tuberositas tibiae. *Schweiz. Arch. Tierheil.*, 1997; 136: 259-264.