

1-1-2005

## Transrectal Ultrasonographic Examination of the Urinary System in Holstein Cows

SAVAŞ ÖZTÜRK

İBRAHİM DEMİRKAN

MURAT KİBAR

ALİ BUMİN

SELÇUK PEKKAYA

Follow this and additional works at: <https://journals.tubitak.gov.tr/veterinary>



Part of the [Animal Sciences Commons](#), and the [Veterinary Medicine Commons](#)

---

### Recommended Citation

ÖZTÜRK, SAVAŞ; DEMİRKAN, İBRAHİM; KİBAR, MURAT; BUMİN, ALİ; and PEKKAYA, SELÇUK (2005) "Transrectal Ultrasonographic Examination of the Urinary System in Holstein Cows," *Turkish Journal of Veterinary & Animal Sciences*: Vol. 29: No. 2, Article 11. Available at: <https://journals.tubitak.gov.tr/veterinary/vol29/iss2/11>

This Article is brought to you for free and open access by TÜBİTAK Academic Journals. It has been accepted for inclusion in Turkish Journal of Veterinary & Animal Sciences by an authorized editor of TÜBİTAK Academic Journals. For more information, please contact [academic.publications@tubitak.gov.tr](mailto:academic.publications@tubitak.gov.tr).

## Transrectal Ultrasonographic Examination of the Urinary System in Holstein Cows\*

Savaş ÖZTÜRK, İbrahim DEMİRKAN

Department of Surgery, Faculty of Veterinary Medicine, Kafkas University, Kars - TURKEY

Murat KİBAR

Department of Surgery, Faculty of Veterinary Medicine, Erciyes University, Kayseri - TURKEY

Ali BUMİN

Department of Surgery, Faculty of Veterinary Medicine, Ankara University, Ankara - TURKEY

Selçuk PEKKAYA

Department of Internal Diseases, Faculty of Veterinary Medicine, Ankara University, Ankara - TURKEY

Received: 27.01.2003

**Abstract:** In this study, it was aimed to examine the urinary system and to determine normal ultrasonographic appearance by rectal ultrasonography in Holstein cows.

The study material consisted of 20 bladders, 20 urethras, and 20 right and 20 left kidneys, in 20 Holstein cows. A portable ultrasonograph combined with a 6 MHz linear rectal probe (transducer) was used for the examination. Bladder lumen was determined as an anechoic structure in the ventral aspect of the rectum and its wall was hyperechoic. By moving the probe caudally, the anechoic structure of the urethra was monitored. Right and left kidneys were examined after moving the probe cranio-dorsally. The lobular structure of the kidneys was determined in all cows.

Cortex, medulla, renal parenchyma, renal sinus and medullar pyramids of kidneys were identified having different echogenic structures.

It was concluded that rectal ultrasonographical examination can reliably be used to diagnose urinary system diseases in cows.

**Key Words:** Ultrasonography, transrectal, urinary system, cattle, Holstein

### Holstein Irkı İneklerde Üriner Sistemin Transrektal Ultrasonografik Muayenesi

**Özet:** Bu çalışmada, Holstein ırkı ineklerde üriner sistemin rektal ultrasonografi ile muayene edilmesi ve normal ultrasonografik görünümün belirlenmesi amaçlanmıştır.

Çalışma materyalini, 20 Holstein ırkı ineğe ait 20 sidik kesesi ve 20 uretra ile 20 sağ ve 20 sol olmak üzere toplam 40 böbrek oluşturdu. Muayeneler portatif ultrasonografi cihazı ile 6 MHz'lik lineer rektal prob (transducer) ile yapıldı. Sidik kesesinin lümeni rektumun ventralinde anekoik bir yapı olarak belirlenirken, çeperi hiperekoik olarak tespit edildi. Probu kaudale doğru yönlendirilmesi ile anekoik yapıdaki uretra görüntüldü. Sağ ve sol böbrek, probun kraniodorsal yönlendirilmesinden sonra muayene edildi. İneklerin tümünde böbreklerin lobuler yapısı ultrasonografik olarak belirlendi.

Böbreklerde korteks, medulla, renal paransim, renal sinus ve meduller piramitler değişik ekojenik yapılar olarak tanımlandı.

Çalışmanın bulguları ineklerde üriner sistem hastalıklarının tanısında rektal ultrasonografik muayenelerin güvenle kullanılabileceğini göstermiştir.

**Anahtar Sözcükler:** Ultrasonografi, transrektal, üriner sistem, sığır, Holstein

### Introduction

The urinary system in cattle anatomically and functionally can be categorized into two parts: the upper urinary tract (kidneys and ureters) and the lower urinary

tract (bladder and urethra). Macroscopically kidneys can be divided into three layers as the capsula, parenchyma and sinus. Renal parenchyma has a cortex and a medulla. The medulla possesses 8 or 10 pyramids depending on

\* A part of the study was presented at the 2<sup>nd</sup> Buiatri Congress, 2001, Bursa, Turkey.

the animal species. Pelvis renalis is missing in cattle. Urine flows from renal papillas through the calices. The right kidney is located on the ceiling of the abdomen, stuck between the last costae and processus transversus of the 2<sup>nd</sup> -3<sup>rd</sup> lumbar vertebrae. Ventral surface faces the liver, pancreas, duodenum and colons. Whereas the left kidney is situated backwardly and underneath the right kidney that can move towards the medial site depending on the rumen's filling (1,2).

Urinary system diseases can be classified as renal diseases (glomerulonephritis, interstitial nephritis, chronic interstitial nephritis, pyelonephritis, acute tubular necrosis [nephrosis], amyloidosis, nephrolithiasis, renal neoplasia, congenital defects) and urinary tract diseases (prolapsus of bladder and canals, rupture of urinary tract, pathological changes in status, enzootic hematuria, and enzootic balanopostitis) (3-5).

For the diagnosis of urinary system diseases, clinical examination, urine evaluation, blood count, serum biochemical analysis, manual palpation, radiography and ultrasonography can all be used (1,2,6).

By ultrasound examination a number of disorders can be diagnosed. These include nephrolithiasis or urolithiasis, hydronephrosis, cyst, neoplasia and renal parenchyma diseases in dogs and horses, and pyelonephritis and nephrolithiasis in cattle and sheep (1,7-13).

Ultrasonographic examination and anatomy of urinary system in Swiss Braunvieh cattle has been studied and reported that the right kidney can be examined transabdominally through lumbar and paralumbar region whereas the left kidney, bladder and urethra should be transrectally approached (1,2).

In this study it was aimed to examine urinary system by rectal ultrasonography and to determine normal ultrasonographic vision of the urinary system in Holstein breed of cattle.

## Materials and Methods

Clinically healthy 20 Holstein cattle were selected for the study. A portable ultrasound (Pie Medical, 100 Falco Vet) and 6 MHz linear transducer was used.

Ultrasonographic examination was performed on standing animals. After removing rectal content the transducer was covered with jelly and placed in an operation glove that was used by the applicator.

Initially the ultrasonographic examination started from the bladder. The transducer was placed around the cranial aspect of the symphysis pubis. The bladder was identified at the ventral aspect of the rectum. By directing the transducer caudally the urethra was observed. To distinguish the urethra in a better vision the animal was encouraged to urinate by manipulating the vulvar labia. Following the visualization of the bladder and urethra the kidneys were examined. The transducer was placed in dorsal aspect of the rectum that was parallel to the vertebral column. Then, it was cranially advanced until the vision of the left kidney discernable. Vertical radius of kidney, horizontal radius of sinus, radius of ventral cortex and medulla, and dimension of the medullar pyramids were measured. And then the transducer was cranially but obliquely advanced to observe the "liver window" (1), which corresponded to the typical appearance of the right kidney.

## Results

Cavity of the bladder was identified as an anechoic structure (lacking internal echoes) if it was fully distended. The bladder was observed in different shapes (i.e. ovoid, teardrop-shaped) depending on the amount of urine in it contained (Figure 1). The wall of the bladder showed a hyperechoic (whiter) appearance. The degree of bladder distension usually reflected the visibility of the wall layers. Cases that contained average amount of urine in the bladder, the wall was identified having three layers. The outermost layer (serosa) was hyperechoic, the middle layer (muscular) was hypoechoic (black), whereas the inner layer (mucosa) was observed hyperechoic.

During urination, the urethra seemed to be anechoic in character (Figure 1). After the urination the urethra collapsed and disappeared from the vision. By the guidance of ultrasonographic visualization a catheter was advanced to the bladder through the orificium urethra externa. Therefore the orificium urethra interna was successfully imaged.

The echo pattern of normal organs was usually specific. Various structures of the kidneys were identified in different echogenic images. The parenchyma of the kidney was hypoechoic, whereas the sinus was hyperechoic. Cortex displayed hypoechoic and medullar pyramid anechoic fields. But no image of ureter was produced (Figure 2). The right kidney was distinguished

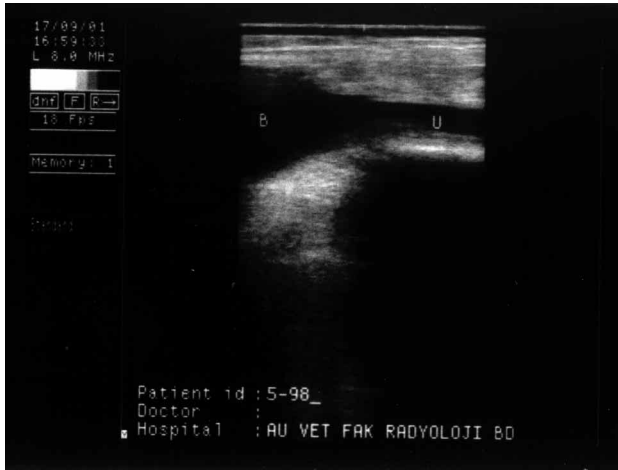

Figure 1. Transrectal sonogram of bladder and urethra of the case no.5 (B-Bladder, U-Urethra).

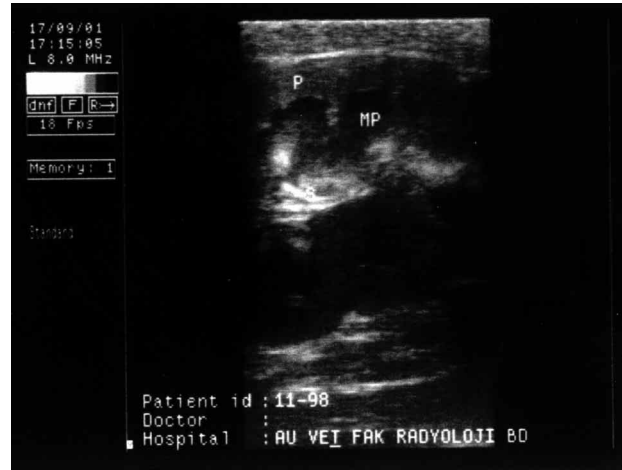

Figure 2. Transrectal sonogram of the left kidney of the case no.11 (P-Renal Parenchyma, MP-Medullary pyramid, S- Renal sinus).

from liver window by means of being less echogenic (brighter) in comparison to the liver (Figure 3).

The vertical diameter of left kidney, horizontal diameter of sinus and ventral diameter of medulla, and the dimensions of small and large medullary pyramids were measured (Figure 4). The vertical diameter of left kidney was 6.39 cm, horizontal diameter of sinus was 4.52 cm, and ventral diameter of cortex-medulla was 2.56 cm whereas small medullary pyramids were 0.87 cm and large medullary pyramids were 1.65 cm (Table).

## Discussion

To observe the bladder, urethra, and left and right kidneys a transrectal ultrasonographic approach was successfully carried out in this study. However, it was reported that ultrasound examination of the right kidney could be possible through trans-abdominal regions, i.e. lumbar or paralumbar region (1,2).

In contrast to other studies (1,2,6) that showed ultrasound images of bladder, kidneys and urethra with an echogenic appearance in cows, our study indicated that the bladder lumen filled with urine displayed anechoic fields with various shapes (ovoid or teardrop-shape) due to the amount of urine in the bladder. When the bladder was full with urine it was not possible to observe the layers of the wall. However, when the bladder was half full, three wall layers were identified, from outside to inside serosal layer (hyperechoic intensity), muscular layer (hypoechoic intensity) and mucosal layer (hyperechoic

intensity). Ultrasound is ideally suited for examination of the urinary bladder (14). Even a small bladder not detected by abdominal palpation or radiographs can be identified using ultrasound.

It is difficult to examine the right kidney by transrectal ultrasound because of its anatomical position; therefore detailed examination may be achieved by transabdominal approach (2). But our examination via transrectal ultrasound suggests that when the transducer is placed at cranio-oblique position, the right kidney in liver window shape that is less echogenic than liver can be visualized. In addition the liver was easily identified because of the bright parallel echoes produced by the portal veins. Although detailed examination of the right kidney was not practical using this approach, the compact lesions/masses located in the right kidney can be identified by transrectal ultrasound.

The ureters in healthy cattle could not be visualized by ultrasound (1,2). In our study all efforts also failed to demonstrate the ureters.

The findings of the current study differed from the study of Braun (1). He reported the vertical diameter of kidney (5.1 cm), ventral diameter of cortex-medulla (1.9 cm) and horizontal diameter of sinus (5.3 cm) to be less in Swiss Braunvieh. This indicates that Holstein breed have bigger kidney dimensions than Swiss Braunvieh according to the ultrasound examination.

We believe that in areas with hair (as in transabdominal sonography) the hair will trap air and this

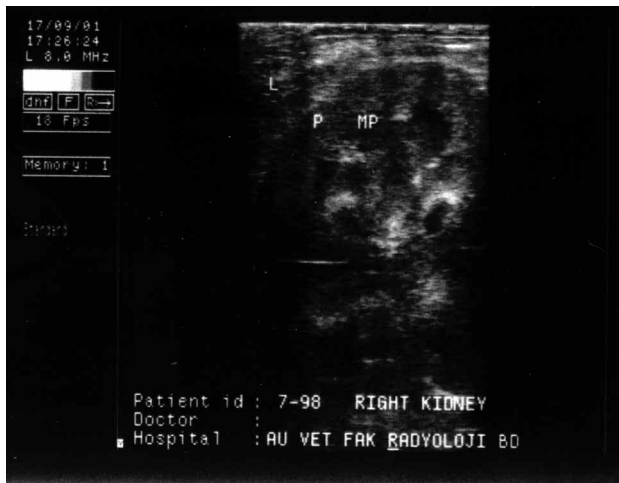

Figure 3. Transrectal sonogram of the right kidney of the case no.7 (L- Liver parenchyma, P- Renal parenchyma, MP- Medullar pyramid).

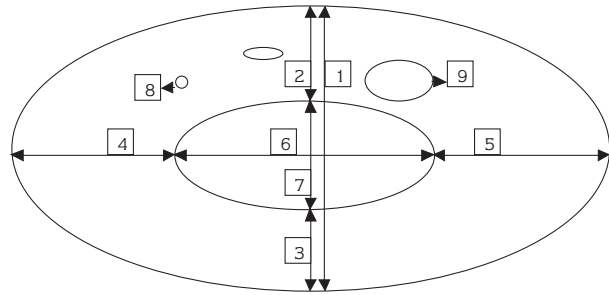


Figure 4. Schematic representation of the kidney. 1-Vertical diameter of the kidney. 2- Dorsal diameter of the renal cortex and medulla. 3- Ventral diameter of the renal cortex and medulla. 4- Medial diameter of the renal cortex and medulla. 5- Lateral diameter of the renal cortex and medulla. 6- Horizontal diameter of the renal sinus. 7- Vertical diameter of the renal sinus. 8- Medullar pyramid (small). 9- Medullar pyramid (large).

Table. Diameters (R) of the kidney of cases.

Case No.	R (cm)				
	Vertical	Renal Sinus	Cortex-medulla	Medullar pyramid (small)	Medullar pyramid (large)
1	5.52	3.78	2.42	0.83	1.60
2	6.08	4.71	2.56	1.10	2.56
3	6.52	4.80	2.80	1.04	1.54
4	6.80	4.50	2.60	1.34	2.05
5	6.53	4.98	2.76	1.28	2.27
6	6.01	4.84	2.35	0.76	1.72
7	5.45	3.06	3.16	0.78	1.28
8	6.82	4.98	2.80	1.06	1.93
9	5.53	3.98	2.19	0.41	0.76
10	5.56	3.94	2.10	0.90	1.44
11	7.10	5.05	3.22	1.19	1.56
12	7.21	5.03	3.60	0.84	1.51
13	7.60	5.27	2.40	0.45	1.93
14	5.93	4.23	1.90	0.97	1.64
15	6.62	4.98	1.73	0.45	1.73
16	6.37	4.52	1.94	0.73	1.62
17	7.24	5.04	3.09	0.80	1.55
18	5.96	3.35	2.75	1.23	1.70
19	6.74	4.85	2.84	0.73	1.55
20	6.25	4.42	2.06	0.60	1.20
Mean	6.39	4.52	2.56	0.87	1.65

interferes with sound transmission. A specific artifact often occurs at the point of contact between the transducer and the skin. Therefore transrectal sonography eliminates these undesired artifacts.

The use of ultrasound to obtain images of the urinary tract can be valuable. The advantages over radiography are those of safety and ability to investigate fluid spaces without resort to contrast techniques (15).

In conclusion, normal ultrasound images of urinary system and kidney diameters in Holstein breed cattle were determined. From the preventive medicine point of view, it is possible to detect lesions located in the urinary tract before clinical manifestations occur by ultrasound aided evaluation of the cattle.

## References

1. Braun, U.: Ultrasonographic examination of the right kidney in cows. *Am. J. Vet. Res.*, 1991; 52: 1933-1939.
2. Braun, U.: Ultrasonographic examination of the left kidney, the urinary bladder, and the urethra in cows. *J. Vet. Med.*, 1993; 40: 1-9.
3. Juzwiak, J.S., Baint, F.T., Slone, D.E., Santshi, E.M., Johnson, J.J.: Unilateral nephrectomy for treatment of chronic hematuria due to nephrolithiasis. *Can. Vet. J.*, 1988; 29: 931-933.
4. Rantanen, N.W.: Disease of the kidneys. *Vet. Clin. North. Am. Equine Pract.*, 1986; 2: 103-108.
5. Tyler, J.W., Smith, B.P., Irvine, J.: Hydronephrosis and pyelonephritis associated with an anomalous vas deferens in a bull. *J. Am. Vet. Med. Assoc.*, 1991; 198: 871-872.
6. Konde, L.J., Wrigley, R.H., Park, R.D., Lebel, J.L.: Ultrasonographic anatomy of normal canine kidney. *Vet. Radiol.*, 1984; 25: 173-178.
7. Barr, F.J., Hold, P.E., Gibbs, C.: Ultrasonographic measurement of normal renal parameters. *J. Small Anim. Pract.*, 1990; 31: 180-184.
8. Divers, T.J., Reef, V.B., Roby, K.A.: Nephrolithiasis resulting in intermittent ureteral obstruction in a cow. *Cornell Vet.*, 1989; 79: 143-149.
9. Hayashi, H., Biller, D.S., Rings, D.M., Miyabayashi, T.: Ultrasonographic diagnosis of pyelonephritis in a cow. *J. Am. Vet. Med. Assoc.*, 1994; 205: 736-738.
10. Hirsbrunner, G., Lang, J., Nicolet, J., Steiner, A.: Nephrectomy for chronic, unilateral suppurative pyelonephritis in cattle. *Tierarztl. Prax.*, 1996; 24: 17-21.
11. Kimme-Smith, C., Perrella, R.R., Kaveggia, L.P., Cochrane, S., Grant, E.G.: Detection of renal stones with real-time sonography: effect of transducers and scanning parameters. *Am. J. Roentgenol.*, 1991; 157: 975-980.
12. Pusterla, N., Braun, U.: Ultrasonic examination of the pancreas in healthy cows. *Vet. Radiol. Ultrasound.*, 1997; 38: 63-67.
13. Rebhun, W.C., Dill, S.G., Perdrizet, J.A., Hatfield, C.E.: Pyelonephritis in cows: 15 cases (1982-1986). *J. Am. Vet. Med. Assoc.*, 1989; 194: 953-955.
14. Biller, D.S., Kantrowitz, B., Partington, B., Miyabayashi, T.: Diagnostic ultrasound of the urinary bladder. *J. Am. Anim. Hosp. Assoc.*, 1990; 26: 397.
15. Barr, F.J.: *Diagnostic ultrasound in the dog and cat.* Blackwell Scientific Publication, Oxford. 1990.