

1-1-2015

Evaluation of patency following revision technique of high-velocity arteriovenous fistula

ÜMİT HALICI

MEHMET ALİ KAYGIN

ÖZGÜR DAĞ

AHMET AYDIN

HÜSNÜ KAMİL LİMANDAL

See next page for additional authors

Follow this and additional works at: <https://journals.tubitak.gov.tr/medical>



Part of the [Medical Sciences Commons](#)

Recommended Citation

HALICI, ÜMİT; KAYGIN, MEHMET ALİ; DAĞ, ÖZGÜR; AYDIN, AHMET; LİMANDAL, HÜSNÜ KAMİL; ARSLAN, ÜMİT; ÇALIK, EYÜP SERHAT; and ERKUT, BİLGEHAN (2015) "Evaluation of patency following revision technique of high-velocity arteriovenous fistula," *Turkish Journal of Medical Sciences*: Vol. 45: No. 4, Article 37. <https://doi.org/10.3906/sag-1406-71>

Available at: <https://journals.tubitak.gov.tr/medical/vol45/iss4/37>

This Article is brought to you for free and open access by TÜBİTAK Academic Journals. It has been accepted for inclusion in Turkish Journal of Medical Sciences by an authorized editor of TÜBİTAK Academic Journals. For more information, please contact academic.publications@tubitak.gov.tr.

Evaluation of patency following revision technique of high-velocity arteriovenous fistula

Authors

ÜMİT HALICI, MEHMET ALİ KAYGIN, ÖZGÜR DAĞ, AHMET AYDIN, HÜSNÜ KAMİL LİMANDAL, ÜMİT ARSLAN, EYÜP SERHAT ÇALIK, and BİLGEHAN ERKUT

Evaluation of patency following revision technique of high-velocity arteriovenous fistula

Ümit HALICI^{1*}, Mehmet Ali KAYGIN², Özgür DAĞ², Ahmet AYDIN³, Hüsnü Kamil LİMANDAL²,
Ümit ARSLAN², Eyüp Serhat ÇALIK², Bilgehan ERKUT²

¹Department of Cardiovascular Surgery, Samsun Training and Research Hospital, Samsun, Turkey

²Department of Cardiovascular Surgery, Erzurum Regional Training and Research Hospital, Erzurum, Turkey

³Department of Cardiovascular Surgery, Konya Numune State Hospital, Konya, Turkey

Received: 20.06.2014 • Accepted/Published Online: 28.12.2014 • Printed: 30.07.2015

Background/aim: The objective of this study is to report our experience with surgical revision of dialysis access-induced ischemia syndrome.

Materials and methods: Between January 2005 and July 2013, 1254 patients underwent arteriovenous fistula operation, and 86 of them [53 males, mean age: 55 ± 25 (range: 25 to 75) years; 33 females, mean age: 50 ± 20 (range: 30 to 70) years] subsequently developed steal syndrome. These patients were treated with arterial pressure-controlled polytetrafluoroethylene banding or constriction with polypropylene suturing technique. Patients were followed in the outpatient clinic at regular intervals.

Results: Symptoms were not relieved during the first 15 days in 4 patients; therefore, reintervention was performed. Thrombosis occurred in one patient after reintervention. No early or late complications were detected in other patients, and fistulae were suitable for hemodialysis. Patency rates at 6 and 12 months were 96% and 92%, respectively, and thrombosis rates were 7% and 9%. There was no hospital mortality in our study, but one patient died from unrelated causes and two other patients quit follow-up after 6 months.

Conclusion: We think that arterial pressure-controlled surgical revision is an effective and safe technique in patients with fistula-related hand ischemia.

Key words: Hemodialysis, arteriovenous fistula, hand ischemia, banding technique

1. Introduction

A well-functioning vascular access (VA) is a certain requirement for providing life-sustaining hemodialysis treatment in end-stage renal disease (ESRD) patients (1). Although autogenous arteriovenous fistula (AVF) is accepted as the ideal VA and is referred to as a 'lifeline', it is not always easy to construct and AVF creation may cause complications (2). The most frequent complications of AVF are aneurysm, failure to maturation, and thrombosis (3). Among complications of native AVF, symptomatic dialysis access-induced ischemia syndrome (DAIIS), also known as steal syndrome, is rarely seen. On the other hand, it is a serious problem and it may cause some clinical findings like ischemic neuropathy, resting pain, and ulceration or tissue necrosis of fingers that may lead to amputation. It can be seen especially after high volume AVF, and its incidence rate in native AVF varies between 1% and 10% in the literature (4). The objective of this retrospective study is to report our experience with surgical revision of fistulae with DAIIS.

2. Materials and methods

Between January 2005 and July 2013, 1254 patients with ESRD underwent arteriovenous fistula operations, and 86 of them [53 males, mean age: 55 ± 25 (range: 25 to 75) years; 33 females, mean age: 50 ± 20 (range: 30 to 70) years] subsequently developed DAIIS (steal syndrome) and were included in this study. Written informed consent was received from the patients. This study was approved by the local institutional review board. Seventy of them had native AVF and 16 of them had AVF with synthetic polytetrafluoroethylene (PTFE) graft. These patients had been treated with hemodialysis for about 4 ± 3 years, and all of them had had prior AVF operations at the wrist and the elbow. Patients with native AVFs had brachiocephalic AVF, and other patients had brachioaxillary AVF. DAIIS can be classified into four stages according to the degree of severity (Table) (5). According to this classification, retrograde inflow of blood into the access during diastole is detected in AVF, but the patients have no complaints

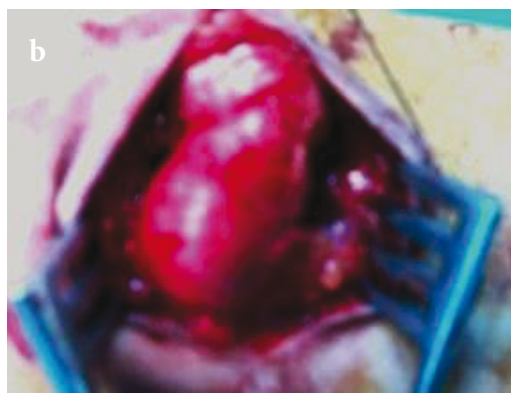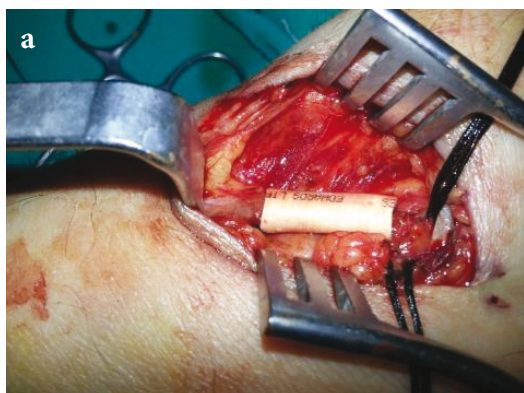
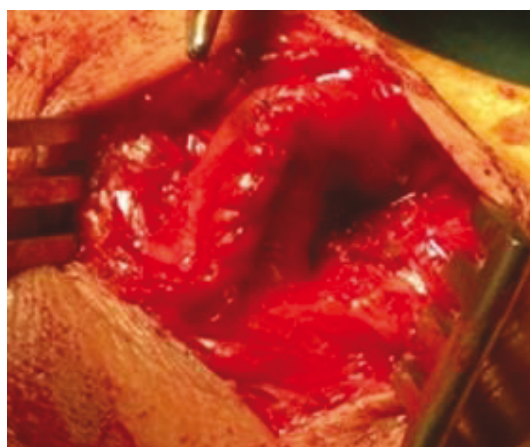
* Correspondence: uhalici2003@yahoo.com

Table. Classification of DAIIS.

Stage	Findings
Stage 1	Retrograde diastolic flow without complaints; steal phenomenon
Stage 2	Pain on exertion and/or during hemodialysis
Stage 3	Resting pain
Stage 4	Ulceration or necrosis or gangrene

(stage 1) and it does not require intervention (6). Patients with pain on exercise or during dialysis (stage 2), however, require attention, because of the risk of deterioration to stage 3 (resting pain) or stage 4 (necrosis) in their early phases. These patients were diagnosed by clinical examination and color flow Doppler ultrasound evaluation. Patients with grade 2, 3, and 4 DAIIS were operated on. Some clinical findings of our patients with hand ischemia were pallor and coldness, absence of radial and ulnar artery pulses, intolerable pain under exertion or pain during dialysis, resting pain, cyanosis, and ulcerations

of digits. The most common complaint of our patients was pain. The brachial artery and radial artery were cannulated and arterial pressures were monitored and recorded during the operation. We used sterile Doppler ultrasound probe for measurement of AVF flow. Our patients' fistula mean flow velocity was 900 ± 100 mL/min. Autogenous AVFs were treated with arterial pressure-controlled PTFE banding and synthetic PTFE grafts were treated with constriction with a polypropylene suturing technique (3 cm distal to AVF anastomoses) (Figures 1 and 2). Our aim was to constrict the AVF until the radiobrachial index was

**Figure 1.** Polytetrafluoroethylene banding technique.**Figure 2.** Constriction with polypropylene suturing technique.

0.5 in both techniques and intraoperative measurements of flow velocities were approximately 400 mL/min and 600 mL/min in native fistulae and synthetic PTFE grafts, respectively.

Patients were followed in the outpatient clinic at regular intervals. Patients were seen in the outpatient clinic at 1, 3, 6, and 12 months after the surgery. Color flow Doppler ultrasound evaluation was performed and flow velocities were measured for all patients. AVF patency and symptoms of patients were recorded.

3. Results

The most common risk factors of our patients were diabetes mellitus (DM) and peripheral arterial occlusive disease (PAOD). DM was detected in 22 patients (25.5%) and PAOD was detected in 10 patients (11.6%). In our study group, 21 patients (24.4%) had pallor and cold hands (stage 1), but they had no complaints. Sixty patients (69.8%) had intolerable pain under exertion or pain during dialysis treatments and impalpable pulses (stage 2), while 4 (4.7%) patients had resting pain (stage 3) and 1 patient (1.1%) had cyanosis of digits and ulcerations (stage 4).

Symptoms and findings were improved partially or completely by the banding or constriction procedures in all patients. Cyanosis of fingers regressed, finger ulcers were healed partially, and resting and exertion pain subsided. However, complete remission of symptoms were not observed in 4 patients (4.7%) for the first 15 days and in 6 patients (7%) for the first month. Reintervention was performed due to thrombosis. Thrombosis reoccurred in one patient after reintervention. AVF thrombectomy was performed successfully again and the AVF was saved. Patency rates at 6 and 12 months were 96% and 92%, respectively, and thrombosis rates were 7% (6 patients) and 9% (8 patients). Rate of remission of ischemic symptoms at 12 months was 98.72%. Limb salvage rate at 12 months was 100%. There was no hospital mortality in our study, but one patient died from unrelated causes and two patients quit follow-up after 6 months.

4. Discussion

AVF is a surgically created connection between an artery and vein in patients with end-stage renal failure. The native AVF is the optimum option for hemodialysis patients, as it is associated with lower complication rates compared to other forms of hemodialysis accesses (7). AVFs might have hemodynamic complications, which may lead to neurological or ischemic problems. The pathophysiologic mechanisms of DAIIS are complex and poorly understood. Shunting of blood away from high-resistance arm and forearm arteries to a low-resistance area in arteriovenous access, resulting in hypoperfusion distal to the anastomosis, has been generally assumed to

be the reason. Furthermore, presence of arterial stenosis beyond the AVF anastomosis may also play a critical role in the etiology (8). Ischemic neuropathy can be seen due to damage to peripheral nerves because of compromised blood supply. Treatment should be started with a detailed history and physical examination to rule out nonischemic causes of hand pain of patients with AVF. Advanced age, diabetes, female sex, PAOD, large conduits such as femoral or popliteal veins, and history of multiple prior procedures increase the risk of steal syndrome in upper extremities (9). In our study, the most common risk factors of our patients were DM and PAOD, whereas DAIIS was found to be more common in males than females.

The incidence rate of DAIIS requiring an intervention was 6% in our study, which was detected between the 1st and 4th weeks after creation of an AVF. The ideal treatment option for DAIIS must reverse the ischemia while preserving the access; however, there was no ideal treatment for this purpose (10). Stolic et al. (11) reported in their study that they monitored patients with mild DAIIS and a radical approach is not required in these patients. They pointed out that the strategic application of a treatment depends on the severity of symptoms and comorbidities of the patients and the skill of the surgical team (11). We followed the grade 1 patients and did not perform any operations for those patients. We operated on patients with grade 2, 3, and 4 DAIIS.

Catheter-based interventions to repair arterial stenoses, ligation of the access, banding, distal revascularization-interval ligation, revision using distal inflow, and proximal arterial inflow procedures, among others, can be performed for the treatment of symptomatic patients with DAIIS (12). Recently, some investigators have applied percutaneous transluminal angioplasty to treat arterial stenosis with the resolution of hand ischemia and healing of digital ulcers (13). Percutaneous interventions such as intravascular coil insertion, percutaneous balloon angioplasty, and intravascular stent insertion can also be performed to ameliorate DAIIS (8).

Closure of an AVF (ligation) is another option that is chosen by some. Although this intervention improves peripheral circulation immediately and symptoms are relieved, the surgeon has to find a new suitable artery and vein to create a new AVF after closure of the old one. Furthermore, the new fistula needs time to mature, so a hemodialysis catheter is inserted into another vein to ensure hemodialysis during this period. Again, there is a risk of developing ischemia in the new AVF. On the other hand, ligation of the access limits the patient's long-term access options. Therefore, correction of DAIIS must preserve the access and, at the same time, improve peripheral arterial circulation (14).

Based on reports about unsatisfactory improvement of DAIIS and high rates of AVF thrombosis, the banding technique was not recommended in some studies (15,16). Additionally, there are reports that DAIIS healed in 90% to 100% of patients, while only 10% to 40% of the banded accesses remained patent in some studies (16–18). Mickley (14) reported that low fistula flow rate caused by banding may result in inefficient dialysis therapy or even access thrombosis while DAIIS syndrome disappears. On the other hand, Van Hoek et al. (19) reported that ischemic symptoms attenuated and all patients successfully continued their dialysis therapy after banding of hemodialysis access to treat hand ischemia. Hastaoğlu et al. (20) reported in their study that the continuity of dialysis can be highly sustained in patients with steal syndrome due to dialysis, maintaining the current arteriovenous fistulae through appropriate revision techniques. Özbek et al. (21) reported that controlled banding with brachial and radial artery pressure monitoring reduces the risk of fistula thrombosis and reinterventions (21). In that study, patency and thrombosis rates at 12 months were 90% and 10%, respectively, and the rate of relief of symptoms was 95%. Likewise, in our study, patency rates at 6 months and 12 months were 96% and 92%, respectively. On the other hand, thrombosis rates at 6 months and 12 months were

7% and 9%, respectively. Moreover, ischemic symptoms disappeared completely in 89% of our patients.

The access banding technique aims to create a narrow vessel segment within the access or reduce flow through the anastomosis. Native fistulae can be banded by nonabsorbable sutures, small caliber interposition grafts, or by narrowing the vein with a tight Dacron or PTFE cuff (14). In prosthetic accesses, interposition of a short tapered graft segment has also been suggested in the literature (16–18,22,23). An accurate physical examination of the AVF is essential for early diagnosis and timely referral of the patient is necessary to prevent complications (1). We used arterial pressure-controlled PTFE banding and constriction with polypropylene suturing techniques in our patients, in parallel with the literature findings. We are of the opinion that synthetic PTFE graft binding method has more favorable results than the polypropylene suturing method. However, the patient's vascular structure has an important role.

In conclusion, we think that arterial pressure-controlled surgical revision is an effective and safe technique in patients with arteriovenous fistula-related hand ischemia. This technique also has the advantage of saving veins, which, of course, is worthwhile in patients under hemodialysis treatment.

References

1. Shah R, Bhatt UY, Cleef SV, Farley M, Davis A, Swope M, Agarwal AK. Vascular access thrombosis and interventions in patients missing haemodialysis sessions. *Clin Nephrol* 2011; 76: 435–439.
2. Shah R, Vachharajani TJ, Agarwal AK. Aneurysmal dilatation of dialysis arteriovenous access. *Open Urology & Nephrology Journal* 2013; 6: 1–5.
3. Fokou M, Teyang A, Ashuntantang G, Kaze F, Eyenga VC, Chichom Mefire A, Angwafo F 3rd. Complications of arteriovenous fistula for hemodialysis: an 8-year study. *Ann Vasc Surg* 2012; 26: 680–684.
4. Rogers NM, Lawton PD. Ischaemic monomelic neuropathy in a non-diabetic patient following creation of an upper limb arteriovenous fistula. *Nephrol Dial Transplant* 2006; 22: 933–935.
5. Tordoir JH, Dammers R, van der Sande FM. Upper extremity ischaemia and hemodialysis vascular access. *Eur J Vasc Endovasc Surg* 2004; 27: 1–5.
6. Schanzer H, Eisenberg D. Management of steal syndrome resulting from dialysis access. *Semin Vasc Surg* 2004; 17: 45–49.
7. Ravani P, Spergel LM, Asif A, Roy-Chaudhury P, Besarab A. Clinical epidemiology of arteriovenous fistula in 2007. *J Nephrol* 2007; 20: 141–149.
8. Leon C, Asif A. Arteriovenous access and hand pain: the distal hypoperfusion ischemic syndrome. *Clin J Am Soc Nephrol* 2007; 2: 175–183.
9. Regalado S, Navuluri R, Vikingstad E. Distal revascularization and interval ligation: a primer for the vascular and interventional radiologist. *Semin Intervent Radiol* 2009; 26: 125–129.
10. Spergel LM, Ravani P, Roy-Chaudhury P, Asif A, Besarab A. Surgical salvage of the autogenous arteriovenous fistula (AVF). *J Nephrol* 2007; 20: 388–398.
11. Stolic RV, Mijailovic MZ, Cvetkovic AM, Stanojevic MS, Stolic DZ, Cvetkovic DM. Distal ischemia induced by vascular access for hemodialysis—a case report. *Hippokratia* 2012; 16: 375–377.
12. Zanow J, Kruger U, Scholz H. Proximalization of the arterial inflow: a new technique to treat access-related ischemia. *J Vasc Surg* 2006; 43: 1216–1221.
13. Asif A. Nephrologists and interventional nephrology. *Dialysis Transplant* 2010; 39: 476–480.
14. Mickley V. Steal syndrome—strategies to preserve vascular access and extremity. *Nephrol Dial Transplant* 2008; 23: 19–24.
15. Wixon CL, Mills JL, Berman SS. Distal revascularization-interval ligation for maintenance of dialysis access and restoration of distal perfusion in ischemic steal syndrome. *Semin Vasc Surg* 2000; 13: 77–82.

16. DeCaprio JD, Valentine RJ, Kakish HB, Awad R, Hagino RT, Clagett GP. Steal syndrome complicating hemodialysis access. *Cardiovasc Surg* 1997; 5: 648–653.
17. Morsy AH, Kulbaski M, Chen C, Isiklar H, Lumsden AB. Incidence and characteristics of patients with hand ischaemia after a hemodialysis access procedure. *J Surg Res* 1998; 74: 8–10.
18. Odland MD, Kelly PH, Ney AL, Anderson RC, Bubrick MP. Management of dialysis associated steal syndrome complicating upper extremity arteriovenous fistulas: use of intraoperative digital photoplethysmography. *Surgery* 1991; 110: 664–669.
19. van Hoek F, Scheltinga M, Luirink M, Pasmans H, Beerenhout C. Banding of hemodialysis access to treat hand ischemia or cardiac overload. *Semin Dial* 2009; 22: 204–208.
20. Hastaoğlu IA, Parlar H, Toköz H, Bilgen F. Ischemic syndrome due to distal hypoperfusion in hemodialysis arteriovenous fistulas. *Turkish J Thorac Cardiovasc Surg* 2013; 21: 936–943 (in Turkish with English abstract).
21. Özbek İC, Kocailik A, Sever K, Mansuroğlu D. Treatment of dialysis access-associated steal syndrome with pressure monitorization-assisted PTFE banding. *Turkish J Thorac Cardiovasc Surg* 2011; 19: 182–185 (in Turkish with English abstract).
22. Meyer F, Muller JS, Grote R, Halloul Z, Lippert H, Bürger T. Fisteldrosselung-erfolgversprechendes Konzept bei peripherer Minderperfusion. *Zentralbl Chir* 2002; 127: 685–688 (in German).
23. Rivers SP, Scher LA, Veith FJ. Correction of steal syndrome secondary to hemodialysis fistulas: a simplified quantitative technique. *Surgery* 1992; 112: 593–597.