

1-1-2015

## Age-related macular degeneration and Alzheimer disease

EREN ÇERMAN

MUHSİN ERASLAN

OSMAN ÇEKİÇ

Follow this and additional works at: <https://journals.tubitak.gov.tr/medical>



Part of the [Medical Sciences Commons](#)

---

### Recommended Citation

ÇERMAN, EREN; ERASLAN, MUHSİN; and ÇEKİÇ, OSMAN (2015) "Age-related macular degeneration and Alzheimer disease," *Turkish Journal of Medical Sciences*: Vol. 45: No. 5, Article 3. <https://doi.org/10.3906/sag-1406-146>

Available at: <https://journals.tubitak.gov.tr/medical/vol45/iss5/3>

This Article is brought to you for free and open access by TÜBİTAK Academic Journals. It has been accepted for inclusion in Turkish Journal of Medical Sciences by an authorized editor of TÜBİTAK Academic Journals. For more information, please contact [academic.publications@tubitak.gov.tr](mailto:academic.publications@tubitak.gov.tr).

## Age-related macular degeneration and Alzheimer disease

Eren ÇERMAN, Muhsin ERASLAN, Osman ÇEKİÇ\*

Department of Ophthalmology, Faculty of Medicine, Marmara University, İstanbul, Turkey

Received: 30.06.2014 • Accepted/Published Online: 14.03.2015 • Printed: 30.10.2015

**Abstract:** This review highlight the similarities in the pathogenesis between Alzheimer disease and age-related macular degeneration. All studies published between 1990 and 2014 were reviewed to identify the common pathological pathways. Alzheimer disease and age-related macular degeneration share common features such as vitronectin and amyloid- $\beta$  accumulation, increased oxidative stress, and apolipoprotein and complement activation pathways, which are reviewed as histologic and immunologic common features.

**Key words:** Age-related macular degeneration, Alzheimer disease, amyloid- $\beta$ , drusen, senile plaques

### 1. Introduction

Epidemiological studies have shown an increased comorbidity with glaucoma and Alzheimer disease (1,2). As the pathophysiology of these two neurodegenerative diseases is better understood, some authors have described glaucoma as 'ocular Alzheimer disease' (3) and others have called it 'cerebral glaucoma' (4). Age-related macular degeneration (AMD) is another ocular pathology that shares many similarities with Alzheimer disease. Degenerative diseases share common immune mechanisms (5). Similar to Alzheimer disease, AMD is a neurodegenerative disease. The two share common risk factors, such as aging, obesity, atherosclerosis, hypertension, and smoking, which induce cellular aging (6). They also share common histologic and molecular features and pathogenic pathways; therefore, some authors have called AMD 'Alzheimer disease in the eye' (7). Because the world population has aged significantly over the last century, the importance of both diseases has increased. Understanding the common mechanisms may provide new insights into Alzheimer disease and AMD pathogenesis and treatment. In this review, we aimed to highlight the common histologic, immunologic, and pathogenetic features of both diseases and to evaluate risk factors, such as aging, from this point of view.

### 2. Histologic and immunologic similarities

Drusen are yellow or white extracellular deposits beneath the retinal pigment epithelium. The size and number of the drusen and the degree of their confluence are significant risk factors for AMD (8). Drusen are characteristic of AMD but not uniquely associated with it.

Alzheimer disease, on the other hand, is histopathologically characterized by amyloid- $\beta$ -containing senile plaques and amyloid-induced tau-containing neurofibrillary tangles (9).

Both diseases share common molecular constituents, such as amyloid- $\beta$ , vitronectin, apolipoprotein E, complement components, and inflammatory mediators, in their specific histologic hallmarks of drusen and senile plaques (10).

#### 2.1. Amyloid- $\beta$

The amyloid- $\beta$  precursor protein is a glycoprotein in the membrane of neuronal cells. It has an extracellular N-terminal and an intracellular C-terminal domain. Both domains play important roles in neuronal growth and regeneration. In processing, the amyloid- $\beta$  precursor protein is cleaved with either  $\alpha$ -secretase (the nonamyloidogenic pathway) or  $\beta$ -secretase (the amyloidogenic pathway). When amyloid- $\beta$  precursor protein is cleaved first by  $\beta$ -secretase and then by  $\gamma$ -secretase, a soluble amyloid- $\beta$  results.

Soluble amyloid- $\beta$  circulates in plasma and cerebrospinal fluid mainly as the amyloid- $\beta$  40 variant (11). The soluble concentrations of the main two variants of amyloid- $\beta$  40 and 42 are predictors of Alzheimer disease (12). For both variants, rapid endocytosis occurs with retention in the lysosomes, where the accumulation may lead to aggregation and amyloid formation (13). Under normal conditions, amyloid- $\beta$  is immediately degraded by peptidases (14). In senile plaques, amyloid- $\beta$  40 and 42 accumulation occurs in the form of insoluble amyloid fibrils (15). Amyloid formation is not specific

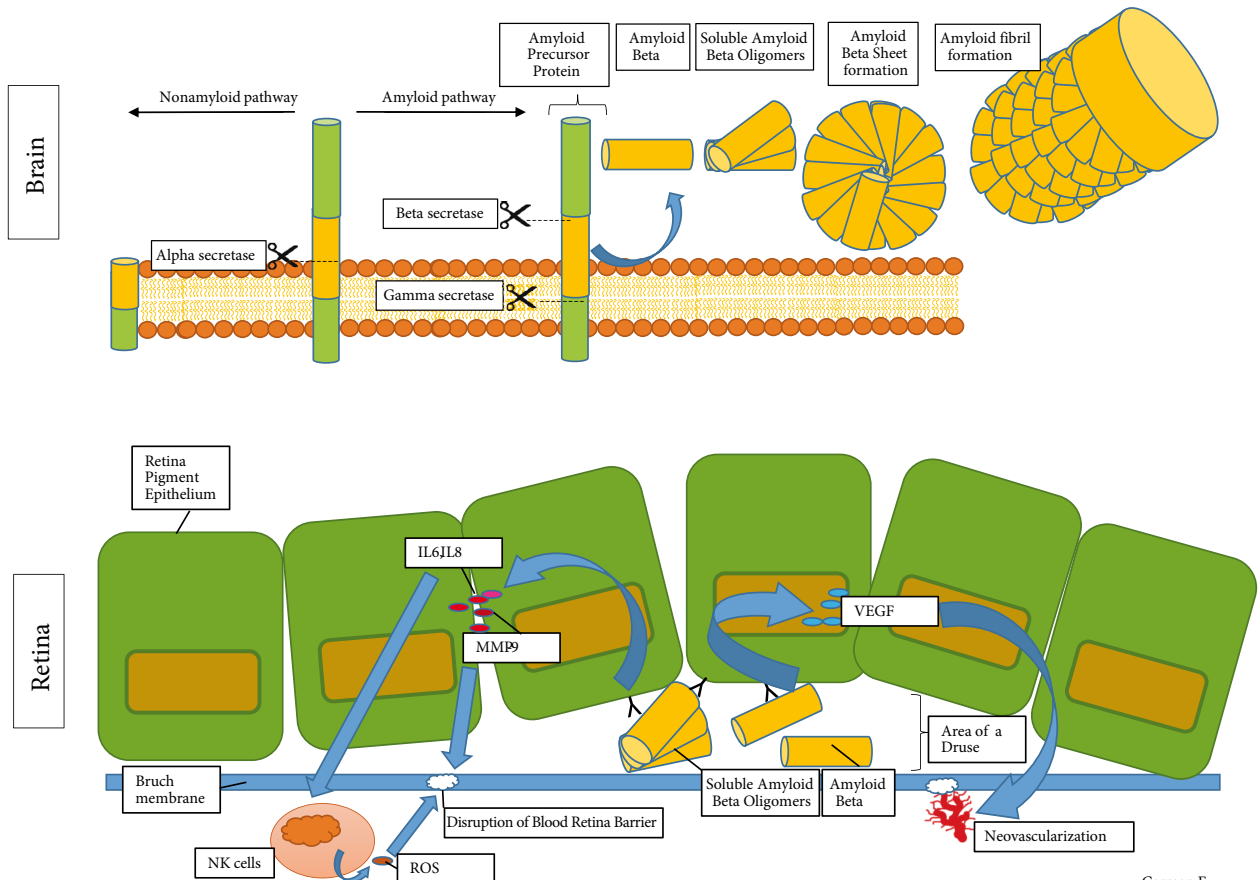
\* Correspondence: ocekic@hotmail.com

for Alzheimer disease; systemic amyloidosis, maturity onset diabetes, Lewy bodies of Parkinson disease, and transmissible spongiform encephalopathy are examples of other diseases where depositions of normally soluble proteins accumulate as insoluble amyloid fibrils (16). How the amyloid fibrils form from soluble amyloid- $\beta$  is not known, and the field of structural studies on this issue is highly complex (17). Briefly, the process is a molecular multistep misfolding cascade where monomeric oligomers build up the  $\beta$  sheet structures, which eventually convert to amyloid fibrils (18,19) (Figure). Amyloid fibrils are longitudinal structures 6–15 nm wide (20). They are stained with thioflavin T and Congo red.

Amyloid- $\beta$  is also accumulated in the drusen, but histologically is not longitudinally arranged in fibrils, which is characteristic of senile plaques (21). Because the drusen do not contain the fibrillar amyloidosis, AMD is not generally considered an amyloid-deposit disease (10). Luibl et al. immunologically showed that the drusen contain mainly the nonfibrillar amyloidogenic oligomers (22). Nonfibrillar oligomers are the common link in

amyloid diseases and play a role in the initial stage of amyloid fibril deposition (23). WO antibodies, which are specifically reactive in mature amyloid fibrils, are also reactive in vesicular drusen; even fibril formation was visualized in small amounts with electron microscopy (10). Amyloid- $\beta$  accumulation is most common at the edge of geographic atrophies in AMD, where further degeneration mostly occurs (24).

The blood–retinal barrier is a barrier located at two levels: the inner barrier is the nonfenestrated capillaries of the retinal vessels, and the outer barrier is the tight junctions of the retinal pigment epithelium. It plays an important role in the pathogenesis of AMD (25). Amyloid- $\beta$  42 oligomers that have accumulated with age cause chronic inflammation and are speculated as the primary cause of blood–retinal barrier dysfunction (26). Retinal pigment epithelium cells express the amyloid precursor protein and  $\alpha$ - and  $\beta$ -secretase. They also react to amyloid- $\beta$  with increased vascular endothelial growth factor and pigment epithelium-derived factor secretion, which are important in the angiogenic mechanisms of AMD (27).



Çerman E.

**Figure.** The schematization of amyloid- $\beta$  fibril formation in the brain in Alzheimer disease and the mechanisms of amyloid- $\beta$  inducing age-related macular degeneration. IL, Interleukin; MMP-9, matrix metalloproteinase-9 (also known as type IV collagenase); VEGF, vascular endothelial growth factor; ROS, reactive oxygen species; NK cells; natural killer cells.

## 2.2. Oxidative stress

The fundamental mechanism of aging is oxidative stress (28). Oxidative stress is hypothesized to occur due to unstable free radicals called reactive oxygen species. The main effect of reactive oxygen species is damage.

In the pathogenesis of both AMD and Alzheimer disease, oxidative stress and the immunologic mechanisms triggered by it are causative (29–31).

One of the mechanisms that lead to oxidative stress is hypoxia. The organs with increased oxygen demand are more prone to hypoxia and, therefore, oxidative stress. The brain and retinas are the most energy-consuming organs (32).

Choroidal blood flow is decreased in AMD (33). Similarly, cerebral blood flow is 20% lower in patients with Alzheimer disease than in age-matched controls (34). Cerebral atherosclerosis is correlated with Alzheimer disease (35).

Reactive oxygen species oxidize the lipids in the membranes of intracellular  $Ca^{+}$ -signaling pathways. Oxidative stress reduces the  $\alpha$ -amylase pathway, which is also the nonamyloid pathway, thereby increasing the  $\beta$ -amyloidase pathway and resulting in increased amyloid- $\beta$  production (36).

Earlier studies showed that protein oxidation products, such as carbonyls and 3-nitrotyrosine, and oxidative damage markers are increased in Alzheimer disease. Recent reviews claimed that accumulating evidence shows that the key factor in Alzheimer disease is oxidative stress (30,37).

With aging, mitochondrial damage occurs due to prolonged oxidative stress, which activates nitric oxide synthase and the formation of reactive oxygen species. This contributes to disruption of the blood–brain barrier (37,38).

Superoxide dismutase is one of the major antioxidant metalloenzymes. Superoxide dismutase 1 (copper-zinc-superoxide dismutase) is found in the cytosol, nucleus, and mitochondrial intermembrane, whereas superoxide dismutase 2 is in the mitochondrial matrix and superoxide dismutase 3 is in the extracellular matrix. Mice deficient in superoxide dismutase 1 are more prone to develop Alzheimer disease, and patients with Alzheimer disease have lower levels of superoxide dismutase 1 (39). It is thought that superoxide dismutase 1 deficiency leads to increased cytoplasmic superoxide radicals, which, in turn, change the conformation of amyloid- $\beta$  oligomers to facilitate the formation of amyloid fibrils.

Similar to Alzheimer disease, oxidative damage is responsible for the pathogenesis of AMD, and superoxide dismutase 1 also plays a major role (31,40).

Superoxide dismutase 1 is also a significant contributor in the pathogenesis of AMD. Plasma malondialdehyde and nitric oxide levels are increased in AMD, which is indicative of oxidative damage (41). Mice deficient in superoxide dismutase 1 develop the typical pathology of AMD when they age and are exposed to light, therefore serving as valuable models for AMD (42).

## 2.3. Vitronectin

Vitronectin is an acute phase reactant and a plasma protein that is toxic to neuroblastoma cells and the retinal pigment epithelium. It is found abundantly in drusen (43). The binding of vitronectin to the Bruch membrane blocks the transmission of metabolites between the choriocapillaris and retinal pigment epithelium, which eventually leads to degeneration of retinal pigment epithelium (44).

Vitronectin is also deposited in other age-related diseases, such as dense deposit disease (45), amyloidosis (46), and Alzheimer disease (47). Previously, it was shown that an antibody to vitronectin strongly stained the Alzheimer brain, whereas it weakly stained the control brain. However, the senile plaques in Alzheimer disease have microglia with strongly positive receptors for vitronectin (48). Recent studies show that it may contribute to the formation of amyloid oligomers and fibrils (43).

## 2.4. Apolipoproteins and lipid metabolism

Apolipoproteins are proteins that bind and help transport lipids in the blood. The products of this process of binding to lipids are called lipoproteins. Cholesterol is an essential fat that provides support for cell membranes. In blood, it is transported mainly as low-density lipoprotein (LDL). Apolipoprotein E and apolipoprotein B are the apolipoproteins that bind to LDL and serve in the body as ligands for the receptor-mediated endocytosis of LDL. Esterified cholesterol is the main component of the lipid-containing part of drusen, which occupies 37%–44% of the druse volume (49). Apolipoprotein B has a central role in atherosclerosis (50). Accumulating evidence suggests that pathological lipid profiles are a significant factor in late-onset Alzheimer disease; hypercholesterolemia, increased LDL, and overexpression of apolipoprotein B are independent risk factors for Alzheimer disease (51). The *ApoE* gene is polymorphic with three major isoforms: apolipoprotein E2, E3, and E4 (52). The strongest genetic risk factor for Alzheimer disease is the E4 variant of apolipoprotein E (53). Immunologic stainings reveal apolipoprotein E, B, and cholesterol accumulation in the Bruch membrane, the drusen, and basal deposits at the retinal pigment epithelium (54).

Aged mice of the transgenic mouse model that expresses human apolipoprotein E4 are strongly associated with Alzheimer disease. When these mice are aged over 1 year and fed with a high-fat diet, they develop the pathological

features of AMD, and the pathology is attenuated if anti-amyloid- $\beta$  antibodies are present (55).

### 2.5. Complement activation

Complement activation is an important process where cellular debris and microorganisms are removed and immune complexes are processed. It is known that complement activation is overtriggered in Alzheimer disease on amyloid- $\beta$  and neurofibrillary tangles (56). Amyloid- $\beta$  is shown to block C3b from inactivation, so that an uncontrolled complement activation results (26).

Complement activation also plays an important role in the development of drusen and choroidal neovascularization (57). Many complement proteins and immune complexes are identified in the drusen (58–60). Specifically, C5, C5b9, and C3 fragments are observed in the drusen. The finding of the colocalizing of amyloid- $\beta$  with these activated complements at the same amyloid vesicles in the drusen point to a common immunomodulatory pathway in Alzheimer disease and AMD (61). The inadequate activation of an alternative pathway in the complement cascade system leads to sustained activation of complements and continued formation of drusen. The complement factor H gene, which is the inhibitor of C3, was found to be strongly associated with AMD (62). Taken together, the complement system and amyloid- $\beta$  may lead to pathological mechanisms in AMD.

## References

1. Bayer AU, Ferrari F, Erb C. High occurrence rate of glaucoma among patients with Alzheimer's disease. *Eur Neurol* 2002; 47: 165–168.
2. Tamura H, Kawakami H, Kanamoto T, Kato T, Yokoyama T, Sasaki K, Izumi Y, Matsumoto M, Mishima HK. High frequency of open-angle glaucoma in Japanese patients with Alzheimer's disease. *J Neurol Sci* 2006; 246: 79–83.
3. McKinnon SJ. Glaucoma: ocular Alzheimer's disease? *Front Biosci* 2003; 8: s1140–1156.
4. Wostyn P, Audenaert K, De Deyn PP. Alzheimer's disease: cerebral glaucoma? *Med Hypotheses* 2010; 74: 973–977.
5. McGeer PL, McGeer EG. Innate immunity, local inflammation, and degenerative disease. *Sci STKE* 2002; 2002: re3.
6. Nussenblatt RB, Liu B, Wei L, Sen HN. The immunological basis of degenerative diseases of the eye. *Int Rev Immunol* 2013; 32: 97–112.
7. Kaarniranta K, Salminen A, Haapasalo A, Soininen H, Hiltunen M. Age-related macular degeneration (AMD): Alzheimer's disease in the eye? *J Alzheimers Dis* 2011; 24: 615–631.
8. Pauleikhoff D. Drusen in Bruch's membrane. Their significance for the pathogenesis and therapy of age-associated macular degeneration. *Ophthalmologie* 1992; 89: 363–386 (in German with English abstract).
9. Gotz J, Schild A, Hoerndli F, Pennanen L. Amyloid-induced neurofibrillary tangle formation in Alzheimer's disease: insight from transgenic mouse and tissue-culture models. *Int J Dev Neurosci* 2004; 22: 453–465.
10. Isas JM, Luibl V, Johnson LV, Kaye R, Wetzel R, Glabe CG, Langen R, Chen J. Soluble and mature amyloid fibrils in drusen deposits. *Invest Ophthalmol Vis Sci* 2010; 51: 1304–1310.
11. Hartmann T, Bieger SC, Bruhl B, Tienari PJ, Ida N, Allsop D, Roberts GW, Masters CL, Dotti CG, Unsicker K et al. Distinct sites of intracellular production for Alzheimer's disease A $\beta$  40/42 amyloid peptides. *Nature Med* 1997; 3: 1016–1020.
12. Lue LF, Kuo YM, Roher AE, Brachova L, Shen Y, Sue L, Beach T, Kurth JH, Rydel RE, Rogers J. Soluble amyloid beta peptide concentration as a predictor of synaptic change in Alzheimer's disease. *Am J Pathol* 1999; 155: 853–862.
13. Esbjornner EK, Chan F, Rees E, Erdelyi M, Luheshi LM, Bertoncini CW, Kaminski CF, Dobson CM, Kaminski Schierle GS. Direct observations of amyloid  $\beta$  self-assembly in live cells provide insights into differences in the kinetics of A $\beta$ (1-40) and A $\beta$ (1-42) aggregation. *Chem Biol* 2014; 732–742.

## 3. Epidemiology

More than 25 million people in the world are affected by dementia, and most of them also have Alzheimer disease (63). Both diseases share the same common risk factors: smoking, obesity, and high dietary glycemic index (64–66). They also share some common genetic mechanisms and other mechanisms that have been highlighted in this review (67), but the coexistence of both AMD and Alzheimer disease in the same patient is not different from what is expected by chance, which points to the importance of the common environmental risk factors (68).

## 4. Conclusion

Because of the increasing age of the population, it has become more important to understand the mechanisms of aging. Addressing the common mechanisms of aging that lead to 2 different diseases might help to identify new therapeutic approaches. As an example, the treatment modalities that have targeted Alzheimer disease might also be applied to AMD. Immunotherapy targeting amyloid- $\beta$  has been proven effective in protecting the retinal pigment epithelium (69,70). Apolipoprotein E, which is speculated to rapidly degrade amyloid- $\beta$  and reverse the effects of Alzheimer disease, may be targeted for the degradation of the drusen in AMD. Nutritional antioxidant supplements for both diseases are effective in delaying both diseases. Other mechanisms highlighted in this review may be the targets of new treatment modalities in the near future.

14. Iwata N, Takaki Y, Fukami S, Tsubuki S, Saido TC. Region-specific reduction of A $\beta$ -degrading endopeptidase, neprilysin, in mouse hippocampus upon aging. *J Neurosci Res* 2002; 70: 493–500.
15. Perez-Garmendia R, Gevorkian G. Pyroglutamate-modified amyloid beta peptides: emerging targets for Alzheimer's disease immunotherapy. *Curr Neuropharmacol* 2013; 11: 491–498.
16. Sunde M, Serpell LC, Bartlam M, Fraser PE, Pepys MB, Blake CC. Common core structure of amyloid fibrils by synchrotron X-ray diffraction. *J Mol Biol* 1997; 273: 729–739.
17. Serpell LC. Alzheimer's amyloid fibrils: structure and assembly. *Biochim Biophys Acta* 2000; 1502: 16–30.
18. Reixach N, Dechongkit S, Jiang X, Kelly JW, Buxbaum JN. Tissue damage in the amyloidoses: transthyretin monomers and nonnative oligomers are the major cytotoxic species in tissue culture. *P Natl Acad Sci USA* 2004; 101: 2817–2822.
19. Kaye R, Sokolov Y, Edmonds B, McIntire TM, Milton SC, Hall JE, Glabe CG. Permeabilization of lipid bilayers is a common conformation-dependent activity of soluble amyloid oligomers in protein misfolding diseases. *J Biol Chem* 2004; 279: 46363–46366.
20. Sunde M, Blake C. The structure of amyloid fibrils by electron microscopy and X-ray diffraction. *Adv Protein Chem* 1997; 50: 123–159.
21. Anderson DH, Talaga KC, Rivest AJ, Barron E, Hageman GS, Johnson LV. Characterization of  $\beta$  amyloid assemblies in drusen: the deposits associated with aging and age-related macular degeneration. *Exp Eye Res* 2004; 78: 243–256.
22. Luibl V, Isas JM, Kaye R, Glabe CG, Langen R, Chen J. Drusen deposits associated with aging and age-related macular degeneration contain nonfibrillar amyloid oligomers. *J Clin Invest* 2006; 116: 378–385.
23. Kaye R, Head E, Thompson JL, McIntire TM, Milton SC, Cotman CW, Glabe CG. Common structure of soluble amyloid oligomers implies common mechanism of pathogenesis. *Science* 2003; 300: 486–489.
24. Dentchev T, Milam AH, Lee VM, Trojanowski JQ, Dunaief JL. Amyloid-beta is found in drusen from some age-related macular degeneration retinas, but not in drusen from normal retinas. *Mol Vision* 2003; 9: 184–190.
25. Jo DH, Kim JH, Kim JH. How to overcome retinal neuropathy: the fight against angiogenesis-related blindness. *Arc Pharmacol Res* 2010; 33: 1557–1565.
26. Wang J, Ohno-Matsui K, Yoshida T, Kojima A, Shimada N, Nakahama K, Safranov O, Iwata N, Saido TC, Mochizuki M et al. Altered function of factor I caused by amyloid  $\beta$ : implication for pathogenesis of age-related macular degeneration from Drusen. *J Immunol* 2008; 181: 712–720.
27. Yoshida T, Ohno-Matsui K, Ichinose S, Sato T, Iwata N, Saido TC, Hisatomi T, Mochizuki M, Morita I. The potential role of amyloid beta in the pathogenesis of age-related macular degeneration. *J Clin Invest* 2005; 115: 2793–2800.
28. Harman D. Aging: a theory based on free radical and radiation chemistry. *J Gerontol* 1956; 11: 298–300.
29. Perry G, Cash AD, Smith MA. Alzheimer disease and oxidative stress. *J Biomed Biotechnol* 2002; 2: 120–123.
30. Kosenko EA, Solomadin IN, Tikhonova LA, Reddy VP, Aliev G, Kaminsky YG. Pathogenesis of Alzheimer disease: role of oxidative stress, amyloid-beta peptides, systemic ammonia and erythrocyte energy metabolism. *CNS Neurol Disord Drug Targets* 2014; 13: 112–119.
31. Yildirim Z, Ucgun NI, Yildirim F. The role of oxidative stress and antioxidants in the pathogenesis of age-related macular degeneration. *Clinics (Sao Paulo)* 2011; 66: 743–746.
32. Yu DY, Cringle SJ. Retinal degeneration and local oxygen metabolism. *Exp Eye Res* 2005; 80: 745–751.
33. Remsch H, Spraul CW, Lang GK, Lang GE. Changes of retinal capillary blood flow in age-related maculopathy. *Graefes Arch Clin Exp Ophthalmol* 2000; 238: 960–964.
34. Roher AE, Debbins JP, Malek-Ahmadi M, Chen K, Pipe JG, Maze S, Belden C, Maarouf CL, Thiyyagura P, Mo H et al. Cerebral blood flow in Alzheimer's disease. *Vasc Health Risk Manag* 2012; 8: 599–611.
35. Dolan H, Crain B, Troncoso J, Resnick SM, Zonderman AB, O'Brien RJ. Atherosclerosis, dementia, and Alzheimer disease in the Baltimore Longitudinal Study of Aging cohort. *Ann Neurol* 2010; 68: 231–240.
36. Zhao Y, Zhao B. Oxidative stress and the pathogenesis of Alzheimer's disease. *Oxid Med Cell Longev* 2013; 2013: 316523.
37. Aliev G, Priyadarshini M, Reddy VP, Grieg NH, Kaminsky Y, Cacabelos R, Ashraf GM, Jabir NR, Kamal MA, Nikolenko VN et al. Oxidative stress mediated mitochondrial and vascular lesions as markers in the pathogenesis of Alzheimer disease. *Curr Med Chem* 2014; 21: 2208–2217.
38. Aliev G, Obrenovich ME, Tabrez S, Jabir NR, Reddy VP, Li Y, Burnstock G, Cacabelos R, Kamal MA. Link between cancer and Alzheimer disease via oxidative stress induced by nitric oxide-dependent mitochondrial DNA overproliferation and deletion. *Oxid Med Cell Longev* 2013; 2013: 962984.
39. Murakami K, Murata N, Noda Y, Tahara S, Kaneko T, Kinoshita N, Hatsuta H, Murayama S, Barnham KJ, Irie K et al. SOD1 (copper/zinc superoxide dismutase) deficiency drives amyloid beta protein oligomerization and memory loss in mouse model of Alzheimer disease. *J Biol Chem* 2011; 286: 44557–44568.
40. Drobek-Slowik M, Karczewicz D, Safranow K. The potential role of oxidative stress in the pathogenesis of the age-related macular degeneration (AMD). *Postepy Hig Med Dosw (Online)* 2007; 61: 28–37.
41. Totan Y, Çekiç O, Borazan M, Uz E, Sogut S, Akyol O. Plasma malondialdehyde and nitric oxide levels in age related macular degeneration. *Br J Ophthalmol* 2001; 85: 1426–1428.
42. Imamura Y, Noda S, Hashizume K, Shinoda K, Yamaguchi M, Uchiyama S, Shimizu T, Mizushima Y, Shirasawa T, Tsubota K. Drusen, choroidal neovascularization, and retinal pigment epithelium dysfunction in SOD1-deficient mice: a model of age-related macular degeneration. *P Natl Acad Sci USA* 2006; 103: 11282–11287.
43. Shin TM, Isas JM, Hsieh CL, Kaye R, Glabe CG, Langen R, Chen J. Formation of soluble amyloid oligomers and amyloid fibrils by the multifunctional protein vitronectin. *Mol Neurodegener* 2008; 3: 16.

44. Pauleikhoff D, Zuels S, Sheraidah GS, Marshall J, Wessing A, Bird AC. Correlation between biochemical composition and fluorescein binding of deposits in Bruch's membrane. *Ophthalmology* 1992; 99: 1548–1553.
45. Jansen JH, Hogasen K, Mollnes TE. Extensive complement activation in hereditary porcine membranoproliferative glomerulonephritis type II (porcine dense deposit disease). *Am J Pathol* 1993; 143: 1356–1365.
46. Dahlback K, Wulf HC, Dahlback B. Vitronectin in mouse skin: immunohistochemical demonstration of its association with cutaneous amyloid. *J Invest Dermatol* 1993; 100: 166–170.
47. Kiddle SJ, Thambisetty M, Simmons A, Riddoch-Contreras J, Hye A, Westman E, Pike I, Ward M, Johnston C, Lupton MK et al. Plasma based markers of [<sup>11</sup>C] PiB-PET brain amyloid burden. *PLoS One* 2012; 7: e44260.
48. Akiyama H, Kawamata T, Dedhar S, McGeer PL. Immunohistochemical localization of vitronectin, its receptor and beta-3 integrin in Alzheimer brain tissue. *J Neuroimmunol* 1991; 32: 19–28.
49. Wang L, Clark ME, Crossman DK, Kojima K, Messinger JD, Mobley JA, Curcio CA. Abundant lipid and protein components of drusen. *PLoS One* 2010; 5: e10329.
50. Olofsson SO, Boren J. Apolipoprotein B: a clinically important apolipoprotein which assembles atherogenic lipoproteins and promotes the development of atherosclerosis. *J Int Med* 2005; 258: 395–410.
51. Löffler T, Flunkert S, Havas D, Santha M, Hutter-Paier B, Steyrer E, Windisch M. Impact of ApoB-100 expression on cognition and brain pathology in wild-type and hAPPs1 mice. *Neurobiol Aging* 2013; 34: 2379–2388.
52. Eisenberg DT, Kuzawa CW, Hayes MG. Worldwide allele frequencies of the human apolipoprotein E gene: climate, local adaptations, and evolutionary history. *Am J Phys Anthropol* 2010; 143: 100–111.
53. Percy M, Somerville MJ, Hicks M, Garcia A, Colelli T, Wright E, Kitaygorodsky J, Jiang A, Ho V, Parpia A et al. Risk factors for development of dementia in a unique six-year cohort study. I. An exploratory, pilot study of involvement of the E4 allele of apolipoprotein E, mutations of the hemochromatosis-HFE gene, type 2 diabetes, and stroke. *J Alzheimers Dis* 2014; 38: 907–922.
54. Malek G, Li CM, Guidry C, Medeiros NE, Curcio CA. Apolipoprotein B in cholesterol-containing drusen and basal deposits of human eyes with age-related maculopathy. *Am J Pathol* 2003; 162: 413–425.
55. Malek G, Johnson LV, Mace BE, Saloupis P, Schmechel DE, Rickman DW, Toth CA, Sullivan PM, Bowes Rickman C. Apolipoprotein E allele-dependent pathogenesis: a model for age-related retinal degeneration. *P Natl Acad Sci USA* 2005; 102: 11900–11905.
56. Zanjani H, Finch CE, Kemper C, Atkinson J, McKeel D, Morris JC, Price JL. Complement activation in very early Alzheimer disease. *Alzheimer Dis Assoc Disord* 2005; 19: 55–66.
57. Nozaki M, Raisler BJ, Sakurai E, Sarma JV, Barnum SR, Lambris JD, Chen Y, Zhang K, Ambati BK, Baffi JZ et al. Drusen complement components C3a and C5a promote choroidal neovascularization. *P Natl Acad Sci USA* 2006; 103: 2328–2333.
58. Johnson LV, Ozaki S, Staples MK, Erickson PA, Anderson DH. A potential role for immune complex pathogenesis in drusen formation. *Exp Eye Res* 2000; 70: 441–449.
59. Anderson DH, Mullins RF, Hageman GS, Johnson LV. A role for local inflammation in the formation of drusen in the aging eye. *Am J Ophthalmol* 2002; 134: 411–431.
60. Johnson LV, Leitner WP, Staples MK, Anderson DH. Complement activation and inflammatory processes in Drusen formation and age related macular degeneration. *Exp Eye Res* 2001; 73: 887–896.
61. Johnson LV, Leitner WP, Rivest AJ, Staples MK, Radeke MJ, Anderson DH. The Alzheimer's A $\beta$ -peptide is deposited at sites of complement activation in pathologic deposits associated with aging and age-related macular degeneration. *P Natl Acad Sci USA* 2002; 99: 11830–11835.
62. Lin JM, Tsai YY, Wan L, Lin HJ, Tsai Y, Lee CC, Tsai CH, Tsai FJ, Tseng SH. Complement factor H variant increases the risk for early age-related macular degeneration. *Retina* 2008; 28: 1416–1420.
63. Hirtz D, Thurman DJ, Gwinn-Hardy K, Mohamed M, Chaudhuri AR, Zalutsky R. How common are the 'common' neurologic disorders? *Neurology* 2007; 68: 326–337.
64. Chakravarthy U, Wong TY, Fletcher A, Piau E, Evans C, Zlateva G, Buggage R, Pleil A, Mitchell P. Clinical risk factors for age-related macular degeneration: a systematic review and meta-analysis. *BMC Ophthalmol* 2010; 10: 31.
65. Chiu CJ, Milton RC, Gensler G, Taylor A. Association between dietary glycemic index and age-related macular degeneration in nondiabetic participants in the Age-Related Eye Disease Study. *Am J Clin Nutr* 2007; 86: 180–188.
66. Moreira PI. High-sugar diets, type 2 diabetes and Alzheimer's disease. *Curr Opin Clin Nutr Metab Care* 2013; 16: 440–445.
67. Logue MW, Schu M, Vardarajan BN, Farrell J, Lunetta KL, Jun G, Baldwin CT, Deangelis MM, Farrer LA. A search for age-related macular degeneration risk variants in Alzheimer disease genes and pathways. *Neurobiol Aging* 2014; 35: 1510 e1517–1518.
68. Keenan TD, Goldacre R, Goldacre MJ. Associations between age-related macular degeneration, Alzheimer disease, and dementia: record linkage study of hospital admissions. *JAMA Ophthalmol* 2014; 132: 63–68.
69. Ding JD, Lin J, Mace BE, Herrmann R, Sullivan P, Bowes Rickman C. Targeting age-related macular degeneration with Alzheimer's disease based immunotherapies: anti-amyloid-beta antibody attenuates pathologies in an age-related macular degeneration mouse model. *Vis Res* 2008; 48: 339–345.
70. Ding JD, Johnson LV, Herrmann R, Farsiu S, Smith SG, Groelle M, Mace BE, Sullivan P, Jamison JA, Kelly U et al. Anti-amyloid therapy protects against retinal pigmented epithelium damage and vision loss in a model of age-related macular degeneration. *P Natl Acad Sci USA* 2011; 108: E279–287.