

1-1-2005

## The Cuttlefish Backbone: A New Bone Xenograft Material?

ZAFER OKUMUŐ

ÖMER SELİM YILDIRIM

Follow this and additional works at: <https://journals.tubitak.gov.tr/veterinary>



Part of the [Animal Sciences Commons](#), and the [Veterinary Medicine Commons](#)

---

### Recommended Citation

OKUMUŐ, ZAFER and YILDIRIM, ÖMER SELİM (2005) "The Cuttlefish Backbone: A New Bone Xenograft Material?," *Turkish Journal of Veterinary & Animal Sciences*: Vol. 29: No. 5, Article 15. Available at: <https://journals.tubitak.gov.tr/veterinary/vol29/iss5/15>

This Article is brought to you for free and open access by TÜBİTAK Academic Journals. It has been accepted for inclusion in Turkish Journal of Veterinary & Animal Sciences by an authorized editor of TÜBİTAK Academic Journals. For more information, please contact [academic.publications@tubitak.gov.tr](mailto:academic.publications@tubitak.gov.tr).

## The Cuttlefish Backbone: A New Bone Xenograft Material?

Zafer OKUMUŞ

Department of Surgery, Faculty of Veterinary Medicine, Atatürk University, 25700 Erzurum - TURKEY  
E-mail: zokumus@atauni.edu.tr.

Ömer Selim YILDIRIM

Department of Orthopaedic and Traumatology, Faculty of Medicine, Atatürk University, 25700 Erzurum - TURKEY

Received: 16.06.2004

**Abstract:** This experiment was conducted to determine the feasibility of cuttlefish backbone as a new xenograft in the treatment of bone defects and its therapeutic effectiveness. Following the administration of general anaesthesia to 20 one-year-old male New Zealand rabbits, traumatic defective areas (5 mm in diameter) were experimentally induced at the proximal and distal metaphyses of both femurs. These defective areas (n = 80) were randomly assigned to be filled with cuttlefish backbone, spongy bovine graft (SBG), tricalcium phosphate (TCP) and demineralised bone matrix (DBM) in a complete randomised design. At the end of the 30-day postoperative experimental period, bone defects filled with various graft materials were evaluated using macroscopic, radiographic, MRI, and scintigraphic methods and then the rabbits were subjected to euthanasia for histological examination. In response to the application of these graft materials, callus formation was observed in a similar fashion across all defective areas. Moreover, cuttlefish backbone ranked second after spongy bovine graft with respect to osteogenic capacity and the bone repairing process. In conclusion, our preliminary data on callus formation, osteogenic capacity and bone repairing suggest that cuttlefish backbone could be considered an alternative xenograft material in orthopaedic applications.

**Key Words:** Cuttlefish backbone, bone defect, bone xenograft

### Mürekkkep Balığı Sırt kemiği: Yeni Bir Kemik Ksenogreft Materyali?

**Özet:** Bu araştırma, mürekkep balığı sırt kemiğinin, kemik defekti sağaltımında yeni bir ksenogreft olarak kullanılabilirliğini ve tedavi etkinliğini saptamak amacıyla yapıldı. Yirmi adet bir yaşlı erkek Yeni Zelanda tavşanlarına uygulanan genel anesteziyi takiben her iki femur proksimal ve distal metafizlerinde deneysel olarak 5 mm çaplı travmatik defektler oluşturuldu. Tesadüfi parselleme dizaynına göre oluşturulan kemik defektleri (n = 80) mürekkep balığı sırt kemiği, spongyöz sığır kemiği grefti, trikalsiyum fosfat ve demineralize kemik matrisi ile dolduruldu. Otuz günlük postoperatif deneme döneminin sonunda değişik greft materyalleriyle doldurulan kemik defektleri makroskopik, radyografik, MRI ve sintigrafik yöntemlerle incelendi ve sonrasında histolojik inceleme için tavşanlar ötenazi edildi. Bütün defektif bölgelerde greft materyallerine yanıt olarak benzer kallus oluşumu gözlemlendi. Bunun yanı sıra, osteojenik kapasite ve kemik onarımı açısından mürekkep balığı sırt kemiğinin, spongyöz sığır kemiği greftinden sonra ikinci sırada olduğu belirlendi. Sonuç olarak; kallus oluşumu, osteojenik kapasite ve kemik onarımına ilişkin elde edilen ilk veriler, mürekkep balığı sırt kemiğinin ortopedik uygulamalarda alternatif bir ksenogreft materyali olabileceğini göstermektedir.

**Anahtar Sözcükler:** Mürekkep balığı sırt kemiği, kemik defekti, kemik ksenogrefti

### Introduction

After blood, bone is the most commonly transplanted tissue in the body (1). The idea and utilisation of graft materials in bone surgery go back to the 17<sup>th</sup> century. However, discrepancies associated with grafting defective bone tissues made scientists focus on the elucidation of the biopotency of graft materials in relationship to the biology of the bone repairing process during the mid 19<sup>th</sup> century (1-3). Bone grafts are extensively used for

orthopaedic applications including treatment of fractures and non-unions, replenishment of bone loss resulting from tumour or infection, and cases requiring reconstructive procedures such as fusion or joint replacement (1). Various bone graft substitutes including autografts, allografts, xenografts, polymers, ceramics and some metals have been employed to promote bone reunion (3-5). Moreover, the utilisation of these materials as bone grafts may reduce the need for autogenous bone graft, which is available in only limited

quantities and is associated with a considerable morbidity rate (6). An ideal graft substitute should have bioresorbability (7) and osteoconductive capacity (8). It also should be nontoxic and nonimmunogenic to the organism, easy to sterilise (9,10) and not compromise mechanical stability (10-12).

Graft materials have considerable variation in terms of meeting all these criteria mentioned above, and consequently their usage is limited, depending on the case of orthopaedic application (13-16). Although the utilisation of autografts results in significant success in the bone healing process, there are some disadvantages, such as requiring the patient to undergo a second operation and increasing therapeutic costs due to a prolonged hospital stay and extended medicare (1). Therefore, the employment of the allograft and xenograft as an alternative to the autograft has become common in orthopaedic surgery (12,13,16). There are numerous studies comparing the biopotency of allografts such as intramembranous bone graft and demineralised bone graft (4,12,13) and xenografts such as coralline and bovine grafts (17-19) with the autograft available.

The cuttlefish (*Sepia officinalis* L.) is abundant in the Aegean sea (20) and its unique backbone provides rigidity to the body whilst doubling as an efficient buoyancy regulation mechanism in the water (21). The backbone of the common cuttlefish as a xenograft has not been

tested in experimental or clinical studies. The objective of this experiment was to evaluate the feasibility of the cuttlefish backbone as a new bone xenograft and to compare its bone repairing efficiency with that of other commonly used xenografts including demineralised bone matrix (DBM), spongy bovine graft (SBG) and tricalcium phosphate (TCP) in rabbits with induced bone defects.

## Materials and Methods

### Cuttlefish backbone and its processing

Cuttlefish backbone was obtained from a pet store (Figure 1). After sterilisation with ethylene oxide, a lack of contamination in the cuttlefish backbone was corroborated by microbiological and virological examinations.

### Animal, diet and management

Twenty skeletally mature 1-year-old male New Zealand white rabbits weighing 3.5 kg were selected from the Atatürk University Experimental Animal and Research Centre. They were placed in individual cages (60 x 60 x 45 cm) and fed ad libitum a conventional diet formulated to meet their nutrient requirements as assessed by the National Research Council (22). Water was available at all times during the experiment (30 days).




Figure 1. The cuttlefish backbone.

### Surgical intervention for inducing bone defects and graft material

Following a 28-day adaptation period, all rabbits underwent bone surgery. An induction mixture of ketamine hydrochloride 50 mg/kg (Ketalar®, Eczacıbaşı, Lüleburgaz, Turkey) and xylazine hydrochloride 5 mg/kg (Rompun®, Bayer, İstanbul, Turkey) was administered intramuscularly, followed by the maintenance of inhalation anaesthesia using 1.5% to 4% sevoflurane (Sevorane®, Abbott Laboratories, İstanbul, Turkey) volatilised with O<sub>2</sub> and delivered by means of a snout mask.

Under general anaesthesia, the lateral and medial femoral regions of each rabbit were shaved, prepared with povidone iodine antiseptic solution (Poviodeks, Kim-Pa, İstanbul, Turkey) and sterile draped with the rabbit in lateral recumbency. After incising the skin and fascia, the quadriceps muscles were retracted, and the entire femoral diaphysis was exposed. The periosteum was stripped from the bone using a periosteal elevator. Bilateral critical size defects (5 mm width) spanning the proximal and distal metaphyseal regions were created 3 mm from the joint lines in the anterolateral cortex of the femurs. During the bone defect induction, a micro burr with a 5-mm-diameter tip was used while flushing sterile saline to minimise thermal damage.

The defects in the left proximal, the left distal, the right proximal and the right distal areas of the femurs were filled with cuttlefish backbone (Group A) (Figure 2),

DBM (Collograft®, Zimmer, Warsaw, IN, USA) (Group B), SBG (Unilab Surgibone® Spongiosa, Unilab Inc., CA, USA) (Group C) and TCP (Pro Osteon® 500, Interpore Cross, Irvine, CA, USA) (Group D), respectively. Before placing the graft materials, it was ensured that there was no bone residue remaining by irrigation with sterile saline. After that, the periosteum was reflected back over the defective area and the skin was sutured using 3-0 polyglycolic acid suture (Dexon, Sherwood Davis & Geck, St. Louis, MO, USA). Rabbits were intramuscularly injected with 15 mg/kg Diclofenac Na (Dikloron®, Deva, İstanbul, Turkey) and 10 mg/kg Enrofloxacin (Baytril®, Bayer İstanbul, Turkey) during the post-operative period (7 days). The animals were free to move and weight-bear immediately post-operation as tolerated.

### Evaluation procedure and data analysis

On day 30 post-operation, the rabbits were subjected to scintigraphy (23), MRI assessment and radiographic grading as described by Ohgushi et al. (14) in order to compare the bone healing process (Table). In the scintigraphic evaluation, the region of interest (ROI), the proximal and distal metaphyses of the rabbit femurs, was drawn in the bone transplant (BT) area. A mirror image of the ROI in the BT area and its mirror image in the background bone (BB) area were obtained to determine the efficiency of the union process of the graft materials (BT/BB). After obtaining clinical data, the rabbits were sedated by an intramuscular injection of xylazine hydrochloride 5 mg/kg and then euthanised with an



Figure 2. The defects in the left proximal of the femurs filled with cuttlefish backbone.

Table. Histological and radiographic grading score according to Ohgushi et al. (14).

Histologic scoring system	Points	Radiographic scoring system
Nonunion	0	Nonunion
Osteochondral union	1	Possible union
Osseous union	2	Radiographic union
Bone bridge between proximal and distal end	1	Continuous radiodense area over the implant in the defect
Bone formation in the defect	1	Radiodense appearance in the defect
Maximum score	6	Maximum score

intravenous infusion of 2 ml/4.5 kg of sodium thiopental (Pental® Sodium 1 g, İ.E. Ulagay, İstanbul, Turkey). Following a macroscopical evaluation of the femurs for the presence and structure of callus formation, they were harvested for histological evaluation of osteoblastic activity in defective areas filled with the graft materials.

One-way ANOVA was employed in the data analyses using the general linear model procedure in a complete randomised design (SPSS for Windows, release 10.0.0, 1999, Chicago, IL, USA). Group means were compared using the least significant difference (LSD) option and statistical differences were considered significant at  $P < 0.05$ .

**Results**

In comparing with other graft materials, cuttlefish backbone was soft and easy to mold and fill with. Moreover, sterilisation with ethylene oxide was sufficient

to eliminate contamination. During the experimental period, no adverse effects related to inducing bone defects or placing graft materials on general health status were observed.

By means of macroscopic evaluation, significant callus formation was observed in all defective areas in the femurs (Figure 3); this was also detected by means of radiography (Figure 4) and MRI (Figure 5). Scintigraphic evaluation of the regions of interest (ROIs), the proximal and distal metaphyses of the femurs, also corroborated the newly formed callus expressed as the ratio of the BT area to its mirror image in the BB area (Figure 6). SBG had the highest BT:BB ratio, followed by cuttlefish backbone. Moreover, this ratio for Groups A and C continuously increased, whereas that for Groups B and D remained constant as the scintigraphy continued (Figure 6).

Data obtained from histological and radiographic scoring system (Table) were in agreement with those



Figure 3. New callus formed in all defective areas regardless of the graft materials 30 days after placing graft materials.

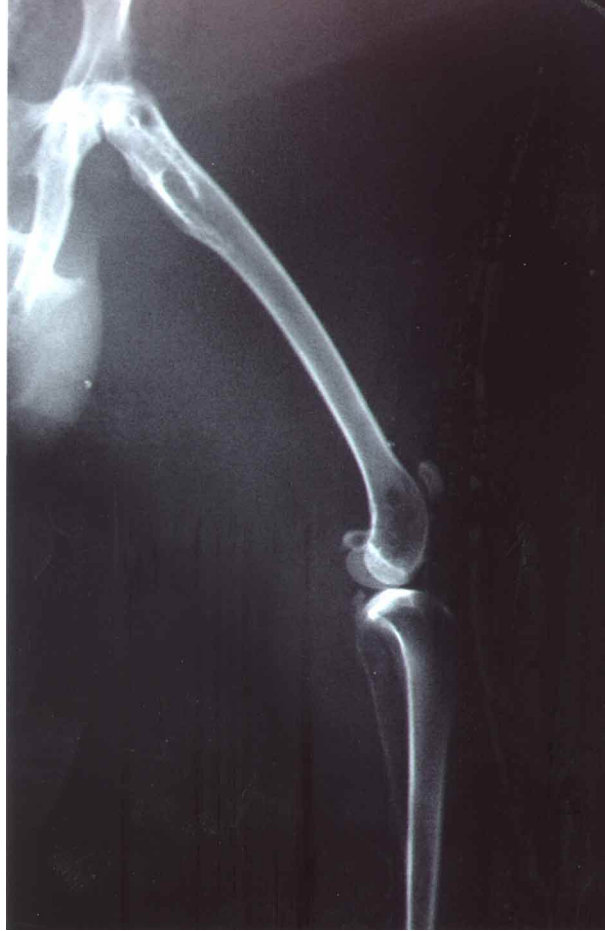

Figure 4. Radiological image of new callus formed in all defective areas regardless of the graft materials 30 days after placing graft materials.

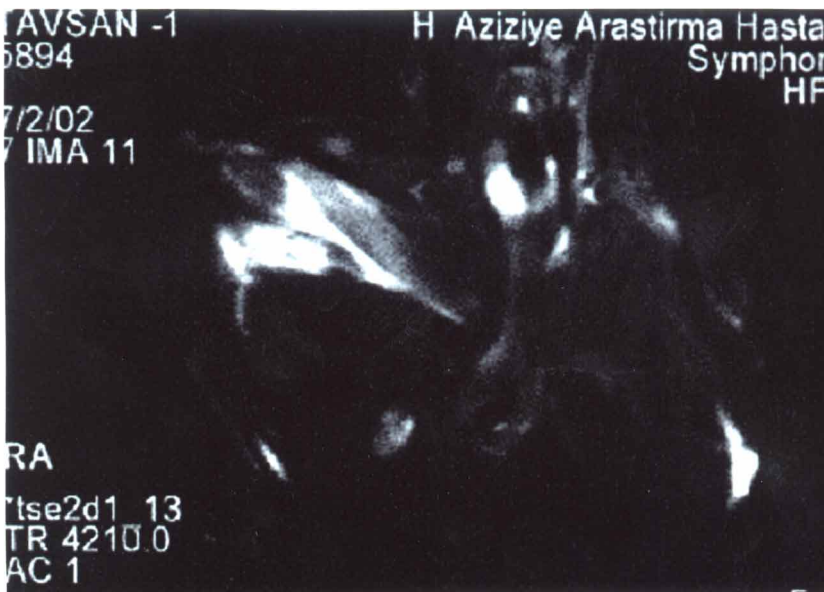

Figure 5. MRI T2 axial image of new callus formed in the left proximal methaphysis of femur.

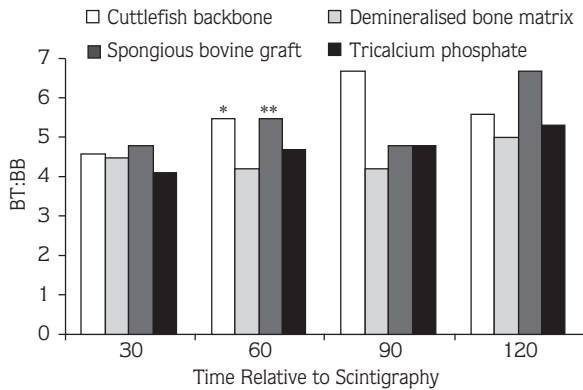


Figure 6. Scintigraphic ratio of graft areas to background areas (mean ± SD).  
 \* P > 0.05 Between Group A and C  
 \*\* P < 0.05 All groups at each time

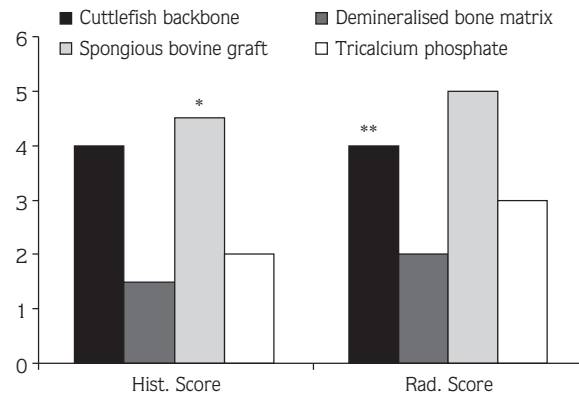


Figure 7. Healing potential of cuttlefish backbone and others graft materials according to Ohgushi et al. (14).  
 \*P > 0.05 Between Group A and C, and Group B and D  
 \*\* P < 0.05 All groups at each time  
 \*P > 0.05 Between Group A and C  
 \*\* P < 0.05 All groups at each time

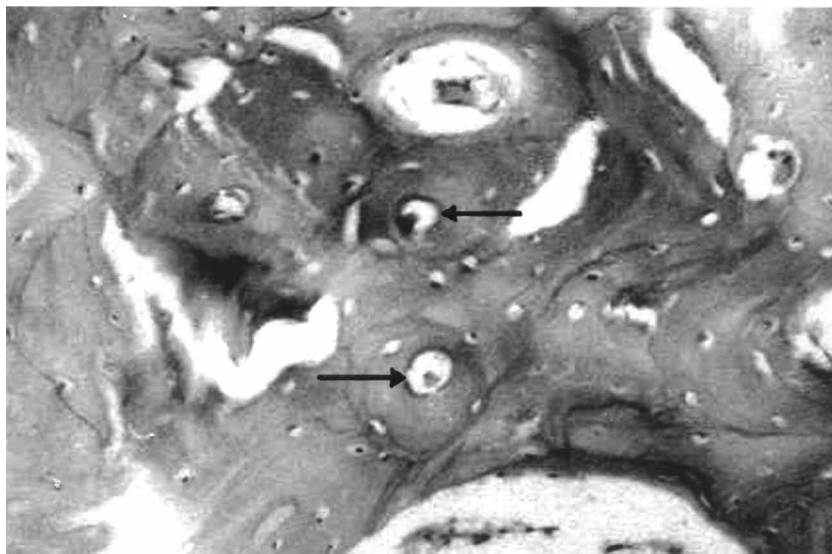


Figure 8. Histologic image of cuttlefish backbone (HE x 50). Arrows indicate increased number of osteoblasts in graft area.

obtained from scintigraphy and showed that SBG had the greatest bone healing, followed by cuttlefish backbone, TCP and DBM (Figure 7). Additionally, histological evaluation by an independent expert verified the presence of vascularised and proliferated connective tissues in all defective areas. An independent pathology expert compared all defective areas for osteoblastic activity as reflected by the number of osteoblasts surrounding the spherical white area (Figure 8) and reported that osteoblastic activity was 45, 40, 20 and 16 for Groups C, A, D and B, respectively.

### Discussion

Several researchers have investigated the efficacy and utilisation of various allografts (1,4,6,10,16) and xenografts (8,9,11,12) in orthopaedic surgery. Many of them have been substantiated and proved to be used safely (14,17-19). Yet, much research on graft materials is necessary to determine whether they meet all criteria that graft materials should possess. This experiment was carried out to determine whether cuttlefish backbone could be utilised as a xenograft in bone defects. In this experiment, defective areas were successful established to

mimic traumatic injury. It was also ensured that following sterilisation there was no contaminant on coarsed backbone (about 5 to 10 mm) by virological and bacteriological examinations. For instance, in the preparation of allografts, bone samples were subjected to refrigeration at  $-70^{\circ}\text{C}$  to reduce immunogenicity. Then the samples were treated with ethylene oxide and heat (above  $62^{\circ}\text{C}$ ) or gamma rays (2,3). In this experiment, we did not freeze the cuttlefish backbone. Histological examination did not reveal the presence of inflammation or immunological response, suggesting that sterilisation of cuttlefish backbone is easy compared with other xenografts and allografts.

The requirement of an advanced biomedical technology and economic feasibility remains the major factor determining the choice of selecting bone graft materials in surgery. A xenograft should be compatible with the structure and chemistry of natural cancellous bone with respect to its osteoconductive, osteoinductive and osteogenic properties so that the likelihood of compromising the bone repairing process can be minimised (7,8,15) and/or promoting bone reunion can be enhanced (2-4). Similar to other commonly used bone xenografts, cuttlefish backbone may play a load-bearing role by providing a scaffold in new bone growth. Moreover, cuttlefish backbone was easy to obtain, mold and sterilise, which are the factors influencing bioresorbability. In fact, materials used for bone-graft substitutes are available as pellets, pastes, strips, gels, putty, or blocks, which can be shaped to suit the defect (1). However, one may question the mechanical strength of cuttlefish backbone as a graft material, which should also be investigated.

Although DBM is used as an allograft in human medicine, it represented a xenograft in the present experiment because the host organisms were rabbits. Additionally, SBG and TCP were utilised to evaluate the feasibility and efficacy of cuttlefish backbone as a new graft material. In reality, autograft yields the most significant success in orthopaedic medicine (1,2,6,10,18). However, its utilisation is limited due to an increased risk for infection, wound drainage, haematomas, reoperation, prolonged pain, sensory loss and keloids (1). Autogenous bone grafting generally requires the patient to undergo a second skin incision, and there are the costs of long anaesthetic time and hospital stay (1). Therefore, xenografts are routinely used in human and veterinary

medicine. However, no xenograft materials fully meet the requirement for autogenous bone. Xenografts still have some disadvantages in terms of graft incorporation, resorption, mechanical strength and other problems linked to immunological rejection and microbiological contamination (1,19). That is, the provision of a desirable bone repairing process without complications has been the major consideration in evaluating the success of xenografts (17).

Radiological, biomechanic and histologic analyses are commonly used to compare the feasibility of bone graft use in different studies (5,13,18,19). To our knowledge, no study dealing with cuttlefish backbone is available. Our data obtained by radiography (Figure 4), MRI (Figure 5), scintigraphy (Figure 6) and histology (Figure 8) examinations revealed new callus formation in all groups, with the significance of being cuttlefish backbone ranking second, which suggests that this new material has an osteoconductive capacity, is resorbable, and does not interfere with graft incorporation. Moreover, a lack of gigantic cells in response to exposing host tissue to foreign material shows that cuttlefish backbone could be considered a new bone xenograft in terms of acceptability. Moreover, in the Ohgushi scoring system (14), the average of histologic and radiologic evaluations of calluses for graft materials resulted in cuttlefish backbone having the second highest score after bovine grafts in terms of osteoblastic activity, which is a very crucial bioactivity and biocompatibility factor for the bone reunion process. Acceptability was also supported by scintigraphy, in which cuttlefish backbone had the second highest ratio of the BT area to its mirror image in the BB area (Figure 7).

In conclusion, this study was conducted to determine the feasibility of the common cuttlefish and to compare its efficiency in bone defects with other commonly used xenografts. The preliminary data show that cuttlefish backbone is easy to obtain and mold and has considerable osteoconductive capacity. Cuttlefish backbone grafts may be clinically applicable to enhance osteogenesis and osteoconduction. In addition to conventional diagnostic tests, the bone repairing efficiency of cuttlefish backbone as a new alternative xenograft should be substantiated and monitored for a longer term in terms of clinical biochemistry (serum Ca, P, ALP activity and mRNA expression of protein osteocalcin), and biomechanical and electron microscopic grading in future studies.



## References

1. Van Heest, A., Swiontkowski, M.: Bone-graft substitutes. *Lancet*, 1999; 353: 28-29.
2. Albee, F.H.: Bone graft surgery. *Clin. Orthop. Relat. Res.*, 1996; 324: 5-12.
3. Friedlaender, G.E.: Bone grafts. The basic science rationale for clinical applications. *J. Bone Joint Surg. Am.*, 1987; 69: 786-790.
4. Lu, M., Rabie, A.B.M.: The effect of demineralized intramembranous bone matrix and basic fibroblast growth factor on the healing of allogeneic intramembranous bone grafts in the rabbit. *Arch. Oral Biol.*, 2002; 47: 831-841.
5. Inoue, K., Ohgushi, H., Yoshikawa, T., Okumura, M., Sempuku, T., Tamai, S., Dohi, Y.: The effects of aging on bone formation in porous hydroxyapatite: biochemical and histologic analysis. *J. Bone Miner. Res.*, 1997; 12: 989-994.
6. Sandhu, H.S., Grewal, H.S., Parvataneni, H.: Bone grafting for spinal fusion. *Orthop. Clin. North Am.*, 1999; 30: 685-698.
7. Urist, M.R.: Bone: "Formation by autoinduction". *Science*, 1965; 150: 893-899.
8. Horstmann, W.G., Verheyen, C.C.P.M., Leemans, R.: An injectable calcium phosphate cement as a bone-graft substitute in the treatment of displaced lateral tibial plateau fractures. *Injury*, 2003; 34: 141-144.
9. Perka, C., Schultz, O., Spitzer, R., Lindenhayn, K., Burmester, G., Sittlinger, M.: Segmental bone repair by tissue-engineered periosteal cell transplants with bioresorbable fleece and fibrin scaffolds in rabbits. *Biomaterials*, 2000; 21: 1145-1153.
10. Stevenson, S., Emery, S.E., Goldberg, V.M.: Factors affecting bone graft incorporation. *Clin. Orthop. Relat. Res.*, 1996; 324: 66-74.
11. Walsh, W.R., Chapman-Sheath, P.J., Cain, S., Debes, J., Bruce, W.J.M., Svehla, M.J., Gillies, R.M.: A resorbable porous ceramic composite bone graft substitute in a rabbit metaphyseal defect model. *J. Orthop. Res.*, 2003; 21: 655-661.
12. Bostrom, M.P., Yang, X., Kennan, M., Sandhu, H., Dicarolo, E., Lane, J.M.: An unexpected outcome during testing of commercially available demineralized bone graft materials: How safe are the nonallograft components? *Spine*, 2001; 26: 1425-1428.
13. Pekler, R.R., Friedlander, G.E.: Biomechanical aspects of bone autografts and allografts. *Orthop. Clin. North Am.*, 1987; 18: 235-239.
14. Ohgushi, H., Goldberg, V.M., Caplan, A.I.: Repair of bone defects with marrow cells and porous ceramic. Experiments in rats. *Acta Orthop. Scand.*, 1989; 60: 334-339.
15. Gunzburg, R., Szpalski, M.: Use of a novel beta-tricalcium phosphate-based bone void filler as a graft extender in spinal fusion surgeries. *Orthopedics*, 2002; 25: 591-595.
16. Young, W.F., Rosenwasser, R.H.: An early comparative analysis of the use of fibular allograft versus autologous iliac crest graft for interbody fusion after anterior cervical discectomy. *Spine*, 1993; 18: 1123-1124.
17. Kuboki, Y., Takita, T., Kobayashi, D., Tsuruga, E., Inoue, M., Murata, M., Nagai, N., Dohi, Y.: BMP-induced osteogenesis on the surface of hydroxyapatite with geometrically feasible and nonfeasible structures: topology of osteogenesis. *J. Biomed. Mater. Res.*, 1998; 40: 190-199.
18. Oktar, F.N., Göller, G., Heybeli, N., Varol, R.: Porous bioceramic production using human teeth. *J. Arthroplas. Arthroscop. Surg.*, 2002; 13: 99-104.
19. Karaismailoğlu, T.N., Tomak, Y., Andaç, A., Ergün, E.: Comparison of autograft, coralline graft, and xenograft in promoting posterior spinal fusion. *Acta Orthop. Traumatol. Turc*, 2002; 36: 147-154.
20. Laptikhovskiy, V., Salman, A., Onsoy, B., Katagan, T.: Fecundity of the common cuttlefish, *Sepia officinalis* L. (Cephalopoda, Sepiidae): a new look at an old problem. *Sci. Mar.*, 2003; 67: 279-284.
21. Webber, D.M., Aitken, J.P., O'Dor, R.K.: Costs of locomotion and vertic dynamics of cephalopods and fish. *Physiol. Biochem. Zool.*, 2000; 73: 651-62.
22. National Research Council: Nutritional requirements of laboratory animals. 1995, 4<sup>th</sup> rev. ed., 1-173, National Academy Press, Washington, DC.
23. Boyer, M.I., Gilday, D., Kiral, A., Nolan, L., Bowen, C.V.: Can quantitative <sup>99m</sup>Tc-MDP bone scans be used to predict longitudinal growth of epiphyseal plate allografts after microvascular transplantation? An experimental study. *Microsurgery*, 1995; 16: 155-60.