

1-1-2005

Immunohistochemical Localization of FSH Cells in the Pars Distalis of the Pituitary Gland in Five-Month-Old Laying Hens

HATİCE ERDOST

Follow this and additional works at: <https://journals.tubitak.gov.tr/veterinary>



Part of the [Animal Sciences Commons](#), and the [Veterinary Medicine Commons](#)

Recommended Citation

ERDOST, HATİCE (2005) "Immunohistochemical Localization of FSH Cells in the Pars Distalis of the Pituitary Gland in Five-Month-Old Laying Hens," *Turkish Journal of Veterinary & Animal Sciences*: Vol. 29: No. 5, Article 7. Available at: <https://journals.tubitak.gov.tr/veterinary/vol29/iss5/7>

This Article is brought to you for free and open access by TÜBİTAK Academic Journals. It has been accepted for inclusion in Turkish Journal of Veterinary & Animal Sciences by an authorized editor of TÜBİTAK Academic Journals. For more information, please contact academic.publications@tubitak.gov.tr.

Immunohistochemical Localization of FSH Cells in the Pars Distalis of the Pituitary Gland in Five-Month-Old Laying Hens

Hatice ERDOST

Department of Histology and Embryology, Faculty of Veterinary Medicine, Uludağ University, 16059 Bursa - TURKEY
E-mail: edost@uludag.edu.tr.

Received: 18.02.2004

Abstract: The present study was performed to determine the structural differences and immunohistochemical distribution of follicle-stimulating hormone (FSH) producing cells in the pars distalis region of the pituitary glands of 5 month-old laying hens, using the labeled avidin-biotin method. Hens begin to lay eggs at approximately the age of 5 months. It was observed that gonadotrophic cells containing FSH were present in both the cephalic and caudal zones and were densely distributed throughout the pars distalis. They appeared to be arranged in either cords or follicles in which branching and anastomosing occurred as well as being found as separate cells. The strongest positive FSH immunoreactivity was observed in most of the cells located in the caudal and cephalic zones of the pars distalis in 5 month-old laying hens. Furthermore, the total numbers of FSH immunoreactive cells (in $1 \mu\text{m}^2$) were similar in the cephalic and caudal zones.

Key Words: Pituitary gland, pars distalis, FSH cells, laying hens

Beş Aylık Tavukların Hipofiz Bezinin Pars Distalisindeki FSH İçeren Hücrelerin İmmunohistokimyasal Dağılımı

Özet: Bu çalışmada, beş aylık yumurtacı tavukların FSH salgılayan gonodotrop hücreleri işaretli avidin-biotin yöntemi ile saptanarak; hücrelerin yapısal özellikleri ve pars distalisteki dağılımları incelendi. Beş aylık yaş, tavukların yumurtlama periyodunun başlangıcıdır. Pars distalisin sefhalik ve kaudal bölgelerinin her ikisinde de FSH immunreaktif hücreler görüldü. FSH-ir hücrelerin tek tek yerleşim gösterdiği gibi kordonlar, foliküller oluşturarak dallanmalar ve anostomozlar şekillendirdiği saptandı. Beş aylık yumurtacı tavukların pars distalisinde bulunan FSH-ir hücrelerin büyük çoğunluğunun kuvvetli pozitif immunreaksiyon verdiği gözlemlendi. Ayrıca FSH-ir hücrelerin toplam sayısı ($1 \mu\text{m}^2$) hem sefhalik hem de kaudal bölgede birbirine oldukça yakın değerlerde bulundu.

Anahtar Sözcükler: Hipofiz bezi, pars distalis, FSH hücreleri, yumurtacı tavuk

Introduction

Gonadal development in fowl as well as in mammals depends on the function of pituitary hormones. Luteinizing hormone (LH) and follicle-stimulating hormone (FSH), considered the major gonadotrophic hormones produced by the pituitary gland, are particularly critical for the regulation of ovulation. These hormones have stimulatory effects on the production of eggs. Hens begin to lay eggs at approximately the age of 5 months. During this period, FSH cells become activated to stimulate the growth of follicles, which will give rise to mature eggs in laying hens (1,2).

The objective of the current study was to determine the structural differences and immunohistochemical distribution of FSH producing cells in the pars distalis region of the pituitary glands of 5 month-old laying hens.

Materials and Methods

Ten Isobrown laying hens (egg type) at the age of 5 months were sacrificed by cervical dislocation. The hypophyses were removed and fixed in buffered neutral formalin for 24 h. They were then processed routinely through paraffin. The tissues were embedded parasagittally into paraffin blocks. The sections were cut to 6- μm thickness and were stained with the triple method (3). The cephalic and caudal zones were determined from the triple stained sections. For immunohistochemistry, 6- μm -thick sections were cut and mounted on poly-L-lysine (Sigma, St Louis, MO, USA) coated slides. Monoclonal mouse-antihuman FSH (Zymed, San Francisco, CA, USA) as a primary antibody was used to identify FSH immunoreactive (FSH-ir) cells in the pars distalis of the pituitary glands by the modified labeled

avidin-biotin method (4) using Histostain-Plus Bulk Kits (Zymed 2nd Generation LAB-SA Detection System). This protocol was modified in the antigen retrieval step by putting the slides into citrate buffer (pH 6) in a microwave oven at 700 W for 5 min 3 times. Then the sections were incubated with monoclonal mouse anti-human-FSH primary antibody in a dilution of 1/100 for 90 min at 37 °C. The specificity of immunolabeling was assessed by omission of the primary antibody and incubation with non-immune serum. All these control experiments gave negative results.

FSH-ir cells were classified depending on the density of the staining as weakly (+), moderately (++) and strongly stained (+++). Based on this classification, the average number of FSH-ir cells was calculated (5), after the cells were counted per 1 μm² per 10 squares.

Results

The triple stained sections confirmed that the adenohypophysis was composed of pars distalis and pars tuberalis regions in the pituitary glands of 5 month-old laying hens (Figure 1). The pars intermedia did not exist in the adenohypophysis. The pars distalis occupied the major part of the pituitary gland. The secretory cells of the pars distalis appeared to be arranged in either cords or follicles in which branching and anastomosing occurred. No structural distinction was observed between cephalic and caudal zones. Connective tissue

strands were not separately located in the zones (Figure 1). The cords of the cells in the caudal zone of the pars distalis were more loosely arranged than those in the cephalic zone.

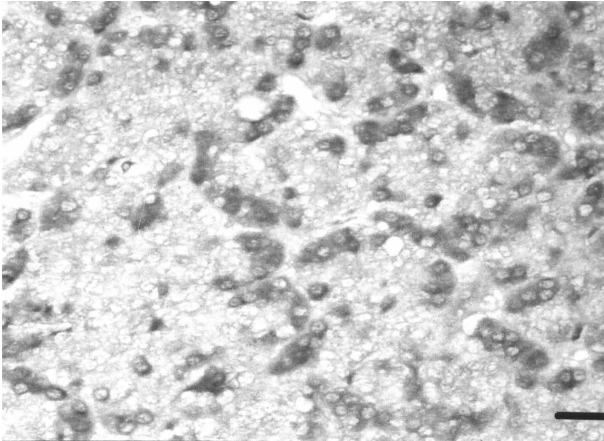
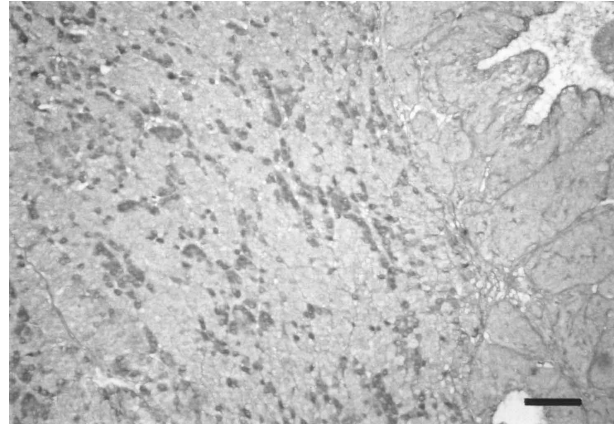
FSH-ir cells were localized in both the cephalic and caudal zones of the pars distalis. However, they were distributed differently throughout the pars distalis of the 5 month-old laying hens (Figure 2). FSH positive labeling was observed in the cytoplasm of the gonadotrophic cells. FSH-ir cells stained brown with DAB chromogen had a small amount of cytoplasm, and spherical or ovoid and relatively euchromatic nuclei located at the center of the cells (Figure 3). The staining densities of the FSH-ir cells in the cephalic and caudal zones are shown in the Table. The average numbers of FSH-ir cells were similar in the cephalic and caudal zones. Additionally, the strongest positive reaction for FSH-ir cells was observed in both zones (Table). While limited number of weakly stained (+) FSH-ir cells were observed, moderately stained (++) FSH-ir cells had the same arithmetical average rate in both zones. FSH-ir cells of the pars distalis appeared to be arranged in either cords or follicles in which branching and anastomosing occurred, as well as being found as separate cells (Figure 4). Those cords and follicles had thin diameters and thus most cells were touching or close to the external surface of the cords. They were elongated in different shapes and were polarized towards the sinusoids of the pituitary gland.

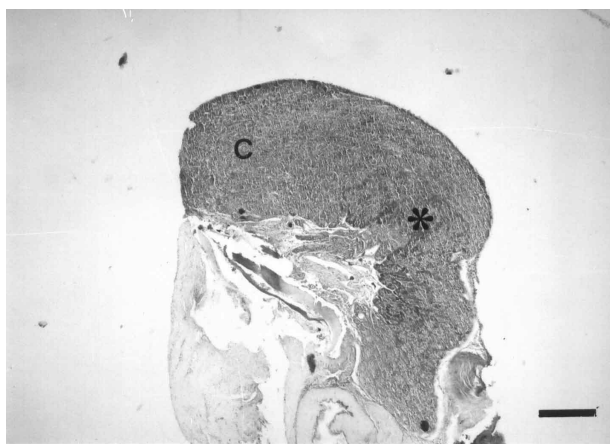

Figure 1. Cephalic and caudal zones of the pars distalis, cephalic (C), caudal zones (*), triple. Bar 350 μm.



Figure 2. FSH-ir cells. Bar 140 μm.

Figure 3. FSH-ir cells. Bar 35 μm .Figure 4. FSH-ir cells. Bar 70 μm .Table. Arithmetical mean, total, minimum and maximum values of FSH-ir cells, 1 μm^2 in cephalic and caudal zones of the pars distalis.

	Cephalic Lobes				Caudal Lobes			
	Arithmetical mean	Total	Min	Max	Arithmetical mean	Total	Min	Max
+ FSH-ir cells	1.5	12.2	1	2	1.6	12.1	0	3
++ FSH-ir cells	2.6	12.2	2	4	2.6	12.1	1	4
+++ FSH-ir cells	8.1	12.2	7	9	7.9	12.1	7	9

Discussion

The pituitary glands of 5-month-old hens used in the present study demonstrated a structural similarity with those fowl (6,7). The majority of the gonadotrophs contained both LH and FSH in the same cells (8-10). In pigs (11) and lizards (12), all the gonadotrophs reportedly contained both LH and FSH. In other species ranging from humans (13) to frogs (9), at least two-thirds of the gonadotrophs contained both hormones. However, LH and FSH were produced in separate cells in bovine and chicken pituitary glands (8). FSH and LH resided in different cells in the pars distalis region of chicken pituitary glands (14). The cellular localization of the gonadotrophs was determined by immunohistochemical techniques in a variety of species (9,10,15,16). There were conflicting findings regarding

whether there were 1 or 2 types of gonadotrophic cells in birds and whether those gonadotrophic cells were found in both zones or just in the caudal zone of the pars distalis (14,17). We observed that gonadotrophs containing FSH were densely distributed throughout the pars distalis, while they were present in both zones.

Our results showed that FSH-ir cells were arranged in either cords or follicles in which branching and anastomosing occurred as well as being found as separate cells in both zones of the pars distalis. Total numbers of FSH-ir cells were similar in the cephalic and caudal zones. Additionally, the strongest positive reaction for FSH-ir cells was observed in both zones. While very few weakly stained (+) FSH-ir cells were observed, moderately stained (++) FSH-ir cells had the same arithmetical average rate in both zones.

References

1. Dellmann, H.D., Eurell, A.: Textbook of Veterinary Histology. Fifth Edition, Williams & Wilkins, USA, 1998.
2. Hattori, A., Ishii, S., Wada, M.: Different mechanisms controlling FSH and LH release in Japanese quail (*Coturnix coturnix japonica*): Evidence for an inherently spontaneous release and production of FSH. *J. Endocrinol.*, 1986; 108: 239-245.
3. Crossmonn, G.: A modification of Mallory's connective tissue stain with a discussion of the principles involved. *Anat. Rec.*, 1937; 69: 33-38.
4. Erdost, H.: Immunohistochemical study on the chicken adenohypophysis using monoclonal mouse anti-human FSH as a primary antibody. *Anat. Histol. Embryol.*, 2004; 33: 49-52.
5. Sümbüloğlu, K., Sümbüloğlu, U.: Biyoistatistik. Özdemir Yayıncılık, Ankara. 1994.
6. Farner, D.S., King, J.R., Parkes, K.C.: Avian Biology. Vol. III, Academic Press, New York 128-148, 1973.
7. Hodges, R.D.: The Histology of the Fowl, Academic Press, London, 429-431, 1974.
8. Bastings, E., Beckers, A., Reznik, M., Beckers, J.F.: Immunocytochemical evidence for production of luteinizing hormone and follicle-stimulating hormone in separate cells in the bovine. *Biol. Reprod.*, 1991; 45: 788-796.
9. Pinelli, C., Fiorentino, M., D'Aniello, B., Tanaka, S., Rastogi, R.K.: Immunohistochemical demonstration of FSH and LH in the pituitary of the developing frog, *Rana esculenta*. *Gen. Comp. Endocrinol.* 1996; 104: 189-196.
10. Rahmanian, M.S., Thompson, D.L. Jr., Melrose, P.A.: Immunocytochemical localization of luteinizing hormone and follicle-stimulating hormone in the pituitary. *J. Anim. Sci.*, 1998; 76: 839-846.
11. Dacheux, F.: Subcellular localization of gonadotropic hormones in pituitary cells of the castrated pig with the use of pre- and post-embedding immunocytochemical methods. *Cell Tissue Res.*, 1984; 236: 153-160.
12. Naik, D.R., Sar, M., Stumpf, W.E.: Immunohistochemical identification of cells in the pars distalis of the pituitary of the lizard, *Anolis carolinensis*. *Histochemistry*, 1980; 69: 19-26.
13. Pelletier, G., Leclerc, R., Fabrie, F.: Identification of gonadotropic cells in the human pituitary by immunoperoxidase technique. *Mol. Cell. Endocrinol.*, 1976; 6: 123-128.
14. Proudman, J.A., Vandesande, F., Berghman, L.R.: Immunohistochemical evidence that follicle-stimulating hormone and luteinizing hormone reside in separate cells in the chicken pituitary. *Biol. Reprod.*, 1999; 60: 1324-1328.
15. Mikami, S.: Avian Hypophysis: Recent progress in immunocytochemical studies. In: Mikami, S., Homma, K., Wada, M. (eds), *Avian Endocrinology: Environmental and Ecological Perspectives*. New York, Springer-Verlag: 39-56, 1983.
16. Iwama, Y.: Immunohistochemical identification of mouse adenohypophysial gonadotropes. *Okajimas Folia Anat. Jpn.*, 1990; 67: 281-287.
17. Mikami, S., Kurosu, T., Farner, D.S.: Light and electron microscopic studies on the secretory cytology of the adenohypophysis of the Japanese quail, *Coturnix coturnix japonica*. *Cell Tissue Res.*, 1975; 159: 147-165.