

1-1-2006

Abortions in Sheep Due to *Listeria ivanovii* in the Kars Region

MİTHAT ŞAHİN

ENVER BEYTUT

Follow this and additional works at: <https://journals.tubitak.gov.tr/veterinary>



Part of the [Animal Sciences Commons](#), and the [Veterinary Medicine Commons](#)

Recommended Citation

ŞAHİN, MİTHAT and BEYTUT, ENVER (2006) "Abortions in Sheep Due to *Listeria ivanovii* in the Kars Region," *Turkish Journal of Veterinary & Animal Sciences*: Vol. 30: No. 5, Article 12. Available at: <https://journals.tubitak.gov.tr/veterinary/vol30/iss5/12>

This Article is brought to you for free and open access by TÜBİTAK Academic Journals. It has been accepted for inclusion in Turkish Journal of Veterinary & Animal Sciences by an authorized editor of TÜBİTAK Academic Journals. For more information, please contact academic.publications@tubitak.gov.tr.

Abortions in Sheep Due to *Listeria ivanovii* in the Kars Region

Mitat ŞAHİN^{1,*}, Enver BEYTUT²

¹Department of Microbiology, Faculty of Veterinary Medicine, University of Kafkas, Kars - TURKEY

²Department of Pathology, Faculty of Veterinary Medicine, University of Kafkas, Kars - TURKEY

Received: 16.01.2006

Abstract: This report describes an outbreak of *Listeria ivanovii*-induced abortion in sheep in the Kars region. In a flock of 120 sheep raised in Taşlıdere, a village in the region of Arpaçay, in Kars, some ewes in the last stages of gestation aborted in March, 2004. Necropsy was conducted on 5 aborted fetuses. Livers of the aborted fetuses showed diffuse necrotic foci. Histologically, the liver and lungs of aborted fetuses revealed diffuse coagulative necrosis infiltrated with macrophages and neutrophils. Bacterial culture from the liver and lungs of fetuses found pure growth of *L. ivanovii* subsp. *ivanovii*.

Key Words: Sheep, *Listeria ivanovii*, abortion

Kars Yöresinde *Listeria ivanovii* Enfeksiyonuna Bağlı Koyun Abortları

Özet: Bu çalışmada, Kars yöresinde *Listeria ivanovii* enfeksiyonuna bağlı koyun abortlarının bildirilmesi amaçlanmıştır. Arpaçay ilçesine bağlı Taşlıdere köyünde 120 baş koyundan oluşan ve gebeliklerinin son döneminde olan bir sürüde Mart 2004 tarihinde bazı koyunlarda abortlar gözlenmiş; nekropsi yapılan 5 fötusun karaciğerlerinde diffuz nekroz odakları saptanmıştır. Histolojik olarak, atık fötusların karaciğer ve akciğerlerde yaygın koagülasyon nekrozu ile birlikte makrofaj ve nötrofil infiltrasyonları izlenmiştir. Fötusların karaciğer ve akciğerlerinden yapılan bakteriyolojik kültürlerde *L. ivanovii* subsp. *ivanovii*'nin saf olarak ürediği gözlenmiştir.

Anahtar Sözcükler: Koyun, *Listeria ivanovii*, abort

Listeric infections, caused by micro-organisms of the genus *Listeria*, occur worldwide and in a variety of animals, including humans. *Listeria monocytogenes* and *L. ivanovii* are the most important animal pathogens within the genus *Listeria* (1). Common manifestations of listeriosis in animals include meningitis, encephalitis, meningoenzephalitis, abortion and neonatal sepsis (1). Abortion in sheep due to listeriosis is known to be an important problem in many sheep-raising areas of the world (2). Apart from *L. monocytogenes*, *L. ivanovii*, formerly known as *L. monocytogenes* serotype 5, is the only other pathogenic *Listeria* species (3). Infection with *L. ivanovii* is recognised as a cause of abortions and stillbirths in sheep, as well as of the birth of live lambs that are weak and often fail to survive (3). This report describes an outbreak of abortion caused by *L. ivanovii* in a flock of 120 sheep raised in a village in the Kars region. Furthermore, this is most probably the first report of *L. ivanovii*-induced abortion in sheep in Turkey.

Eighty out of 120 crossbred sheep raised on a farm in Taşlıdere, a village located in the region of Arpaçay, in Kars, were pregnant ewes in the last stages of gestation. There was no clinical sign of any illness in the flock but 4 ewes aborted in March, 2004. Moreover, further abortions and deaths of neonatal lambs (8 animals) followed at irregular intervals until the end of April 2004, although none of the ewes showed any premonitory clinical signs. Over about 2 months, 5 aborted fetuses were brought to the Department of Veterinary Pathology, University of Kafkas, Kars, for postmortem examination.

Tissue samples were taken for light microscopic examination from the liver, kidney, spleen, lungs, heart, cerebrum and cerebellum of the fetuses. All samples were fixed in 10% buffered formalin, processed routinely, and stained with haematoxylin and eosin (H&E). Some liver and lung sections were also stained with Brown and Brenn (B&B) Gram stain.

* E-mail: mitats@hotmail.com

The liver and lung samples were cultured on 7% sheep blood agar (Oxoid), *Listeria* selective medium (Oxoid), and Eosin Methylene Blue (EMB) agar. The cultures were incubated at 37 °C for 3 days, aerobically and microaerobically (Microaerobic kit, Merck, Anaerocult C), in candle jars.

All of the foetuses had a clear to sanguineous fluid in the body cavities, with a little blood-tinged fluid in the subcutis. Numerous yellowish-white necrotic foci (from 1 to 3 mm in diameter) were distributed on the livers. Necrotic foci were well demarcated and were severe on the right lobes in particular (Figure 1). No changes were observed in other organs.

In the liver, the necrotic foci were characterised by multifocal coagulative necrosis of varying size (Figure 2), and were surrounded by macrophages and neutrophils with deep eosinophilic staining of the cytoplasm of a few hepatocytes at the periphery. Perivascular mononuclear cell infiltration and minor haemorrhages were also noted. In 3 cases, the lungs revealed severe focal necroses surrounded by inflammatory cell reaction next to the airways, with marked haemorrhages (Figure 3). Based on B&B Gram staining, both the liver and lung sections revealed numerous cytoplasmic bacilli laden macrophages in the necrotic foci.

All samples yielded almost pure growth of β -haemolytic colonies on the blood agar at the end of the

incubation period. The bacterial colonies were small (1-2 mm in diameter), smooth, circular and whitish-grey. On the *Listeria* selective agar, the colonies had similar characteristics and were 3-4 mm in size. Growth was not observed on EMB agar. Staining of smears from the colonies revealed small Gram-positive bacilli. Similar bacilli could also be seen in smears from the necrotic foci on the livers. The isolate was catalase positive, phosphatase, methyl red and Voges-Proskauer test positive, it hydrolysed aesculin and exhibited tumbling motility between 25 and 30 °C. The CAMP test was positive with *R. equi* and negative with *S. aureus*. Based on cultural characteristics, morphology and biochemical reactions, the isolates were distinguishable from *L. monocytogenes*. The isolates were sent to the Department of Microbiology, Gülhane Military Medical Academy, Ankara, for confirmation and serotyping, and were identified as *L. ivanovii* subsp. *ivanovii*.

Listeriosis is a sporadic disease of several animal species and humans, but it is most important economically in animals. Moreover, listeriosis is one of the most common causes of meningitis in humans and nonhuman primates (4). Listeric abortions are commonly caused by *L. monocytogenes* and occur in ruminants and many other species of domesticated animals. *L. ivanovii* is also recorded as a cause of abortion in sheep (2,3) and cattle (5,6), but occurs less frequently than *L.*

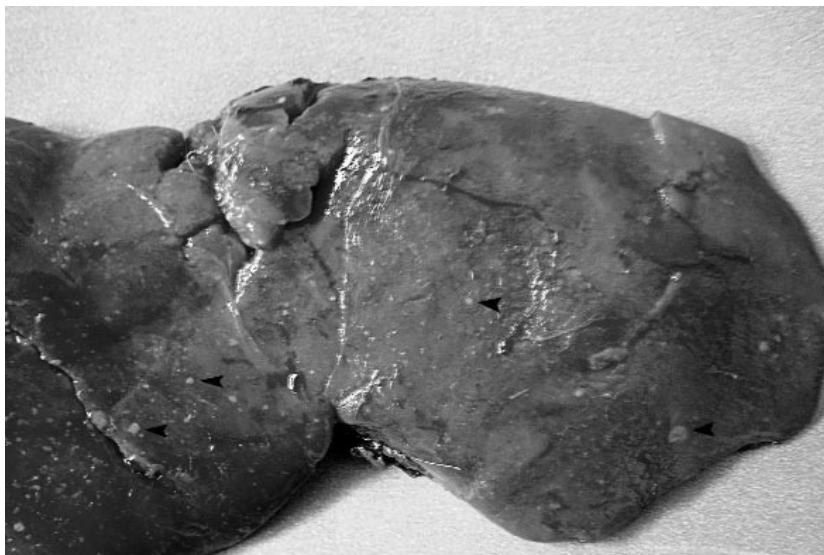

Figure 1. Numerous yellowish-white necrotic foci (arrows) of varying size in the liver of an aborted lamb.

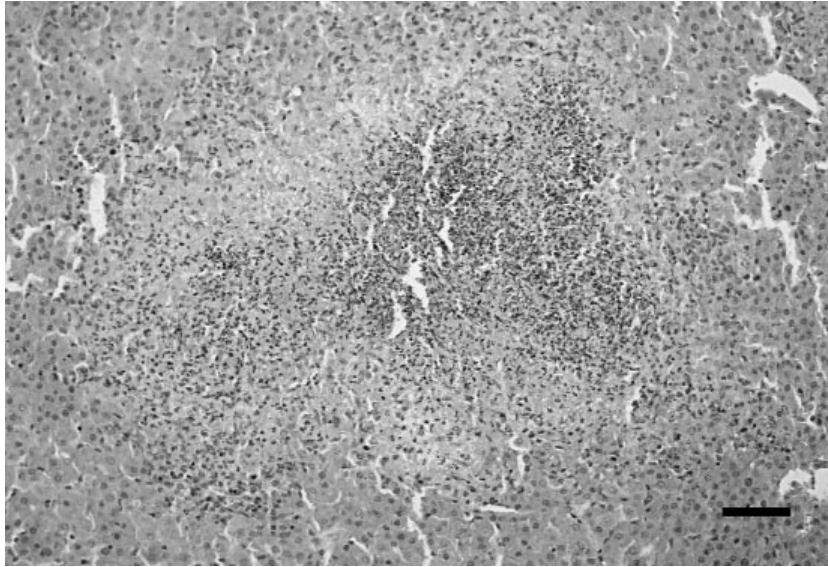


Figure 2. Coagulative necrotic foci in the liver with varying degrees of infiltration by macrophages and neutrophils. H&E, Bar = 20 µm.

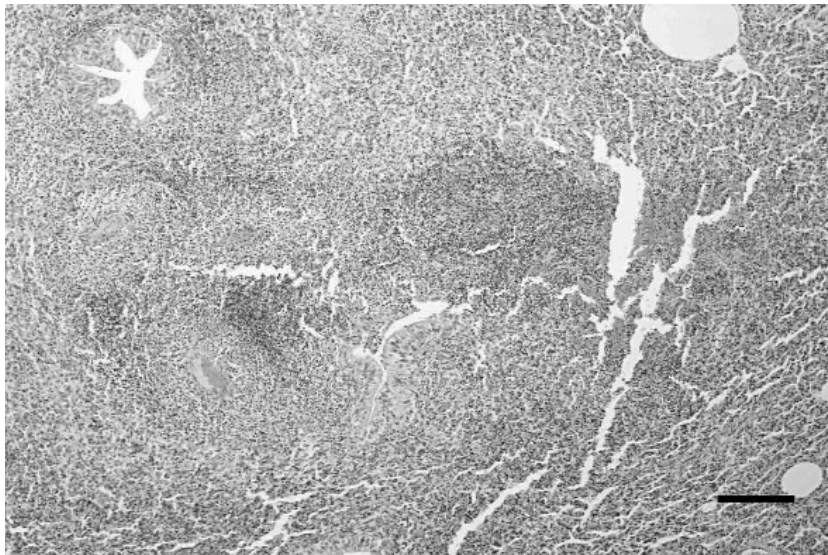


Figure 3. Lung from an aborted lamb showing severe necrosis characterised by marked karyorrhexis. H&E, Bar = 20 µm.

monocytogenes and is extremely rare as a cause of other conditions. Listeric abortions caused by *L. ivanovii* in sheep and cattle have not been reported in Turkey to date, based on our literature review, and thus this is probably the first report of *L. ivanovii*-induced abortion in sheep in this country.

It has been reported that outbreaks of listeriosis in sheep are often associated with periods of cold and wet weather, nutritional stress and sometimes with the feeding of silage, especially poor quality silage (2,3,6). In our region, the winters are long; moreover in the period in which the abortions occurred the weather had been

extremely cold and wet because of heavy rainfall. A change to cold and wet weather and the confinement of sheep in sheds have been reported to favour the growth and spread of *Listeria* micro-organisms (2). The affected flock had been fed mouldy hay and barley. Although the source of infection in the flock could not be established with certainty since cultivation from the feeds was not possible, there is evidence that these types of animal feed might contain *Listeria* organisms (4,7). Likewise, Sergeant et al. (3) have recorded similar conditions and they concluded that hay spoiled by heavy rainfall and contaminated with *L. ivanovii* was responsible for an outbreak. Thus, the ubiquitous organism may have gained entry into the animals through contaminated feed or water.

The livers of the foetuses showed similar lesions grossly and were characterised by multifocal, whitish, pin-point, necrotic foci mainly located on the right lobes, consistent with previous descriptions of listerial abortions (2,3). Histologically, these lesions showed diffuse coagulative necroses of hepatocytes infiltrated with macrophages and neutrophils laden with the cytoplasmic bacteria. Moreover, similar findings have been documented as characteristic lesions of foetuses in

Listeria-induced abortions (6). Although the lungs revealed no gross lesions, necrotic foci surrounded by phagocytic cells associated with haemorrhages were detected histologically. Consistent with our findings, Gill et al. (6) reported that the lungs of aborted bovine foetuses showed bronchopneumonia along with infiltration of the bronchioles and alveoli by polymorphonuclear leucocytes, macrophages and giant cells, and that the lesions might have been caused by the spread of the agents from the placenta to the foetus via the amniotic fluid.

In conclusion, even though gross and histopathological lesions in the present report were compatible with those of ovine foetuses in abortions caused by *Listeria* spp., the diagnosis depended principally on the isolation and identification of *L. ivanovii*.

Acknowledgements

The authors would like to thank Dr. Ali Albay of the Department of Microbiology, Gülhane Military Medical Academy, Ankara, for confirming and serotyping the isolates.

References

1. Arumugaswamy, R., Gibson, L.F.: *Listeria* in zoo animals and rivers. *Aust. Vet. J.*, 1999; 77: 819-820.
2. Chand, P., Sadana, J.R.: Outbreak of *Listeria ivanovii* abortion in sheep in India. *Vet. Rec.*, 1999; 145: 83-84.
3. Sergeant, E.S.G., Love, S.C.J., McInnes, A.: Abortions in sheep due to *Listeria ivanovii*. *Aust. Vet. J.*, 1991; 68: 39.
4. Vazquez-Boland, J.A., Kuhn, M., Berche, P., Chakraborty, T., Dominguez-Bernal, G., Goebel, W., Gonzalez-Zorn, B., Wehland, J., Kreft, J.: *Listeria* pathogenesis and molecular virulence determinants. *Clin. Microbiol. Rev.*, 2001; 14: 584-640.
5. Alexander, A.V., Walker, R.L., Johnson, B.J., Charlton, B.R., Woods, L.W.: Bovine abortions attributable to *Listeria ivanovii*: four cases (1988-1990). *J. Am. Vet. Med. Assoc.*, 1992; 200: 711-714.
6. Gill, P.A., Boulton, J.G., Fraser, G.C., Stevenson, A.E., Reddacliff, L.A.: Bovine abortion caused by *Listeria ivanovii*. *Aust. Vet. J.*, 1997; 75: 214.
7. Low, J.C., Donachie, W.: A review of *Listeria monocytogenes* and listeriosis. *Vet. J.*, 1997; 153: 9-29.