

1-1-2006

The Pathologic and Bacteriologic Comparison of Pneumonia in Lambs

ERTAN ORUÇ

Follow this and additional works at: <https://journals.tubitak.gov.tr/veterinary>



Part of the [Animal Sciences Commons](#), and the [Veterinary Medicine Commons](#)

Recommended Citation

ORUÇ, ERTAN (2006) "The Pathologic and Bacteriologic Comparison of Pneumonia in Lambs," *Turkish Journal of Veterinary & Animal Sciences*: Vol. 30: No. 6, Article 14. Available at: <https://journals.tubitak.gov.tr/veterinary/vol30/iss6/14>

This Article is brought to you for free and open access by TÜBİTAK Academic Journals. It has been accepted for inclusion in Turkish Journal of Veterinary & Animal Sciences by an authorized editor of TÜBİTAK Academic Journals. For more information, please contact academic.publications@tubitak.gov.tr.

The Pathologic and Bacteriologic Comparison of Pneumonia in Lambs

Ertan ORUÇ*

Veterinary Control and Research Institute, 42080 Meram, Konya - TURKEY

Received: 25.11.2005

Abstract: The correlations between the bacteriologic agent of lamb pneumonia and its pathologic characters were investigated in this study. Pneumonia was detected in 262 (35.41%) of 740 diseased or dead lambs. Pathogenic bacteria were isolated in 114 cases (14.96% of all lamb deaths and 43.51% of all pneumonias). Lung lesions were histopathologically described as acute-catarrhal (17.56%), catarrhal-purulent (14.50%), purulent-necrotic (9.54%), fibrinous (26.72%), fibrinous-necrotic (5.73%), interstitial (18.32%), or verminous pneumonia (7.63%). In bacteriological studies, *Mannheimia haemolytica* (56.14%), *E. coli* (24.56%), and *Pasteurella multocida* (10.52%) were detected as important bacterial agents that caused different pneumonic lesions in lambs.

Key Words: Lamb, pneumonia, pathology, bacteriology

Kuzu Pnömonilerinde Patolojik ve Bakteriolojik Karşılaştırma

Özet: Çalışmada kuzu pnömonilerinde bakteriyel etken ve patolojik karakterleri karşılaştırıldı. Hastalıklı ya da ölü 740 kuzudan 262'sinde (% 35,41) pnömoni tesbit edilirken, 114 vakada (tüm kuzu ölümlerinde % 14,96 ve tüm pnömonilerde % 43,51) patojenik bakteri izole edildi. Akciğer lezyonları histopatolojik olarak akut-kataral (% 17,56), kataral-purulent (% 14,50), purulent-nekrotik (% 9,54) fibrinli (% 26,72), fibrinli-nekrotik (% 5,73), intersitisyel (% 18,32) ve verminöz (% 7,63) pnömoni olarak tanımlandı. Bakteriolojik ekimlerde sırasıyla *Mannheimia haemolytica* (% 56,14), *E. coli* (% 24,56) ve *Pasteurella multocida* (% 10,52)'nin kuzularda önemli bakteriyel pnömoni etkenleri olduğu ve farklı tiplerde pnömonik lezyonlara yol açtığı görüldü.

Anahtar Sözcükler: Kuzu, pnömoni, patoloji, bakteriyojoloji

Sheep pneumonia is especially common in newborn and feedlot lambs, and it is one of the most important causes of lamb mortality. Pneumonia is caused by a complex interaction between the environment, which produces stress, microorganisms, and the host's immune response. Pneumonic lesions are frequently seen in necropsy in sheep of all ages. It is likely that, either alone or in combination with other disease conditions, pneumonias are a significant cause of loss to the sheep industry (1-4).

Several histological forms are seen in pneumonic diseases: mild to severe, acute to chronic, and exudative to proliferative interstitial. Traditional bacterial pneumonias are characterized by exudation and consolidation of the lung. The typical gross appearance of bronchopneumonia is of irregular consolidation in

cranioventral regions. The cranial and middle lobes are most often affected in those species having well-defined lobation. Consolidated lungs vary from dark red, through gray-pink, to more gray, depending on the age and nature of the process. Consolidation of the tissue is the single most important gross criterion of pneumonia (5). The cut surface of infected lungs reflects the variability of involvement seen on the pleural surface.

In catarrhal or suppurative bronchopneumonia, the section of consolidated lobules is moist and mucopurulent or purulent material can be expressed from small airways. The cut surface of fibrinous inflammation has a dull and dryish appearance. Histopathologically, bronchioles and immediately adjacent alveoli are filled with neutrophils, and sometimes an admixture of various amounts of cell debris, mucus, fibrin, and macrophages.

* E-mail: ertanoruc@hotmail.com

Depending on the nature and pathogenicity of the causative agent, bronchiolar epithelium varies from necrotic to hyperplastic. Interstitial pneumonias have been thought of as chronic inflammatory conditions in which there is predominantly a proliferative response involving alveolar walls and the supporting stroma. Acute pulmonary injury can be caused by or is associated with a wide variety of conditions, such as severe viral pneumonia, chemical lung injury, acute pancreatitis, shock, and septicemia. Most interstitial pneumonias in animals are infectious in origin and are caused by viral, bacterial, fungal, or parasitic diseases. The lungs are at the crossroads of parasitic migration, and many parasites that pass through them cause varying degrees of damage according to the nature and intensity of the host-parasite interaction. Severe and possibly fatal pulmonary lesions may develop if the migrating parasites are large in number, large in size, or especially when the host has a hypersensitive reaction to them (3-12).

Many species of pathogenic bacteria can cause bronchopneumonia. In acute outbreaks of pneumonia, *Mannheimia (Pasteurella) haemolytica* is the organism most frequently isolated from infected lung tissue (3,5,8,9). In one study (13), *Mannheimia haemolytica* isolates from veterinary samples were serotyped over a 3-year period and it was determined that serotypes A2, T4, T10, and T15 were the most common sheep isolates, A2 being most frequently associated with lamb pneumonia. A number of other bacteria, including *Pasteurella multocida*, *Mycoplasma*, *Escherichia coli*, *Actinomyces pyogenes*, *Streptococcus*, and *Staphylococcus* were isolated in many infected lungs of sheep and goats (5-9,14-16).

This study was carried out to determine the incidence of lamb pneumonia and its role in lamb morbidity and mortality, as well as to describe the pathological characters of pneumonia and to determine the correlation between the bacterial agent and its pathological characters.

The study included 740 newborn to 6-month-old dead or terminally diseased lambs that were examined and necropsied between 2000 and 2004 in our institute. Pathological and bacteriological studies were performed on 262 lungs that showed gross lesions. All diseased lung samples were submitted to the Bacteriology Department for bacterial isolation and identification.

For bacteria isolation and identification, specimens from pneumonic lungs were inoculated onto 7% sheep blood agar and MacConkey agar plates, and were then aerobically incubated at 37 °C for 24-48 h. Isolates were identified using standard microbiological techniques (17).

For histopathological examinations, tissue specimens were fixed in 10% formalin buffered solution after gross examination. After routine histopathological processing, 5-6 µm paraffin sections were stained with hematoxylin and eosin (H-E) (18). All sections were microscopically examined.

Pneumonias were classified into 7 subgroups according to their histological appearances.

Acute Catarrhal Bronchopneumonia (ACBP):

In total, 46 cases (17.56%) were evaluated as ACBP. Hyperemia and linear consolidated areas were grossly visible on cranial lobes. In histopathological examinations, capillary hyperemia, edema, and a few neutrophilic exudations were seen within the alveolar and bronchiolar lumina. Pathogenic bacteria were isolated in 14 cases (14/46), including *E. coli* (n = 8), *Mannheimia haemolytica* (n = 5), and *Pasteurella multocida* (n = 1).

Catarrhal Purulent Bronchopneumonia (CPBP):

Multifocal and severely consolidated areas were grossly visible on the cranial lobes. There was purulent exudation on the cut surfaces of the lungs. Histopathologically, moderate neutrophilic exudations were observed in both alveolar and bronchiolar lumina (Figure 1). Alveolar macrophages within the alveoli and epithelial desquamation of the bronchioles were also seen in this area. In all, 38 cases (14.50%) were described as CPBP. *Mannheimia haemolytica* (n = 10), *E. coli* (n = 6), *Actinomyces* spp. (n = 3), *Staphylococcus aureus* (n = 2), and *Pseudomonas* spp. (n = 1) were isolated in this pneumonia type.

Purulent Necrotic Bronchopneumonia (PNBP):

More extensive and necrotic changes than CPBP were observed. In histological examination, large amounts of neutrophils and necrosis were seen, and severe desquamation was detected on bronchial and bronchiolar epithelium. In 14 of the 25 cases of PNBP (9.54%), the following bacteria were isolated: *Mannheimia haemolytica* (n = 9), *Pasteurella multocida* (n = 2), *E. coli* (n = 1), *Streptococcus* n = 1), and *Pseudomonas* spp. (n = 1).

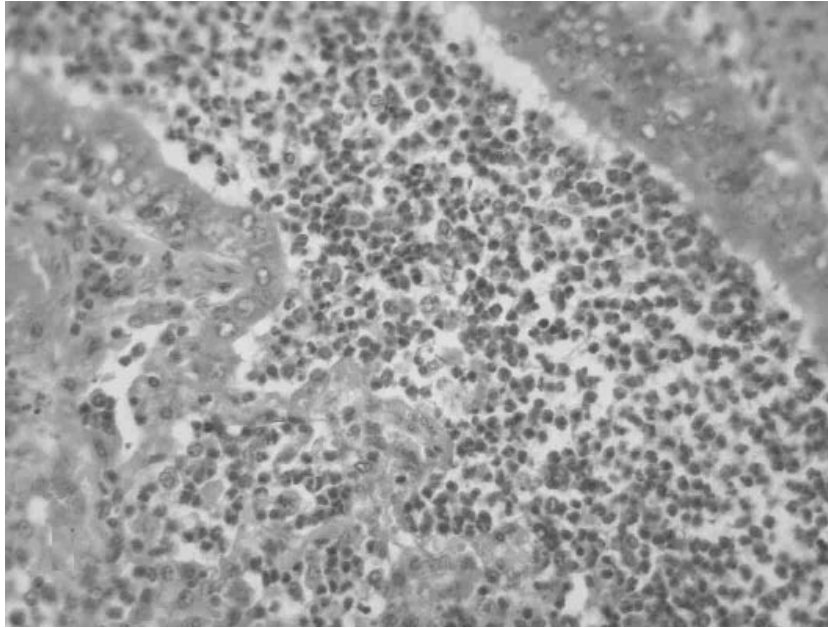


Figure 1. Lamb lung, catarrhal-purulent bronchopneumonia. Hyperemia and neutrophilic exudation of bronchial lumina and alveoli. *E. coli* was isolated from this case. H-E.

Fibrinous Pneumonia (FP):

Diffuse or lobular hepatization was detected in the entire lobe of the pneumonic lungs of the 70 cases (26.72%) evaluated as FP. Generally, pleuritis developed and pleura frequently adhered to the costal surfaces. There was fibrinous exudation on the cut surfaces of the lungs. Microscopically, interlobular septa and pleura expanded because of fibrinous and neutrophilic exudation. Lymphatic capillaries were obstructed with fibrin thrombosis. Hyperemic, fibrinous, and neutrophilic areas could be seen together in the same section (Figure 2). Interlobular capillaries were enlarged, but hyperemia disappeared in the latest periods. In 39 of the 70 cases, some pathogenic bacteria were isolated: *Mannheimia haemolytica* (n = 27), *E. coli* (n = 7), and *Pasteurella multocida* (n = 5).

Fibrinous Necrotic Bronchopneumonia (FNBP):

Fibrinous pneumonia with necrotic changes (n = 15 cases, 5.73%) was described as FNBP in this study. Neutrophilic exudation with necrosis was prominent. Interlobular septa enlarged and pleuritis developed because of fibrinous exudation. *Mannheimia haemolytica* was the most isolated bacteria in this form (n = 7) and *Pasteurella multocida* was detected in 2 other cases.

Interstitial Pneumonia (IP):

In IP (n = 48 cases, 18.32%), lungs were voluminous and enlarged. Rib impressions were seen on the surfaces of the affected lungs. Histologically, lesions were characterized by a marked increase in mononuclear cells in the interalveolar septa and presence of varying numbers of macrophages within the alveolar lumina. Peribronchial and peribronchiolar proliferation of lymphocytes was detected in many interstitial pneumonitis (Figure 3). Peribronchiolar and peribronchial lymphocytic proliferation were prominent in 16 cases; however, in the other 21 cases, fibrous and mononuclear cell proliferations were more prominent in interalveolar septa. In 11 cases with thickening of the alveolar septa, neutrophilic exudation was also observed within the alveolar lumina, and this type was called atypical interstitial pneumonia or broncho-interstitial pneumonia. Bronchiolitis obliterans were detected in 3 lungs. *E. coli* (n = 7), *Mannheimia haemolytica* (n = 6), and *Pasteurella multocida* (n = 1) were isolated in 14 of 48 IP cases.

Verminous Pneumonia:

Verminous pneumonia was detected in 20 (7.63%) lungs. Parasitic lesions were localized on the diaphragmatic lobes, caudal-dorsal surfaces of the lungs,

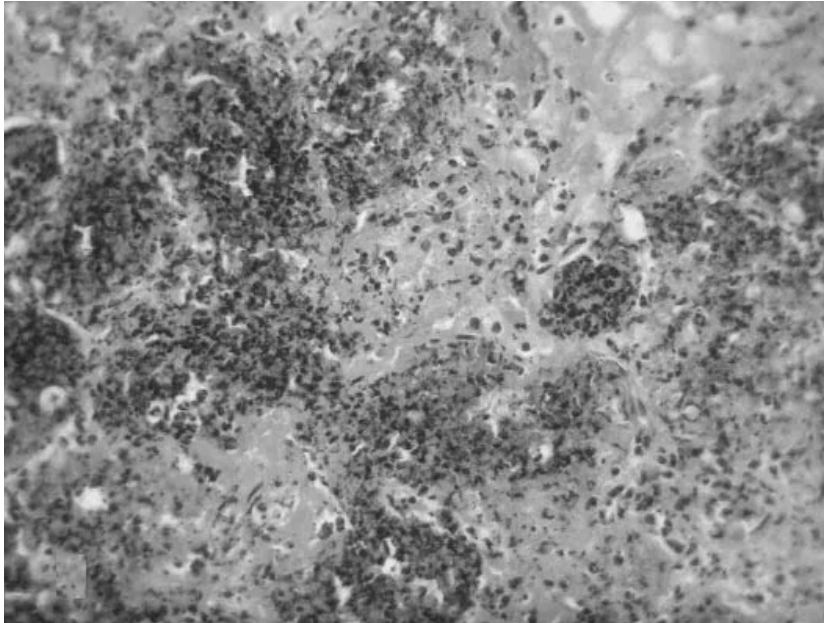


Figure 2. Lamb lung, fibrinous pneumonia. Severe fibrinous and neutrophilic exudation within the alveoli. *Mannheimia haemolytica* was isolated from this case. H-E.

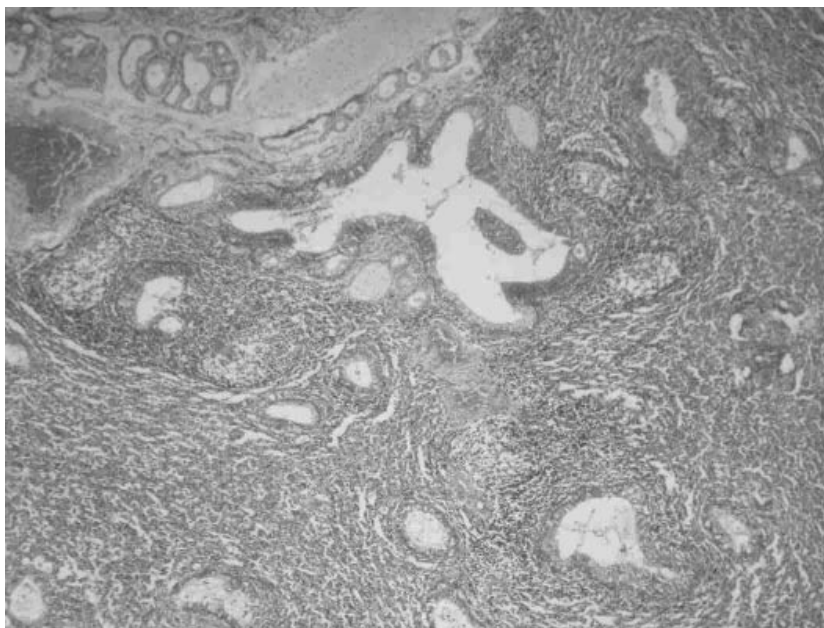


Figure 3. Lamb lung, interstitial pneumonia. Peribronchial and peribronchiolar lymphoid infiltration. Pathogenic bacterium was not isolated from this case. H-E.

and it was emphysematous, varying in size and grayish in appearance. Microscopically, similar lesions were observed with interstitial pneumonia, but parasitic structures varying in size and shaped were detected in the alveolar and bronchiolar lumina. In addition, fibro-

muscular hypertrophy generally developed in this type. Only one bacterium was isolated from this pneumonia and it was *Corynebacterium* spp. The incidence rates of the different types of pneumonias and bacteria are displayed in the Table.

Table. The incidences of pneumonia types and bacteria isolated from these types.

Type of pneumonia	<i>M. haemolytica</i>	<i>E. coli</i>	<i>P. multocida</i>	Others	Total bacteria
ACBP					
14 (17.56%)	5 (7.81%)	8 (28.57%)	1	0 (8.33%)	14 (12.29%)
CPBP					
38 (14.50%)	10 (15.63%)	5 (17.86%)	1 (8.33%)	6 (60%)	22 (19.30%)
PNBP					
25 (9.54%)	9 (14.06%)	1 (3.57%)	2 (16.67%)	2 (20%)	14 (12.29%)
FP					
70 (26.72%)	27 (42.19%)	7 (25.0%)	5 (41.67%)	0	39 (34.21%)
FNP					
15 (5.73%)	7 (10.94%)	0	2 (16.67%)	0	9 (7.90%)
IP					
48 (18.32%)	6 (9.38%)	7 (25.0%)	1 (8.33%)	1 (10%)	16 (14.04%)
VP					
20 (7.63%)	0	0	0 (10%)	1	0
Total bacteria (%)	64 (56.14%)	28 (24.56%)	12 (10.52%)	10 (8.78%)	114 (100%)

ACBP: acute catarrhal bronchopneumonia; CPBP: catarrhal purulent bronchopneumonia;

PNBP: purulent necrotic bronchopneumonia; FP: fibrinous pneumonia; FNP: fibrinous necrotic pneumonia; IP: interstitial pneumonia; VP: verminous pneumonia

Others: *Staphylococcus* sp., *Streptococcus* sp., *Corynebacterium* sp. and *Actinomyces* sp.

In this study, pneumonias were diagnosed in 262 (35.41%) of 740 dead or terminally diseased newborn to 6-month-old lambs at our institute. This result confirmed that pneumonia continues to be one of the most important causes of lamb morbidity and mortality in our region (6,15,16) and other regions of Turkey (7-9). Some pathogenic bacteria were isolated from 114 pneumonic lambs (43.51%). These data indicate that bacterial agents are still one of the most important causes of lamb pneumonia. In some cases, histopathologically detected pneumonic lesions were probably associated with a bacterial agent, although there was no bacteria isolation. This could have been due to antibiotic use before our examinations. Therefore, it was thought that bacterial agents may cause pneumonia in lambs with greater frequency than was detected in this study. *Mannheimia haemolytica* was the most frequently isolated

pathogen (64 cases, 56.14%) in the different pneumonia types, followed by *E. coli* (28 cases, 24.56%) and *Pasteurella multocida* (12 cases, 10.52%). In previous bacteriological studies (6,15,16) undertaken in our region, *E. coli* was the most commonly isolated pathogen from lamb pneumonia. The results of the present study show that *Mannheimia haemolytica* was more important in lamb pneumonia between 2000 and 2004. Similarly, recent studies (8-10) also showed that *Mannheimia haemolytica* was the prime bacteriological agent in lamb pneumonia. It was shown in this study that *Actinomyces* spp. (3 cases, 2.63%), *Pseudomonas* spp. (3 cases, 2.63%), *Staphylococcus* spp. (2 cases, 1.75%), *Corynebacterium* spp. (1 case, 0.87%), and *Streptococcus* spp. (1 case, 0.87%) rarely cause lamb pneumonia.

Histopathologically, FP (26.72%) was the most frequently observed type, followed by IP (18.32%), ACBP (17.56%), CPBP (9.54%), and verminous pneumonia (7.63%). In some studies (1,8) verminous pneumonia was reported to be the most frequently encountered pneumonia type in lambs. These data show that pneumonia types can vary from region to region, depending on different or insufficient breeding systems. Gross and histopathological appearances of pneumonia types in the present study are generally similar to those in previous reports (5-10). *Mannheimia haemolytica*, *Pasteurella multocida*, and *E. coli* were isolated from many lungs infected with different pneumonia types, including catarrhal, purulent, fibrinous, fibrinous-necrotic, and even interstitial forms; therefore, it is difficult to identify a pathogenic microorganism responsible for each pneumonia type. However, *Mannheimia haemolytica* was mostly isolated from fibrinous and fibrinous-necrotic lesions in the present study. Hyperemic and less neutrophilic changes appeared in early or mild infections, but large amounts of neutrophilic exudation, fibrinoid, or necrotic changes were noted in later stages or more severe infections. This difference may have been associated with the infection mechanism of the pathogenic bacteria, and host resistance and immunity. Bacteriological isolation of mycoplasma was not carried out. Because of this, there are no data about the role of mycoplasma on lamb pneumonia in this study. Previous reports (5,10,13,15), however, showed that mycoplasma was also one of the most important causes of lamb pneumonia.

E. coli, *Mannheimia haemolytica*, and *Pasteurella multocida* were isolated in some cases of interstitial pneumonia. These lesions were characterized by an increase in mononuclear cells of interalveolar septa, sometimes peribronchial or peribronchiolar proliferation of lymphocytes, and by the presence of a varying number

of neutrophils and/or macrophages within the alveolar lumina. It is thought that the isolation of pathogenic bacteria in interstitial pneumonias is a sign of secondary bacterial complication of a primary viral infection; thus, exudative and proliferative changes are seen together in this form. Therefore, this type was referred to a broncho-interstitial pneumonia, as in previous studies (11). Some viral agents play a very important role in lamb pneumonia with regard to the onset of infection (5,11). Yet, in the present study, the correlation between viruses and bacteria was not determined in interstitial or broncho-interstitial pneumonias. A pathogenic bacterium was isolated in only one case of verminous pneumonia. No correlation between bacterial microorganisms and parasitic pneumonia was noted.

It is concluded that pneumonia continues to be one of the most important causes of lamb morbidity and mortality in our region. *Mannheimia haemolytica* (56.14%), *E. coli* (24.56%), and *P. multocida* (10.52%) were determined to be the most important bacterial agents of lamb pneumonia, and it was observed that these organisms caused different pneumonic lesions, which were dependent upon various factors. It is thought that the histological character of pneumonia probably changes according to its etiological character, host immunity, environmental conditions, therapeutic attempts, and disease prognosis.

Acknowledgment

This study was conducted at the Konya Veterinary Control and Research Institute between 2000 and 2004, and bacteriological examinations were performed in the institute's bacteriology laboratory. The author thanks the personnel of the Bacteriology Department who were present during this period.

References

1. Bekele, T., Kasali, O.B., Woldeab, T.: Causes of lamb morbidity and mortality in the Ethiopian highlands. *Vet. Res. Commun.*, 1992; 16: 415-424.
2. Rook, J.S., Scholman, G., Wing-Proctor, S., Shea, M.: Diagnosis and control of neonatal losses in sheep. *Vet. Clin. North Am. Food Anim. Pract.*, 1990; 6: 531-562.
3. Daniel, J.A., Held, J.E., Brake, D.G., Wulf, D.M., Epperson, W.B.: Evaluation of the prevalence and onset of lung lesions and their impact on growth of lambs. *Am. J. Vet. Res.*, 2006; 67: 890-894.
4. Goodwin, K.A., Jackson, R., Brown, C., Davies, P.R., Morris, R.S., Perkins, N.R.: Pneumonic lesions in lambs in New Zealand: patterns of prevalence and effects on production. *N.Z. Vet. J.*, 2005; 53: 91-92.

5. Dungworth, D.L.: The Respiratory System. In: Jubb, K.V.F., Kennedy, P.C., Palmer, N., Eds. Pathology of Domestic Animals. 3rd ed., Vol. 2, Academic Press, New York, 1985; 451-532.
6. Kıran, M.M., Berkin, Ş., Kaya, O., Dinçer, Z.: Konya bölgesi koyun pnömonilerinde patolojik ve etiyolojik araştırmalar. S. Ü. Vet. Fak. Derg., 1993; 9: 3-9.
7. Özer, H., Gülcü, H.B.: Kuzu ve oğlakların enzootik pnömonileri ile ilgili gözlemler. S.Ü. Vet. Fak. Derg., 1986; 2: 135-141.
8. Yener, Z., Gürtürk, K., Gülbahar, Y., Solmaz, H.: Bitlis mezbahasında kesilen keçilerde pnömoni olguları üzerinde patolojik ve bakteriyolojik çalışmalar. Vet. Bil. Derg., 2001; 17: 13-20.
9. Sağlam, Y.S., Bozoğlu, H., Baş A.T.: Erzurum ve çevresinde kuzu enzootik pnömonileri üzerinde bakteriyolojik ve patolojik incelemeler. Etlik Vet. Mikrobiyol. Derg., 1997; 10: 1-17.
10. Haziroglu, R., Diker, K.S., Gulbahar, M.Y., Akan, M., Guvenc, T.: Studies of the pathology and microbiology of pneumonic lungs of lambs. Dtsch. Tierarztl. Wochenschr., 1994; 101: 441-443.
11. Oros, J., Fernandez, A., Rodriguez, J.L., Rodriguez, F., Poveda, J.B.: Bacteria associated with enzootic pneumonia in goats. J. Vet. Med. B., 1997; 44: 99-104.
12. Lehmkuhl, H.D., Contreras, J.A., Cutlip, R.C., Brogden, K.A.: Clinical and microbiologic findings in lambs inoculated with *Pasteurella haemolytica* after infection with ovine adenovirus type 6. Am. J. Vet. Res., 1989; 50: 671-675.
13. Ball, H.J., Connolly, M., Cassidy, J.: *Pasteurella haemolytica* serotypes isolated in Northern Ireland during 1989-1991. Br. Vet. J., 1993; 149: 561-570.
14. Malone F.E., McCullough, S.J., McLoughlin, M.F., Ball, H.J., O'Hagan, J., Neill, S.D.: Infectious agents in respiratory disease of housed, fattening lambs in Northern Ireland. Vet. Rec., 1988; 122: 203-207.
15. Kaya, O., Erganiş, O.: Koyun ve kuzu pnömonileri üzerinde etiyolojik survey. Veterinarium, 1991; 32: 27-29.
16. Baysal, T., Güler, L.: Konya yöresindeki kuzu ve oğlakları enzootik pnömonilerinden bakteriyel etken izolasyonu. Veterinarium, 1992; 33: 1-5.
17. Quinn, P.J., Carter, M.E., Markey, B.K., Carter, G.R., Clinical Veterinary Microbiology. 2nd. Ed., Mosby, London. 1998.
18. Luna, L.G.: Manual of Histologic Staining Methods of The Armed Forces Institute of Pathology, 3rd Ed. McGraw-Hill Book Company, New York. 1968; 38-39.