

1-1-2007

## Chondroma in a Dog

RIFKI HAZIROĞLU

HASAN BİLGİLİ

KÜBRA A. TERİM KAPAKIN

Follow this and additional works at: <https://journals.tubitak.gov.tr/veterinary>



Part of the [Animal Sciences Commons](#), and the [Veterinary Medicine Commons](#)

---

### Recommended Citation

HAZIROĞLU, RIFKI; BİLGİLİ, HASAN; and KAPAKIN, KÜBRA A. TERİM (2007) "Chondroma in a Dog," *Turkish Journal of Veterinary & Animal Sciences*: Vol. 31: No. 1, Article 14. Available at: <https://journals.tubitak.gov.tr/veterinary/vol31/iss1/14>

This Article is brought to you for free and open access by TÜBİTAK Academic Journals. It has been accepted for inclusion in Turkish Journal of Veterinary & Animal Sciences by an authorized editor of TÜBİTAK Academic Journals. For more information, please contact [academic.publications@tubitak.gov.tr](mailto:academic.publications@tubitak.gov.tr).

## Chondroma in a Dog

Rıfki HAZIROĞLU<sup>1,\*</sup>, Hasan BİLGİLİ<sup>2</sup>, Kübra A. TERİM KAPAKIN<sup>3</sup>

<sup>1</sup>Department of Pathology, Faculty of Veterinary Medicine, Ankara University, Ankara - TURKEY

<sup>2</sup>Department of Surgery, Faculty of Veterinary Medicine, Ankara University, Ankara - TURKEY

<sup>3</sup>Department of Pathology, Faculty of Veterinary Medicine, Atatürk University, Erzurum - TURKEY

Received: 16.01.2006

**Abstract:** An 11-year-old female terrier brought to our clinic was diagnosed with chondroma located on the caudolateral side of the right distal humerus. During the clinical examination of the dog, swelling and lameness were observed on right forelimb. Following the operation, the subject had no lameness after removing the mass. Postoperative follow-up was done by phone with the owner of the patient in 6th and 12th months, and no lameness and swelling in the region was reported. The tumoral mass was removed easily from underlying tissue without any attachment during the operation. The tissue sample from the specimen was routinely processed and stained with Hematoxylin–Eosin for histopathological examination. The tumoral mass was 5 x 3.4 x 1.9 cm in size, 25 g in weight and hard in texture. Cross sections of the mass were white and had a multilobulated appearance surrounded by connective tissue. The histological examination showed that the tumoral mass was divided into lobules by a thin fibrous stroma. The neoplastic cells were uniform in shape and size, and they were composed of well-differentiated mature chondrocytes. While the tumoral mass was poorly vascularized with a few foci of necrotic areas, mitosis was not observed within the tumoral cells.

**Key Words:** Chondroma, dog, pathology

### Bir Köpekte Kondroma

**Özet:** 11 yaşlı Terrier ırkı dişi bir köpekte kiliniklerimizde sağ distal humerusunun kaudolateraline lokalize olan kondroma teşhisi kondu. Köpeğin klinik muayenesinde sağ ön ekstremitesinde şişkinlik ve topallık izlendi. Olgunun operasyonundan sonra kitlenin çıkarılmasını takiben topallık kalmadı. Postoperatif izleme döneminde hasta sahibi ile 6. ve 12. aylarda telefon bağlantısı yapıldı, olguda herhangi bir topallık ve bölgesel şişkinlik olmadığı bildirildi. Operasyon sırasında tümöral kitle, alt dokularla bağlantısı olmaksızın kolayca çıkarıldı. Tümöral kitlenin cerrahi olarak uzaklaştırılmasından sonra örneklerden alınan dokular rutin doku takibinden sonra histopatolojik muayene için Hematoksilen – eosin ile boyandı. Tümöral kitle sert kıvamda, 25 g ağırlığında ve 5 x 3,4 x 1,9 cm boyutlarındaydı. Kitlenin kesit yüzü beyaz renkte ve konnektif bir doku ile çevrili multilobüler bir görünüme sahipti. Histolojik muayenede tümöral kitlenin, ince fibröz bir doku ile lobüllere bölündüğü gözlemlendi. Neoplastik hücreler üniform şekil ve büyüklükte, iyi differansiye olgun kondrositlerden oluşmuştu. Tümöral kitle damarlardan yoksun, birkaç nekrotik bölgeye sahip iken tümör hücrelerinde mitozis gözlenmedi.

**Anahtar Sözcükler:** Kondroma, köpek, patoloji

Chondromas are benign neoplasms that have elements of mature hyaline cartilage (1-3). Primary chondromas of bone are divided into enchondromas and ecchondromas. The former type originates from the medullary cavity of the bone (1,3,4), while the latter arises from cartilage anywhere in the skeleton (1,3).

Enchondroma in humans occurs mainly in the hand bones of especially the proximal phalanges, but few cases

in animals have been reported. The localization of the enchondroma reported in animal species was the proximal phalanx of a dog (1) and the distal tibia and distal fifth metatarsal (4) of a rhesus monkey. Ecchondroma occurs in flat bones more often than in long bones (1,2,5,6), including turbinates and sternocostal cartilage complexes (1). Chondromas have rarely been reported in animals (4,5,7-10), but a detailed description

\*E-mail: hazirogl @veterinary.ankara.edu.tr

of chondroma was given in sheep and dogs by Sullivan (7).

Within the last 72 years, cases of chondroma including the present were diagnosed only in 3 dogs brought to the Department of Pathology, Faculty of Veterinary Medicine, Ankara University. The subjects involved in these cases were a Belgian shepherd, a German shepherd, and a terrier. Here, we described the clinical and histopathological features of chondroma diagnosed on the caudolateral side of the right distal humerus in an 11-year-old female terrier.

The terrier was brought to our clinic in the Department of Surgery, Faculty of Veterinary Medicine, Ankara University, with the complaint of right forelimb lameness. The tumoral mass had developed on the caudolateral side of the right distal humerus (Figure 1)

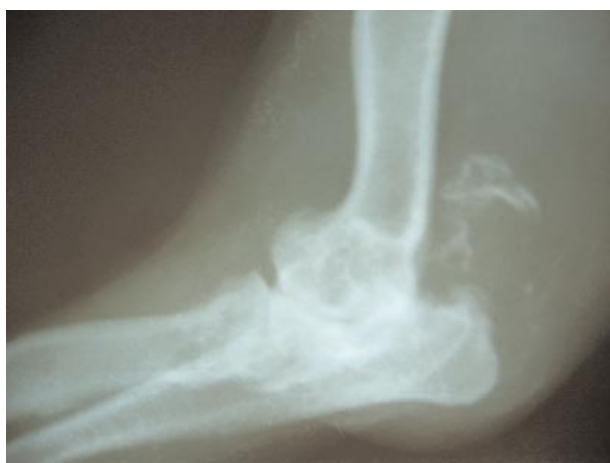

Figure 1. Radiographic view of the near olecranon and caudolateral side of the right distal humerus.

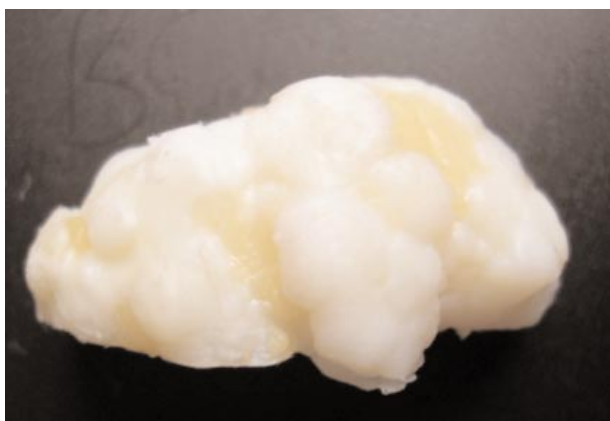

Figure 2. Macroscopic appearance of the tumoral mass.

over the course of 6 months. Swelling and lameness were observed at the clinical examination. Under general anesthesia, the tumoral mass was surgically removed via a lateral approach to the elbow joint.

The tumoral mass was 5 x 3.4 x 1.9 cm in size, 25 g in weight and hard in texture. Cross section of the mass showed white (Figure 2) and multilobulated lobules surrounded by a capsule of connective tissue.

For the histopathologic examination, a specimen was initially fixed in 10% buffered formalin solution and then decalcified with 10% nitric acid solution. After being processed routinely, tissue samples were embedded in paraffin wax, cut to 5 mm thickness and stained with Hematoxylin-Eosin (HE).

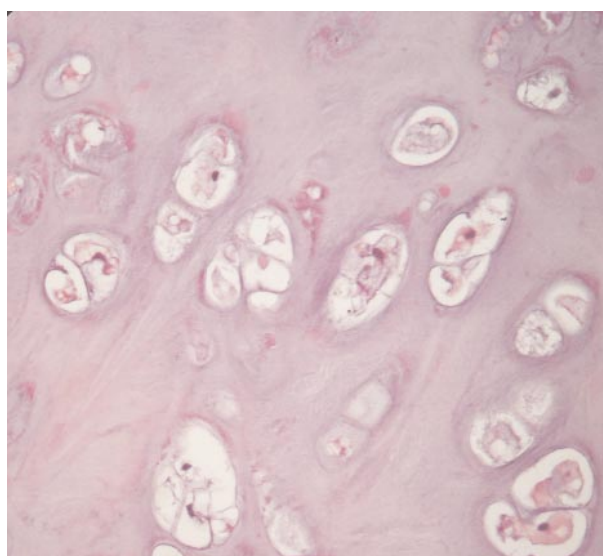


Figure 3. Well-differentiated mature chondrocytes. HE, x 400.

The histopathologic examination revealed that the tumoral mass was divided into randomly scattered lobules. The cells within the tumoral mass were composed of well-differentiated, uniformly shaped and sized mature chondrocytes containing an ovoid, pleomorphic or pyknotic nucleus (Figure 3) surrounded by a vacuolar cytoplasm. The tumoral mass was poorly vascularized with a few foci of necrotic areas. Mitosis was not observed within tumoral cells.

Chondromas are rarely seen in domestic animals (4,5,7-11). Sullivan described chondromas in several domestic animals, especially in older dogs and sheep (7). No breed or sex predilections were indicated (1,3). In our

case, chondroma was detected in an 11-year-old female terrier.

Enchondroma occurs in flat bones more often than in long bones (1,2,5,6), such as in turbinates and sternocostal cartilage complexes (1,3). Contrary to previous reports, we observed this tumoral mass on the caudolateral side of the right distal humerus.

Clinical signs are associated with the size and localization of the tumors. Although the lesions could become quite large, they are usually asymptomatic or accompanied by painless swellings (1,3). Usually, these tumors grow slowly, producing minor bone deformations (1,2,11). During the clinical examination of the dog, swelling and lameness were observed. Following the operation, the subject had no lameness after the mass was removed. Postoperative follow-up was done by phone calls to the owner of the patient at 6 and 12 months, and no lameness or swelling in the region was reported.

Chondromas are multilobular structures variable in size surrounded by a fibrous capsule. On cut surface, the color of chondromas ranges from bluish white to milk white (1,3,11). The surrounding skin may show ulceration and suppurative exudation along with invasion of the adjacent venous vessels by the extensive growth of the tumoral mass (1,3). Chondromas consist of irregular

lobules of hyaline cartilage. Neoplastic cartilage is composed of chondrocytes tending to be rather uniform in size and shape and sitting in the matrix that on occasions has more fibrous stroma than in normal hyaline cartilage (1-3,5,11). The macroscopic and microscopic findings of this neoplasm were similar to those in previously published articles.

It is not easy to differentiate chondromas from trauma or degenerative articular alterations and chondrosarcomas. However, abundance of cellularity, presence of cells with large or double nucleuses in chondrosarcomas and the observation of pleomorphism and mitosis are differentiating factors in both cases (1,2). Observation of these findings in our case supports the correctness of the chondroma diagnosis.

It was reported that the occurrence of chondromas is rare (4,5,7-11). Similar to the reports, 3 cases were diagnosed as chondroma in the Department of Pathology, Faculty of Veterinary Medicine, Ankara University, over the last 72 years, which confirms the fact that chondromas are rare.

In conclusion, considering the historical background and reported cases, chondroma is rarely encountered. Despite the rare occurrence, this case study showed that it is possible to see this type of neoplastic growth with an unusual localization in animals.

## References

1. Thompson, K.G., Poll, R.R.: Tumors of bones. In: Meuten, D.J., Ed. *Tumors in Domestic Animals*. Fourth Ed. Iowa State Press. 2002; 259-261.
2. Milli, U., Hazıroğlu, R.: Kemik, Eklem, Kas, Tendo ve Aponözrozlar. In: *Veteriner Patoloji*, 1997: 403.
3. Poll, R.R.: Tumors of bones and cartilage. In: Moulton J. E., Ed., *tumors in Domestic Animals*. Third Ed. Univ. of California Press, 1990; 173-175.
4. Silverman, J., Weisbrode, S.E., Myer, C.W., Biler, D.S., Kerpsack, S.J.: Enchondroma in a rhesus monkey. *J. Am. Vet. Med. Assoc.*, 1994; 204: 786-788.
5. Hamilton, J.M., Kight, D.: Cartilaginous tumors in dogs: a description of two cases with a review of the literature. *Vet. Rec.*, 1973; 92: 41-43.
6. Ling, G.V., Morgan, J.P., Pool, R.R.: Primary bone tumors in the dog: a combined clinical, radiographic, and histologic approach to early diagnosis. *J. Am. Vet. Med. Assoc.*, 1974: 165: 55-67.
7. Sullivan, D.J.: Cartilagenous tumors (chondroma and chondrosarcoma) in animals. *Am. J. Vet. Res.*, 1960; 21: 531-538
8. Ertürk, E., Tanzer, F., Bulucu, F.: Patolojik anatomi Kürsüsünde 1964-1970 yılları arasında incelenen köpek ve kedi tümörleri. *Ankara Üniv. Vet. Fak. Derg.*, 1971; 18: 383-386.
9. Kutsal, O., Kaya, Ü., Vural, S., Sağlam, M.: Köpek ve kedilerde 1986-2000 yılları arasında Ankara'da incelenen kemik tümörleri. *Turk. J. Vet. Anim. Sci.*, 2003; 27: 109-115.
10. Pamukçu, A.M., Ertürk, E.: Ankarada görülen tümör çeşitleri. *Ankara Üniv. Vet. Fak. Derg.*, 1962; 9: 1-9.
11. Doige, C.E., Weisbrode, S.E.: Diseases of bone and joints. In: Carlton, W.W., McGavin, M.D. Eds., *Thomson's Special Veterinary Pathology*. Second ed., 1995; 446.