

1-1-2007

## Cystocaulus ocreatus Infection in Anatolian Wild Sheep and Dwarf Goats

NALAN KABAĞCI

KADER YILDIZ

SİBEL YASA DURU

MURAT YARIM

Follow this and additional works at: <https://journals.tubitak.gov.tr/veterinary>



Part of the [Animal Sciences Commons](#), and the [Veterinary Medicine Commons](#)

---

### Recommended Citation

KABAĞCI, NALAN; YILDIZ, KADER; DURU, SİBEL YASA; and YARIM, MURAT (2007) "Cystocaulus ocreatus Infection in Anatolian Wild Sheep and Dwarf Goats," *Turkish Journal of Veterinary & Animal Sciences*: Vol. 31: No. 5, Article 1. Available at: <https://journals.tubitak.gov.tr/veterinary/vol31/iss5/1>

This Article is brought to you for free and open access by TÜBİTAK Academic Journals. It has been accepted for inclusion in Turkish Journal of Veterinary & Animal Sciences by an authorized editor of TÜBİTAK Academic Journals. For more information, please contact [academic.publications@tubitak.gov.tr](mailto:academic.publications@tubitak.gov.tr).

## ***Cystocaulus ocreatus* Infection in Anatolian Wild Sheep and Dwarf Goats**

Nalan KABAKCI<sup>1,\*</sup>, Kader YILDIZ<sup>2</sup>, Sibel YASA DURU<sup>3</sup>, Murat YARIM<sup>4</sup>

<sup>1</sup>Department of Pathology, Faculty of Veterinary Medicine, Kırıkkale University, 71450 Yahşihan, Kırıkkale - TURKEY

<sup>2</sup>Department of Parasitology, Faculty of Veterinary Medicine, Kırıkkale University, 71450 Yahşihan, Kırıkkale - TURKEY

<sup>3</sup>Department of Internal Medicine, Faculty of Veterinary Medicine, Kırıkkale University, 71450 Yahşihan, Kırıkkale - TURKEY

<sup>4</sup>Department of Pathology, Faculty of Veterinary Medicine, Ondokuz Mayıs University, Samsun - TURKEY

Received: 19.10.2007

**Abstract:** An Anatolian wild sheep (*Ovis orientalis anatolica*) from a wild ruminant farm near Kırıkkale, Turkey, was necropsied. Parasitic nodules were situated beneath the pleura of the caudodorsal lobes of the lungs. First stage larvae of *Cystocaulus ocreatus* were detected both in bronchial fluid and in lung paraffin sections. Clinical and parasitological examinations of the other animals (4 dwarf goats and 3 wild sheep reared on the same farm) were also performed. First stage larvae of *C. ocreatus*, and eggs of *Nematodirus* spp. and *Strongyloides* spp. were observed in coproscopic examination. Anthelmintic treatment, Rabenzole® (rafoxanide and thiabendazole, Topkim), was administered to the animals infected by parasites. At the end of the treatment the combination of rafoxanide and thiabendazole was found to be markedly effective for the treatment of lungworm infection and no parasitic eggs were detected in the faeces of any of the treated animals.

**Key Words:** Anatolian wild sheep, dwarf goat, *Cystocaulus ocreatus*, lungworm, *Ovis orientalis anatolica*

### **Anadolu Yaban Koyunu ve Cüce Keçilerde *Cystocaulus ocreatus* İnfeksiyonu**

**Özet:** Kırıkkale civarındaki bir yabani hayvan çiftliğinden getirilen Anadolu yaban koyununa (*Ovis orientalis anatolica*) nekropsi yapılmış ve akciğerin kaudodorsal loblarının pleuraya yakın kısımlarında parazit nodülleri tespit edilmiştir. Anadolu yaban koyununun bronşiyal sıvı ve enfekte akciğer dokusundan hazırlanan histolojik kesitlerde *Cystocaulus ocreatus*'un 1. dönem larvası görülmüştür. Aynı çiftlikte yaşayan diğer hayvanlarda (4 yaban keçisi ve 3 yaban koyunu) enfeksiyonun tespiti için klinik ve parazitolojik inceleme yapılmıştır. Hayvanlarda *C. ocreatus* larvası, *Nematodirus* spp. ve *Strongyloides* spp. yumurtası tespit edilmiştir. Enfekte hayvanlara Rabenzole® (rafoksanid tiabendazol kombinasyonu, Topkim) tablet verilmiştir. Tedavi periyodunun sonunda rafoksanid tiabendazol kombinasyonu bu yabani hayvanların akciğer kılkurdu enfeksiyonunda belirgin şekilde başarılı bulunmuştur.

**Anahtar Sözcükler:** Anadolu yaban koyunu, cüce keçi, *Cystocaulus ocreatus*, akciğer kılkurdu, *Ovis orientalis anatolica*

### **Introduction**

Anatolian wild sheep (*Ovis orientalis anatolica*) phylogenetically belong to a subspecies of Asian mouflon. Although this species is endemic throughout Turkey, their presence, with dense populations, has been established, especially around Bozdağ province in Central Anatolia. It is thought that Anatolian wild sheep originated from domestic sheep (1).

*Cystocaulus ocreatus* (protostrongylidae) is a small lungworm that occurs in the lung parenchyma and in subpleural nodules of small ruminants. The land snail acts as the intermediate host in the life cycle of the parasite, and swallowing the intermediate host with its food infects sheep. The infective larvae usually reach the lung by the hepatic portal system or lymphatic drainage. The parasite moults twice in interstitial tissue of the lung and migrates

\* E-mail: nalankabakci@yahoo.com

to the alveolar ducts (2,3). *C. ocreatus* forms both worm knots and brood-type nodules in the lung parenchyma. Worm knots in subpleural nodules of the lung, including *C. ocreatus*, generally are brown to black and the size of a pin head. Brood-type nodules contain mature *C. ocreatus* in large numbers and first stage larvae. These nodules are grey and walnut sized, and can be seen in the parenchyma as well as in interstitial lung tissue (3). The severity of infection can be assessed quite accurately by superficial inspection (4).

There are only a few reported cases of parasitic infection of wild ruminant species (5-8). Similarly, the number of reported cases related to protostrongylid species in wild animals is limited (7,8). In the present study, clinical, parasitological, and pathological findings of *C. ocreatus* infection in an Anatolian wild sheep, as well as anthelmintic therapy administered to the other infected animals on the same farm are described.

## Materials and Methods

A 2-year-old female Anatolian wild sheep (*Ovis orientalis anatolica*) that was in agony before dying was brought to the Pathology Department for necropsy. This sheep came from a wild ruminant farm near Kırıkale, Turkey. The number and localisation of the grossly visible lesions and nodules detected in the lungs were recorded. The grossly visible lesions in the lungs were dissected with a lancet. The parasitological examination of the small amount of bronchial fluid obtained by squeezing the lungs was performed under a light microscope. Then, the trachea and bronchial branches were opened with scissors.

The tissues of the sheep were immediately fixated in 10% buffered formalin overnight at 4 °C. Subsequently, the tissues were dehydrated in ethanol and xylene, and embedded in paraffin wax. We stained 5- $\mu$ m thick sections with haematoxylin and eosin. Separate samples of lung, liver, spleen, and kidney were collected for microbiological analysis.

Clinical and parasitological examinations were also conducted on the other animals (4 dwarf goats and 3 wild sheep reared on the same farm). Faeces samples were collected for parasitological examination and processed with Baermann, sedimentation, and flotation methods. Rabenzole<sup>®</sup> (150 mg rafoxanide and 2000 mg

thiabendazole) was given to each animal, only once, at the dose of one pill per 20 kg bodyweight for anthelmintic therapy. For secondary bacterial infections, Synulox<sup>®</sup> suspension (140 mg amoxicillin trihydrate and 35 mg potassium clavulanate) and Nervit<sup>®</sup> solution (100 mg vitamin B<sub>1</sub> and 10 mg vitamin B<sub>6</sub>) were administered intramuscularly over 1 week at the dose of 1 ml per 20 kg bodyweight and 2 ml per animal, respectively. At the end of the treatment period (15th day), a faecal examination was performed and we compared the differences in larval counts obtained with the Baermann method. Statistical analysis was not performed because the number of animals was limited.

## Results

The pathological changes in the lungs of the Anatolian wild sheep were prominent in necropsy. The most prominent lesions in the lungs were parasitic nodules, which were situated beneath the pleura of the dorsocaudal lobes. In all, 7 grey 1-2 cm nodules were observed in the lungs. Some of them projected over the pleural surface. First stage larvae of *C. ocreatus* were observed in both bronchial fluid and in histological sections of the infected lung tissues (Figures 1 and 2). These parasitic lesions were considered brood-type nodules. Lymphocytic infiltration was seen around the blood vessels, bronchioles, and alveolar septa. A mild fibrous thickening of the alveolar septa was prominent in some areas of the lungs. The epithelium of the bronchioles was hyperplastic and the muscularis mucosa of the bronchioles was thick.

In addition to above findings, the heart was hypertrophic and many white ulcers 2-3 mm long were observed in the mucosal surface of the small intestine. In the microbiological examination, *Fusobacterium necrophorum* was isolated from tissue samples of the Anatolian wild sheep.

On clinical examination, the wild dwarf goat from the same farm that presented with a history of anorexia, weakness, diarrhoea, and respiratory distress revealed sero-mucous discharge from the eyes and nose, listlessness related to anorexia, and mild dehydration due to diarrhoea. Crackles, severe coughing, polypnea, and inspiratory and expiratory distress were the other clinical findings.

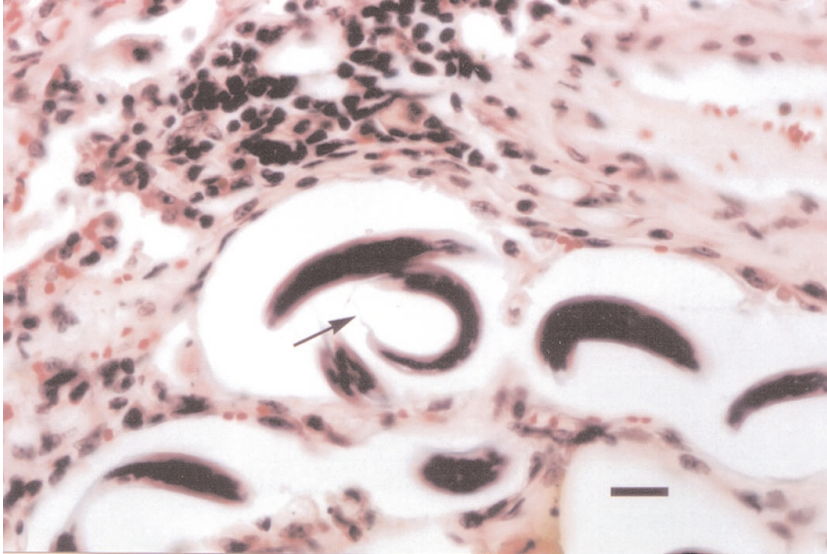


Figure 1. *Cystocaulus ocreatus*: Tissue section of the lung showing larvae in the alveolus (arrow) and cellular infiltration (bar: 156 mm).

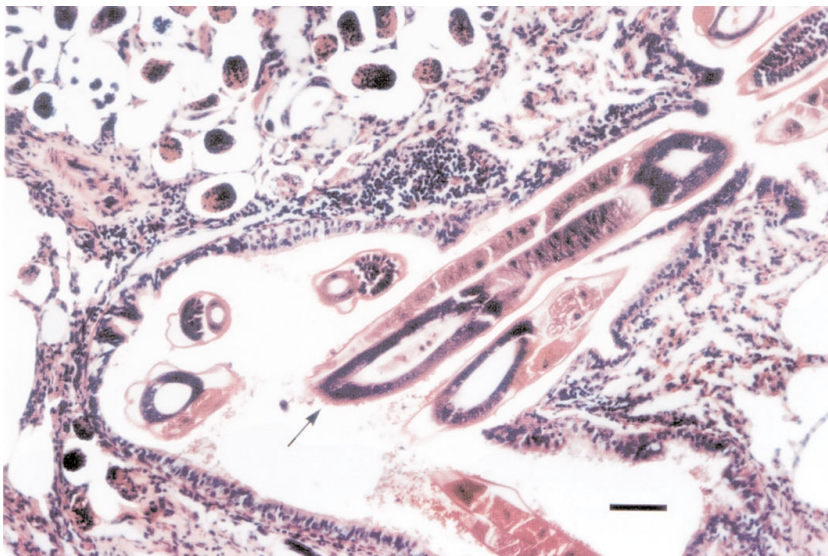


Figure 2. Adult *C. ocreatus* in the lung section (arrow) (bar: 78 mm).

Faeces samples were watery and dark. First stage larvae of *C. ocreatus*, and eggs of *Nematodirus* spp. and *Strongyloides* spp. were detected by coproscopic examination.

The affected ruminants responded to anthelmintic and antibiotic treatment. At the end of the treatment period, the frequency of clinical signs gradually decreased and then later disappeared completely. The lungworm larvae were no longer observed in the faeces of the treated animals.

## Discussion

The infection of *C. ocreatus* in sheep is widely recognised in Turkey (9-11). It was reported that *C. ocreatus* was also found in domestic sheep in Kirikkale province and the lungworm was found in 34% of Akkaraman sheep with necropsy. Thus, *C. ocreatus* was found to be the dominant lungworm species in this region (11). The source of infection in these Anatolian wild

sheep was most likely infected Akkaraman sheep brought to that region for pasture.

The number of brood-type nodules indicated the severity of infection (4). In the present study, 7 *C. ocreatus* brood-type nodules were detected in the necropsied Anatolian wild sheep. Some researchers suggest that more than 4 brood nodules observed in the lungs indicates a severe infection (4); thus, the nodules seen in the necropsied case can be considered an indication of severe infection, which highlights the seriousness of the ongoing infection on the farm.

Protostrongylus species can result in bronchitis or pneumonia, or both, and predispose animals to pulmonary bacterial and viral infections. Diminished weight gain has been reported in severely infected lambs (2). Thus, *C. ocreatus* infection may not have been the only cause of death in the presented case, partly due to its more restricted localisation in the lungs. However, *F. necrophorum* was isolated in some organs in this wild sheep. It was certain that secondary bacterial infection by *F. necrophorum* increased the severity of the *C. ocreatus* infection in the presented case.

Parasitic eggs and first stage larvae were found in the alveolar spaces of the lungs with histopathological examination. These parasitic forms may provoke inflammatory response and this cellular reaction reflects the stage of the parasite and resistance of the host (2). In this study, lymphocytic infiltration around the blood vessels, bronchioles, and alveolar septa was prominent. A mild fibrous thickening of the alveolar septa was seen in affected areas of the lungs. The epithelium of some bronchioles was hyperplastic and the muscularis mucosa of these bronchioles was thick; thus, these parasites were first stage larvae.

## References

1. Kaya, M.A.: The Morphology, Increase in Weight, Development of Teeth and Horn of Anatolian wild Sheep, *Ovis Orientalis Anatolica Valenciennes 1856*, Living in Bozdağ of Konya, 1991; 15: 135-149.
2. Jubb, K.V.F., Kennedy, P.C., Palmer, N.: *Pathology of Domestic Animals*. Academic Press. Inc., California, Vol 2, 1993, pp 680-682.
3. Schnieder, T.: Helminthosen der Wiederkäuer, In: Rommel, M., Eckert, O., Kutzer, E., Körting, W., Schnieder, T. Eds. *Veterinärmedizinische Parasitologie 5.*, Vollständig neuarbeitete Auflage, Parey Buchverlag, Berlin, 2000, pp 192-295.
4. Berrag, B., Cabaret, J.: Assessment of the severity of natural infections of kids and adult goats by small lungworms (Protostrongylidae, Nematoda) using macroscopic lesion scores. *Vet. Res.*, 1997; 28: 143-148.
5. Sevcik, B., Kinkorova, J., Danek, J., Strakova, J., Dvorak, M., Lamka, J.: Combined preparation of rafoxanide and mebendazole against parasitoses of wild ruminants. *Biologizace a chemizace Zivocisne Vyroby-Veterinaria*, 1986; 22: 151-171. (in Czech with an abstract in English).
6. Lamka, J., Simon, I., Capkova, J., Vysloulil L.: Efficacy of two- and four-day treatments with rafendazol premix spofa in game animals. *Veterinarstvi*, 1990; 40: 501-502.

7. Nocture, M., Cabaret, J., Hugonnet-Chapelle, L.: Protostrongylid nematode infection of chamois (*Rupicapra rupicapra*) at the Bauges massif (French Alps). *Vet. Parasitol.*, 1998; 77: 153-161.
8. Taşan, E., Köroğlu, E., Altaş, M.G.: Elazığ bölgesinde koyunlarda akciğer kılkuurtlarının yayılışı. *Fırat Üniv. Sağlık Bil. Derg.*, 1997; 11: 273-276.
9. Sevinç, F., Güçlü, F., Uslu, U.: Anadolu yaban koyununda (*Ovis orientalis anatolica*) bulunan parazitler. *Erciyes Univ. Vet. Fak. Derg.*, 2004; 1: 87-89.
10. Değer, S., Biçek, K., Akdemir, C., Taş, Z.: Van belediye mezbanasında kesilen koyunlarda akciğer kılkuurtlarının yayılışı. *Yüzüncü Yıl Üniv. Vet. Fak. Derg.*, 2000; 11: 11-13.
11. Yıldız, K.: Prevalence of lungworm infection in sheep and cattle in Kırıkkale province. *T. Parazitol. Derg.*, 2006; 30: 190-193.
12. Berrag, B., Cabaret J.: Impaired pulmonary gas exchange in ewes naturally infected by small lungworms. *Int. J. Parasitol.*, 1996; 26: 1397-1400.
13. Bürger, H.J.: Protostrongylidosen von von Schaf und Ziege. In: Eckert, J., Kutzer, E., Rommel, M., Bürger, H.J., Körting, W., (Eds.). *Veterinarmedizinische Parasitologie*, 4. vollst, Verlag Paul Parey, Berlin, 1992; pp. 307-314.
14. Eslami, A.H., Anwar, M.: Activity of fenbendazole against lungworms in naturally infected sheep. *Vet. Rec.*, 1976; 99: 129.
15. Jones, L.C., Worley, D.E.: Use of fenbendazole for long-term control of protostrongylid lungworms in free-ranging Rocky Mountain bighorn sheep. *J. Wildl. Dis.*, 1997; 33: 365-367.
16. Rehbein, S., Visser, M.: Efficacy of ivermectin delivered via a controlled-release capsule against small lungworms (Protostrongylidae) in sheep. *J. Vet. Med. B, Infect. Dis. Vet. Public Health*, 2002; 49: 313-316.
17. Papadopoulos, E., Sotiraki, S., Himonas, C., Fthenakis, G.C.: Treatment of small lungworm infestation in sheep by using moxidectin. *Vet. Parasitol.*, 2004; 121: 329-336.