

1-1-2008

The Prevalence of Sheep Liver Trematodes in the Northwest Region of Iran

MOHAMMAD H. MOVASSAGH GHAZANI

MOHAMMAD R. VALILOU

ALI R. AHMADZADEH

AMIR R. KARAMI

KHADIJEH ZIRAK

Follow this and additional works at: <https://journals.tubitak.gov.tr/veterinary>



Part of the [Animal Sciences Commons](#), and the [Veterinary Medicine Commons](#)

Recommended Citation

GHAZANI, MOHAMMAD H. MOVASSAGH; VALILOU, MOHAMMAD R.; AHMADZADEH, ALI R.; KARAMI, AMIR R.; and ZIRAK, KHADIJEH (2008) "The Prevalence of Sheep Liver Trematodes in the Northwest Region of Iran," *Turkish Journal of Veterinary & Animal Sciences*: Vol. 32: No. 4, Article 12. Available at: <https://journals.tubitak.gov.tr/veterinary/vol32/iss4/12>

This Article is brought to you for free and open access by TÜBİTAK Academic Journals. It has been accepted for inclusion in Turkish Journal of Veterinary & Animal Sciences by an authorized editor of TÜBİTAK Academic Journals. For more information, please contact academic.publications@tubitak.gov.tr.

The Prevalence of Sheep Liver Trematodes in the Northwest Region of Iran

Mohammad H. MOVASSAGH GHAZANI^{1,*}, Mohammad R. VALILOU²,

Ali R. AHMADZADEH³, Amir R. KARAMI⁴, Khadijeh ZIRAK⁴

¹Department of Food Hygiene, Islamic Azad University, Shabestar Branch - IRAN

²Department of Veterinary Pathology, Islamic Azad University, Shabestar Branch - IRAN

³Faculty of Agriculture, Islamic Azad University, Shabestar Branch - IRAN

⁴Faculty of Veterinary Medicine, Islamic Azad University, Shabestar Branch - IRAN

Received: 09.01.2007

Abstract: This study was carried out to determine the prevalence of liver fluke infection in sheep in the northwest region of Iran (municipal slaughterhouse of Tabriz). The study included the livers of 140 sheep that were collected by systematic random sampling. The prevalence rate of *Fasciola hepatica* and *Dicrocoelium dendriticum* was 8.57% and 20%, respectively.

Key Words: Prevalence, *Fasciola hepatica*, *Dicrocoelium dendriticum*, sheep, Iran

The trematodes *Fasciola hepatica* and *Dicrocoelium dendriticum* are recognized as the most important helminthic parasites of sheep, causing economic losses to ranchers due to reductions in milk and meat production, condemnation of parasitized livers, abortion, increased mortality, and the expense of control measures. In Iran, the main enzootic area of sheep liver trematodes lies in the north of Iran, but *Fasciola* spp. and *D. dendriticum* also occur in the northwest region of Iran. *Fasciola* spp. and *D. dendriticum* are found in many parts of the world (1,2). In chronic infections, these parasites cause biliary cirrhosis in the livers of cattle and sheep, leading to economic losses (3). In the last decade various studies about the prevalence of fasciolosis and dicrocoeliasis in cattle and sheep have been conducted in different parts of Iran (4).

Only one study (1), conducted in Tabriz, reported the prevalence rates of these infections in sheep, but the study did not include animals that came only from the northwest region of Iran.

In the present study sheep livers were investigated pathologically at the municipal slaughterhouse of Tabriz, Iran. All sheep were managed on a semi-intensive system.

The study was conducted from July 2004 to September 2004. Samples were collected from 140 sheep (systematic random sampling). Livers were examined according to the method described by Ogambo-Ongoma (5) and the parasites were identified by their morphological characteristics (2,6). For histopathological examination, all samples were fixed in 10% formalin buffer, processed with routine H&E staining.

In all, 2 species of liver fluke, *F. hepatica* and *D. dendriticum*, were encountered in this study. About 10-12 *D. dendriticum* and 3-4 *F. hepatica* were obtained from 1 liver cutting surface. The number of examined and infected animals, and the prevalence rates are given in the Table.

Major changes in the livers of sheep infected with *F. hepatica* were fibroplasias and cellular infiltration of Glisson's capsule, accompanied by granulomas in the parenchyma beneath the partial surface (Figure 1). The histopathological effect of *D. dendriticum* was similar to that *F. hepatica*, but to a lesser degree (Figure 2). In the present study, these alterations were encountered in all cases (7-9).

* E-mail: Movassagh2@yahoo.com

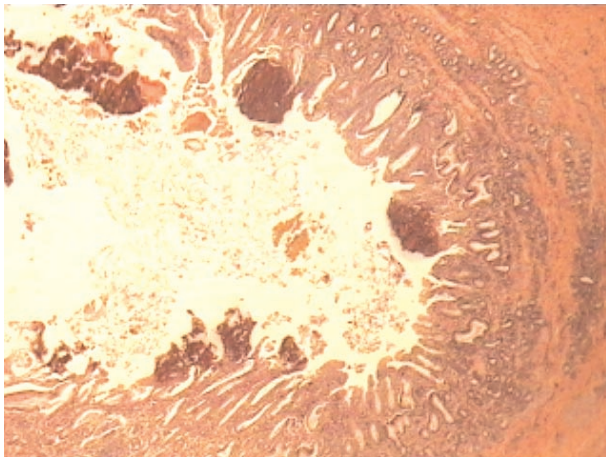


Figure 1. Hyperplasia of the bile duct and infiltration of eosinophils in a sheep liver infected with *F. hepatica* (66×, H&E).

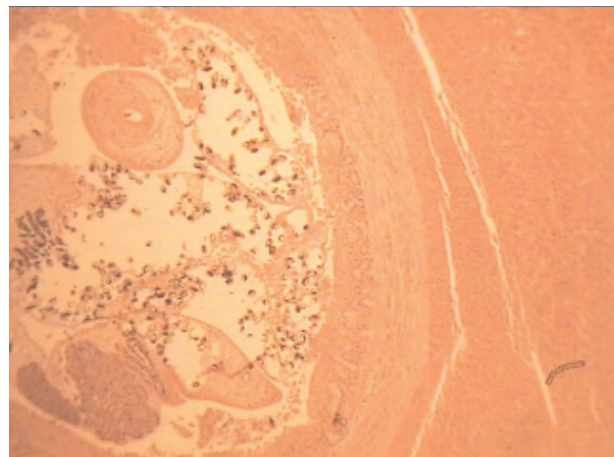


Figure 2. Hyperplasia of the bile duct in a sheep liver infected with *D. dendriticum*, (66×, H&E).

Table. Prevalence rates (%) of liver fluke infection in slaughtered sheep.

Age (year)	Sheep					
	Animals examined (n)	<i>F. hepatica</i> infected (n)	<i>F. hepatica</i> infected (%)	<i>D. dendriticum</i> infected	<i>D. dendriticum</i> infected (%)	
< 1	38	5	13.15	8	21.05	
> 1	102	7	6.86	20	19.60	
Total	140	12	8.57	28	20	

Nadim (1) reported that among 120 sheep livers, 1.62% were infected with *F. hepatica* and 21.6% with *D. dendriticum* at a Tabriz slaughterhouse in 1995. Saffarbani (4) reported that among 150 sheep livers, 20% were infected with *F. hepatica* and 18.6% with *D. dendriticum* in an Ardabil slaughterhouse in 1999.

Gargılı et al. (10) studied the prevalence of liver fluke infection in slaughtered animals in Trakya, Turkey, and reported that 3.99% of 476 sheep livers were infected with *F. hepatica* and 23.52% with *D. dendriticum*.

In the present study conducted in Tabriz, *F. hepatica* was found in 12% of 140 sheep versus *D. dendriticum* in

20%. For *D. dendriticum*, this prevalence rate was higher than previously reported in the northwest of Iran, but the prevalence rate of *F. hepatica* was higher than reported in other regions of Iran. In addition, these parasites contribute to liver condemnation. We conclude that fluke infection in slaughtered sheep in the northwest region of Iran is occurring at a significant level.

Acknowledgment

The authors thank Islamic Azad University, Shabestar Branch, for partially funding this study.

References

- Nadim, A.: Prevalence of infection with liver Trematodes in Tabriz slaughterhouse. DVM Dissertation, Islamic Azad University, Tabriz Branch, Iran, 1995.
- Soulsby, E.J.L.: Helminthes, Arthropods and Protozoa of Domesticated Animals. Bailliere-Tindall, London, U.K., 1982; 210-233.
- Boray, J.C.: Studies on experimental infections with *Fasciola hepatica* with particular reference to acute fascioliasis in sheep. Ann. Trop. Med. Parasitol., 1967; 61: 439-450.
- Saffarbani, H.: Prevalence of infection with liver Trematodes in Ardabil slaughterhouse. DVM Dissertation, Islamic Azad University, Tabriz Branch, Iran, 1999.

5. Ogambo-Ongoma, A.H.: Fascioliasis survey in Uganda. Bull. Epizoot. Dis. Afr., 1972; 20: 35-41.
6. Reinecke, R.K.: Veterinary Helminthology. Butterworths Prof. Pub. Ltd. RSA, 1983; 201-244.
7. Behm, C.A., Sangster, N.C.: Pathology, pathophysiology and clinical aspects. In: Dalton, J.P. Ed., Fasciolosis. CAB International, Wallingford, Oxon, 1999; 185-224.
8. Ganti, A.: Veterinary Pathology. CBS Publ. Ltd., 2002; 715-718.
9. Vegad, J.L., Katiyar, A.K.: A Textbook of Veterinary Special Pathology. International Book Distributing Co., 2001; 532-534.
10. Gargılı, A., Tüzer, E., Gülanber, A., Toparлак, M., Efil, İ., Keleş, V., Ulutaş, M.: Prevalence of liver fluke infections in slaughtered animals in Trakya (Thrace), Turkey. Turk. J. Vet. Anim. Sci., 1999; 23: 115-116.