

1-1-2008

## Ultrasonographic Examination of the Goat Liver

SARANG SOROORI

AFSHIN RAOOFI

ALI REZA VAJHI

SARA GHORBANI NEZAMI

Follow this and additional works at: <https://journals.tubitak.gov.tr/veterinary>



Part of the [Animal Sciences Commons](#), and the [Veterinary Medicine Commons](#)

---

### Recommended Citation

SOROORI, SARANG; RAOOFI, AFSHIN; VAJHI, ALI REZA; and NEZAMI, SARA GHORBANI (2008)  
"Ultrasonographic Examination of the Goat Liver," *Turkish Journal of Veterinary & Animal Sciences*: Vol. 32: No. 5, Article 9. Available at: <https://journals.tubitak.gov.tr/veterinary/vol32/iss5/9>

This Article is brought to you for free and open access by TÜBİTAK Academic Journals. It has been accepted for inclusion in Turkish Journal of Veterinary & Animal Sciences by an authorized editor of TÜBİTAK Academic Journals. For more information, please contact [academic.publications@tubitak.gov.tr](mailto:academic.publications@tubitak.gov.tr).

## Ultrasonographic Examination of the Goat Liver

Sarang SOROORI<sup>1,\*</sup>, Afshin RAOOFI<sup>1</sup>, Ali Reza VAJHI<sup>1</sup>, Sara GHORBANI NEZAMI<sup>2</sup>

<sup>1</sup>Department of Clinical Sciences, Faculty of Veterinary Medicine, University of Tehran, P.O. Box 14155-6453, Tehran - IRAN

<sup>2</sup>General Practitioner, P.O. Box 14155-6453, Tehran - IRAN

Received: 23.05.2007

**Abstract:** The purpose of this study was to obtain detailed information about the normal size and texture of the goat liver by means of ultrasonographic examination. The structure, location, and size of the liver, portal vein, and caudal vena cava were examined ultrasonographically in 6 goats. The angle of the liver and the thickness of the gallbladder wall were also determined. Examinations were performed on the right side of the abdomen, from the 6th through 12th intercostal space, using a 6-13 MHz linear transducer. In each intercostal space the dimensions of the liver, and if visible, the location and diameter of the portal vein and caudal vena cava were determined. Ultrasonographic measurement of liver size and location in healthy goats can be used as a reference for changes in the liver attributable to illness.

**Key Words:** Ultrasonography, liver, goat

Ultrasonography has been routinely used as a diagnostic procedure in dogs and horses with liver disease. Since existing diagnostic methods for detecting hepatic disease, such as hepatospecific enzyme tests, are insufficient, there are many indications for ultrasonographically examining the liver in ruminants. Metabolic disorders, as in hepatic lipidosis associated with pregnancy toxemia, lead to diffuse changes in liver structure and size, whereas abscesses, cysts, and tumors usually cause focal lesions. Detailed descriptions of ultrasonographic examinations of the liver are available in cattle (1) and sheep (2), but to the best of our knowledge not in goats. Iran is at the heart of the Mesopotamian area where the first domestication of goats might have occurred. Indeed, goats are traditionally important in Iran and their population is very large (13.6 million) (3). As there are many diagnostic limitations in evaluating abdominal organs in small ruminants, ultrasonography can be used as an accurate and non-invasive method for detecting liver disease. A complete assessment of the liver should provide detailed information about the size, position, and parenchymal pattern of the liver, and identify the location of the major vessels. The purpose of the present study was to obtain detailed information about the ultrasonographic features of the goat liver,

portal vein, and caudal vena cava in each intercostal space (ICS).

This study was carried out with 6 clinically healthy 1-year-old male goats (mean weight:  $17.25 \pm 1.83$  kg) at the University of Tehran, Faculty of Veterinary Medicine, Large Animal Hospital. Ultrasonographic examinations were performed with a real-time scanner (Sonosite Micromax) using a 6-13 MHz linear transducer.

Hair on the right side of the abdomen was shaved, from the sixth to the last rib. After restraining the animal in the standing position, transmission gel was applied to the shaved area and each goat was ultrasonographically examined from caudal to cranial, beginning caudal to the last rib and ending at the sixth ICS. The transducer was first placed caudal to the last rib and parallel to it so that the dorsal surface appeared on the left side of the ultrasonogram. Then, each ICS (beginning from ICS 12 and ending at ICS 6) was examined from dorsal to ventral with the transducer held parallel to the ribs. In order to evaluate the possibility of left abdominal side scanning of the liver, the transducer was placed on the left side while examining 1 goat. The examination procedures were digitally recorded with a DVD recorder, using Power DVD v.5.0 software. Suitable images were captured from the

\* E-mail: Soroori@ut.ac.ir

recorded DVD and measurements were then made with Scion Image beta v.4.0.3 software. The texture of the liver, diameter and depth of the caudal vena cava and portal vein, diameter of the aorta, thickness of the liver, and thickness of the gallbladder wall were determined. Echogenicity of the liver was compared with that of the renal cortex and the visceral angle of the liver was determined. In order to enhance the accuracy of the examinations and to evaluate the reproducibility of the data obtained, ultrasonographic examination of each goat was repeated 4 times. On the whole, the measurements were made on 324 suitable captured images. Mean and standard deviation of each datum was calculated using Microsoft Excel 2003 software. In the end, the goats were euthanized and post-mortem examinations of the livers were performed in order to confirm that the livers were macroscopically normal.

The parenchymal pattern of the normal liver consisted of numerous weak echoes, which were homogeneously distributed over the entire liver. The portal vein and caudal vena cava could be seen within the normal texture. The lumens of these vessels were anechoic and, thus, appeared black. The caudal vena cava usually had an oval or triangular shape in cross section, but the portal vein always had a circular diameter. The visceral surface was sometimes difficult to assess when adjacent to the intestine. The gallbladder appeared as a fluid-filled vesicle and the bile ducts were not visible in the normal liver structure.

The best location for comparing the echogenicity of the liver and renal cortex was caudal to the 13th rib. In the present study the liver appeared more echogenic than the renal cortex in 2 of the goats, whereas these 2 structures were isoechoic in the remainder of the goats (Figure 1). The liver was well-visualized in the dorsal part of the 12th ICS; the pulsatile cross section of the aorta was also seen in this area. In the 10th and 11th ICSs, the caudal vena cava was visualized in the dorsal part, and the portal vein and its adjacent lymph nodes could be scanned in the ventral part (Figure 2).

The caudal vena cava was always positioned dorsal to the portal vein and portal vein depth was always less than that of the caudal vena cava. In the 9th ICS the caudal vena cava and portal vein could be seen simultaneously in 1 frame. The hepatic vein could be seen in the 8th ICS in a ventral position to the caudal vena cava (Figure 3). The diameter of the vessels decreased cranially and, in general, there was little possibility of visualizing the portal vein and caudal vena cava in the 6th and 7th ICS due to the super-imposition of the lungs. The gallbladder was visualized in the hypochondrium with an oval or sometimes pear-like shape.

None of the liver structures could be visualized from the left side of the abdomen, and only the spleen and some parts of the fore-stomach, which are anatomically situated in the left side, could be seen. The livers of all the goats were normal in post-mortem examination. The aorta could only be visualized in the 11th and 12th ICS,

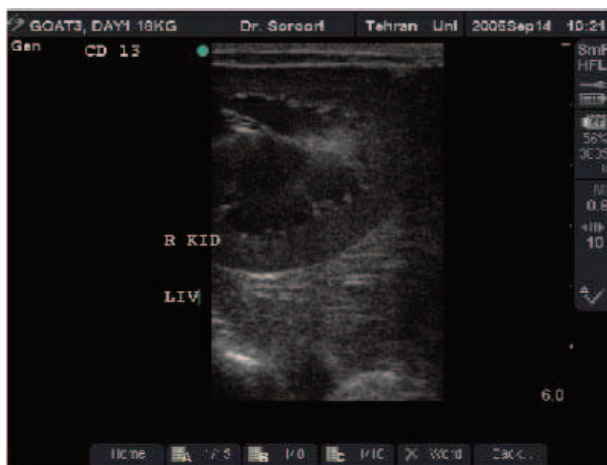


Figure 1. Ultrasonogram of the right kidney and liver. Transducer was placed caudal to the 13th rib. Liver texture seems slightly more echogenic than the renal cortex. LIV: Liver; R KID: right kidney.

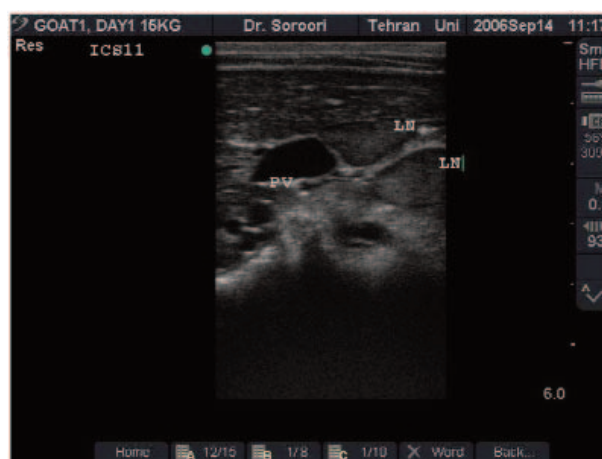

Figure 2. Ultrasonogram of the normal liver, portal vein, and adjacent lymph nodes. Transducer was placed in the 11th ICS. PV: Portal vein; LN: lymph node.

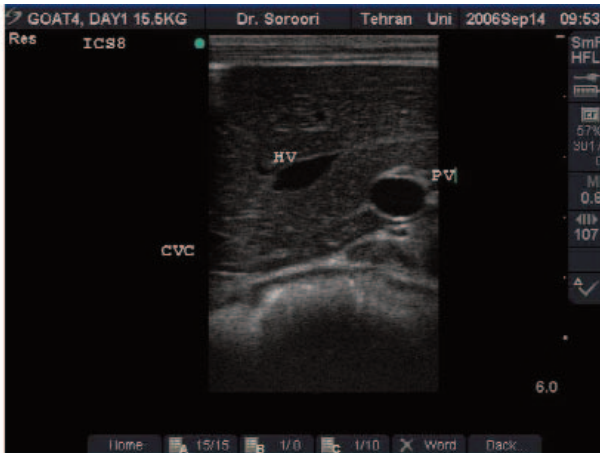


Figure 3. Ultrasonogram of the liver, portal vein, hepatic vein, and caudal vena cava. Transducer was placed in the 8th ICS. Hepatic vein is positioned dorsal to portal vein and ventral to caudal vena cava. PV: Portal vein; HV: hepatic vein; CVC: caudal vena cava.

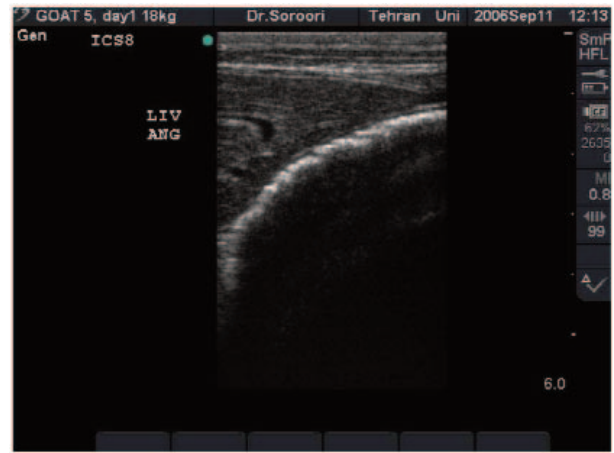


Figure 4. Ultrasonogram of the visceral angle of the liver. Transducer was placed in the 8th ICS. LIV ANG: Liver angle.

and mean aorta diameter was  $8.75 \pm 1.21$  mm and  $9.33 \pm 1.38$  mm, respectively. Mean portal vein diameter was greatest in the 11th ICS ( $8.13 \pm 1.31$  mm) and smallest in the 7th ICS ( $4.16 \pm 1.07$  mm). The depth of the portal vein ranged between  $2.12 \pm 0.29$  and  $2.81 \pm 0.19$  cm. As the caudal vena cava usually had a triangular or oval shape, both small and large diameters were measured. The greatest mean caudal vena cava large diameter was measured in the 12th ICS ( $11.13 \pm 1.63$  mm), ( $11.13 \pm 1.63$  mm for large diameter and  $5.05 \pm 0.9$  mm for small diameter) and the smallest mean diameter was measured in the 9th ICS ( $3.47 \pm 0.32$  mm), ( $7.76 \pm 0.88$  mm for large diameter and  $3.47 \pm 0.32$  mm for small diameter). Mean depth of the caudal vena cava was greatest in the 8th ICS ( $3.9 \pm 0.11$  cm) and smallest in the 12th ICS ( $2.97 \pm 0.7$  cm). The liver was largest in the 10th ICS ( $4.34 \pm 0.43$  cm) and mean thickness of the gallbladder wall was  $1.4 \pm 0.1$  mm. The angle of the liver was visible and ranged between  $19.04^\circ$  and  $30.39^\circ$  in the 10th through the 6th ICS (Figure 4).

In ruminants there are many indications for ultrasound examination of the liver because other diagnostic imaging techniques for detecting liver disease are not adequate. Radiology is not applicable in the field and can not be used in ruminants because of the large soft tissue silhouette of the rumen. Computed tomography and magnetic resonance imaging are not appropriate for ruminants, and scintigraphy is expensive. Ultrasonography is a useful complementary diagnostic

tool for ruminants, not only for the liver, but also for abdominal organs. Ultrasonography often yields more diagnostic information with less effort on the part of the clinician, less stress to the patient, and less expense to the client.

To the best of our knowledge there are no other comprehensive studies on the natural measurements of the goat liver. Maxson et al. (4) evaluated the use of ultrasound to study the prevalence of hydatid cysts in the right lung and liver of sheep and goats. They reported that the positive predictive value of ultrasound for the diagnosis of hydatidosis in sheep and goats was 82.1%. Sage et al. (5) used diagnostic ultrasound as a mass screening technique for the detection of hydatid cysts in the liver and lungs of sheep and goats, and reported that the sensitivity and specificity of ultrasonography for detecting hydatid cysts in sheep and goats was 54.36% and 97.64%, respectively. Braun and Hausammann (2) ultrasonographically examined the livers of 100 female white alpine sheep and quantitatively determined the normal anatomic characteristics of the liver. ICSs 11 through 9 were reported to be the best for such examination, as all the structures could be well-visualized in those areas.

It was reported that an increase in liver size may be suspected when the liver extends  $> 25$  cm into the first ICS or is  $> 8.5$  cm thick. When the diameter of the caudal vena cava in the 10th ICS is  $> 2.7$  cm and the diameter of the portal vein is  $> 2.0$  cm, dilatation from congestion

may be suspected (2). The parenchymal pattern of the liver, and the cross sectional view of the portal vein and caudal vena cava of the goat resemble that of sheep.

Several common goat diseases principally involve the liver and may cause considerable economic loss. The most important hepatic diseases are fluke infestation and pregnancy toxemia. Numerous drugs, chemicals, plants, and fungal mycotoxins have been reported to cause toxic hepatitis, particularly in goats. Copper toxicity produces hemolytic anemia and toxic hepatitis (6). Ultrasonography can be helpful in identifying uncommon mass lesions in the liver, such as abscesses, hydatid cysts, and, rarely, neoplasms.

When available, ultrasonography can be particularly useful in performing accurate liver biopsies. Ultrasonography can also be used to provide better characterization of abdominal distention, internal and external abdominal masses, and gross lesions of the liver. Ascites may be differentiated from fluid in the intestinal

tract, and gas distention of the intestines can be differentiated from fluid distention (7). Diffuse hepatic disease might cause a change in the echogenicity of the hepatic parenchyma. The goat liver is isoechoic or slightly hyperechoic compared to the renal cortex.

Ultrasonography can be used for the diagnosis of hepatomegaly, biliary dilatation, cholelithiasis, and focal lesions. Diffuse diseases are more difficult to detect than focal processes because the former cause less distortion of normal hepatic landmarks. Ultrasonographic diagnosis of diffuse liver disease should be substantiated by biopsy and histopathology. Ultrasonography is an accurate, non-invasive means of monitoring the progression of disease. It can also be used to perform centesis and aspiration of abscesses, as well as cholecystocentesis and aspiration of bile samples (8). The results of the present study can be used as a reference for ultrasonographic evaluation of the goat liver.

## References

1. Braun, U.: Ultrasonographic examination of the liver in cows. *Am. J. Vet. Res.*, 1990; 51: 1522-1526.
2. Braun, U., Hausammann, K.: Ultrasonographic examination of the liver in sheep. *Am. J. Vet. Res.*, 1992; 53: 198-202.
3. Porter, V.: *Goats of the World*. Farming Press, Miller Freeman Professional Ltd., Ipswich. 1996; 87-88.
4. Maxson, A.D., Wachira, T.M., Zeyhle, E.E., Fine, A., Mwangi, T.W., Smith, G.: The use of ultrasound to study the prevalence of hydatid cysts in the right lung and liver of sheep and goats in Turkana, Kenya. *Int. J. Parasitol.*, 1996; 26: 1335-1338.
5. Sage, A.M., Wachira, T.M., Zeyhle, E.E., Weber, E.P., Njoroge, E., Smith, G.: Evaluation of diagnostic ultrasound as a mass screening technique for the detection of hydatid cysts in the liver and lung of sheep and goats. *Int. J. Parasitol.*, 1998; 28: 349-353.
6. Smith, M.C., Sherman, D.M.: *Goat Medicine*. Lea & Febiger, Philadelphia. 1994; 359-380.
7. Pugh, D.G.: *Sheep and Goat Medicine*, 1st edn., W.B. Saunders Company. Philadelphia. 2002; 72-73, 97-103.
8. Aiello, S.E.: *The Merck Veterinary Manual*, 8th edn., Merck & Co., INC. Philadelphia. 1998; 225, 232-233.