

1-1-2009

Esophageal Diverticulum in a Cat

MEHMET KAZIM BÖRKÜ

KEREM URAL

MURAT KİBAR

YUNUSEMRE ÖZKANLAR

MURAT GÜZEL

See next page for additional authors

Follow this and additional works at: <https://journals.tubitak.gov.tr/veterinary>



Part of the [Animal Sciences Commons](#), and the [Veterinary Medicine Commons](#)

Recommended Citation

BÖRKÜ, MEHMET KAZIM; URAL, KEREM; KİBAR, MURAT; ÖZKANLAR, YUNUSEMRE; GÜZEL, MURAT; and CINGI, CENKER ÇAĞRI (2009) "Esophageal Diverticulum in a Cat," *Turkish Journal of Veterinary & Animal Sciences*: Vol. 33: No. 2, Article 14. <https://doi.org/10.3906/vet-0712-3>

Available at: <https://journals.tubitak.gov.tr/veterinary/vol33/iss2/14>

This Article is brought to you for free and open access by TÜBİTAK Academic Journals. It has been accepted for inclusion in Turkish Journal of Veterinary & Animal Sciences by an authorized editor of TÜBİTAK Academic Journals. For more information, please contact academic.publications@tubitak.gov.tr.

Esophageal Diverticulum in a Cat

Authors

MEHMET KAZIM BÖRKÜ, KEREM URAL, MURAT KİBAR, YUNUSEMRE ÖZKANLAR, MURAT GÜZEL, and
CENKER ÇAĞRI CINGI

Esophageal Diverticulum in a Cat

M. Kazım BÖRKÜ¹, Kerem URAL^{2,*}, Murat KİBAR³, Yunusemre ÖZKANLAR⁴, Murat GÜZEL⁵, C. Çağrı CINGİ⁶

¹Department of Internal Medicine, Faculty of Veterinary Medicine, Ankara University, Ankara - TURKEY

²Department of Internal Medicine, Faculty of Veterinary Medicine, Adnan Menderes University, Aydın - TURKEY

³Department of Surgery, Faculty of Veterinary Medicine, Erciyes University, Kayseri - TURKEY

⁴Department of Internal Medicine, Faculty of Veterinary Medicine, Atatürk University, Erzurum - TURKEY

⁵Department of Internal Medicine, Faculty of Veterinary Medicine, Mustafa Kemal University, Hatay - TURKEY

⁶Department of Internal Medicine, Faculty of Veterinary Medicine, Afyon Kocatepe University, Afyon – TURKEY

Received: 03.12.2007

Abstract: A 7-year-old spayed female domestic shorthair cat was presented because of post-prandial regurgitation, gasping shortly after eating, weight loss, dyspnea, and tachypnea. Six months prior to the onset of these signs the cat had received nutritional support via gastrostomy and then nasogastric tubes. A diagnosis of esophageal diverticulum was made on the basis of clinical features, contrast esophagram, and endoscopy, and was considered a complication of tube feeding. Medical therapy, including parenteral fluids, ranitidine, metoclopramide, and cisapride, and a soft, bland low-fat diet resulted in improvement in the clinical signs within 1 week. The cat was discharged and recovery was confirmed by phone call follow-up with the owner.

Key Words: Esophageal diverticula, regurgitation, cat, tube feeding

Bir Kedide Özefagal Divertikül

Özet: Yedi yaşlı kısırlaştırılmış evcil kısa tüylü kedi yemek sonrası şekillenen regürjitasyon, ağzı açık solunum, kilo kaybı, dispne ve taşipne nedeniyle incelendi. Klinik şikayetler başlamadan 6 ay önce kedide gastrostomi ve sonradan nazogastrik tüple beslenme sağlandığı öğrenildi. Klinik bulgular, kontrast radyografi ve endoskopi temel alınarak özefagal divertikül tanısı konuldu. Bu olguda özefagal divertikül'ün tüple beslenmenin bir komplikasyonu olduğu düşünüldü. Parenteral sıvı, ranitidin, metoklopramid ve sisaprid ile yumuşak, düşük yağlı diyet uygulamaları ile yapılan medikal sağıltım klinik bulgularda 1 haftada düzelme sağladı. Kedi taburcu edildikten sonra hasta sahibi ile yapılan telefon görüşmesiyle takipte iyileşme doğrulandı.

Anahtar Sözcükler: Özefagal divertikül, regürjitasyon, kedi, tüple beslenme

Introduction

One of the most common complaints of owners of pets with esophageal disease is regurgitation of food immediately after eating or shortly thereafter. Post-prandial regurgitation is common in patients with esophageal diverticula (1). Esophageal diverticula are

congenital or acquired sac-like outpouchings in the esophageal wall (1), and are rarely seen in dogs (2-4) and cats (5,6). Acquired esophageal diverticula are subclassified into pulsion and traction diverticula (1). Pulsion diverticula have primarily been reported in the epiphrenic region (3,7). The present report describes a cat with an esophageal diverticulum attributed to

* E-mail: uralkerem@gmail.com

nasogastric tube feeding. The clinical signs, diagnosis based on a contrast esophagram and endoscopy, and underlying causes are discussed. This report highlights the importance of including esophageal diverticula in the differential diagnosis of swallowing disorders.

Case History

A 7-year-old spayed female domestic shorthair cat weighing 3 kg was presented to a referring veterinary surgeon with a 1-month history of dysphagia due to dental calculus. The surgeon initially treated the cat with a gastrostomy tube for 10 days, along with amoxicillin-clavulanate (25 mg/kg IM q 12 h). After 10 days the patient began to eat and the gastrostomy tube was removed. Subsequently, due to a decrease in the cat's appetite 1 month after the initial therapy the cat received 12 days of enteral feeding via a nasogastric tube. General anesthesia was not used during placement of the nasogastric tube, and tube placement into the stomach was confirmed radiographically. Post-prandial regurgitation was first observed 10 days following placement of the nasogastric tube. The cat was referred to the present authors' clinic 6 months later because of post-prandial regurgitation, post-prandial gasping, weight loss, and dyspnea/tachypnea.

Results and Discussion

On physical examination the cat was underweight, lethargic, and dyspneic. Rectal temperature was 38.7 °C. The cat's respiratory rate was 50 breaths per minute, with open-mouth breathing and marked abdominal effort, and the heart rate was 120 beats per minute. Auscultation of the right and left lung fields was normal. The cat had been frequently vaccinated against upper respiratory tract viruses and FeLV. In order to achieve an accurate differential diagnosis for the dyspnea, chest radiographs were obtained; however, there was no evidence of disease. Initial diagnostic tests included complete blood cell count (CBC), serum biochemical analysis, and urinalysis. All results were within reference ranges, except for normocytic-normochromic anemia (PCV 20% [reference range: 24%-45%]; RBC count $4.16 \times 10^6/\mu\text{l}$ [reference range: 5-10 $10^6/\mu\text{l}$]; MCV: 44 fl [reference range: 39-55 fl]; MCHC: 32 g/dl [reference range: 30-36 g/dl]). Examination of the oral cavity revealed no abnormalities.

Clinical signs associated with esophageal diverticula may include distress, gasping shortly after eating, post-prandial regurgitation, intermittent anorexia, weight loss, fever, and/or thoracic or abdominal pain. Affected cats develop respiratory signs (1), probably due to secondary aspiration pneumonia (6). Because aspiration pneumonia was ruled out in the present case based on thoracic radiographic controls and examination of the respiratory system was unremarkable, the secondary respiratory signs were attributed to pressure exerted on the trachea by the esophageal diverticulum. Apart from fever, all of the clinical signs of diverticula cases described by Strombeck and Guilford (1) were observed in the present case.

Many possible causes of diverticula have been described, including esophagitis, esophageal strictures, foreign bodies, megaesophagus, hiatal hernias, and vascular ring anomalies (1). Esophageal diverticula may be acquired or congenital (3), and are rarely observed in dogs and cats. Congenital diverticula can develop due to weakness of the esophageal wall, abnormal separation of tracheal and esophageal embryonic buds, or eccentric vacuole formation in the esophagus (1). According to etiopathogenesis, acquired forms can be classified as pulsion or traction diverticula (1). Pulsion diverticula typically appear in the epiphrenic region and have been observed cranial to stenosed esophagi (3,7). Traction diverticula caused by tracheal, bronchial, and hilar lymph nodular inflammatory disorders are generally located cranial to the esophagus and in the mid-thoracic esophagus. Histologically, pulsion diverticula consist of esophageal epithelium and connective tissue, whereas traction diverticula are composed of all the esophageal layers (1). In the present case the diverticulum was not classified, as the owner declined histopathological examination.

The differential diagnosis of regurgitation, gasping immediately after eating, and weight loss include pharyngeal obstructive and neuromuscular disorders, palate abnormalities, esophagitis, esophageal foreign bodies, neoplasia, peri-esophageal masses, granuloma, megaesophagus, esophageal diverticula, hiatal disorders, and vascular ring anomalies. Thoracic radiographs obtained with the presented cat in right lateral recumbency revealed an air-filled cervical esophagus dorsal to the trachea. Radiographs of the remainder of the esophagus were unremarkable.

In patients that are regurgitating, the esophagus must be evaluated using contrast radiographs. Abnormalities that can be detected with esophagrams include dilation, foreign bodies, diverticula, strictures, *Spirocerca lupi* infestation, gastroesophageal intussusception, neoplasia, esophagitis, cricopharyngeal achalasia, esophageal and esophagobronchial fistula, and vascular ring anomalies. Patients with esophageal diverticula often have bilateral symmetric outpouching of the esophagus, cranial to the diaphragm (1,8,9). It is noteworthy that both barium contrast medium and endoscopy revealed the diverticulum in the presented case. A contrast esophagram using barium mixed with canned food revealed a food-filled mass located cranial to the esophagus (Figure a and b). Esophageal diverticulum appeared to be the most likely diagnosis. Esophagoscopy confirmed the diagnosis. Endoscopy excluded masses and neoplasias. Additionally, there was no evidence of an esophageal stricture, mass, or foreign body.

Placement of a gastrostomy tube may cause gastroesophageal reflux (10,11). Gastroesophageal reflux may be associated with upper gastrointestinal motor function abnormalities (12). Reflux is more likely when there is gastric retention and gastric outflow obstruction. Gastric fluid refluxed into the esophagus can damage the

mucosa, due to its acidity (1), and may result in esophagitis (6). Feline esophagitis secondary to gastroesophageal reflux was previously reported in 3 young, male purebred cats (13). Esophagitis has also been observed as a complication associated with nasogastric tube feeding-induced gastric reflux (14,15). In the present case there was no history of gastroesophageal reflux prior to nasogastric tube placement; the clinical signs developed afterwards. Based on the history given by the owner, we could not be certain that nasogastric tube feeding was the cause of the diverticulum. Nevertheless, there was no history of the administration of general anesthesia, and it is possible that the esophageal diverticulum in this case was caused by esophagitis due to continuous gastroesophageal reflux, or by esophageal injury following nasogastric tube feeding (via continued contact between the tube and the esophageal mucosa), as described previously (14-16).

The owner declined surgical treatment. Medical therapy included parenteral fluids (lactated Ringer's solution), ranitidine (2 mg/kg IM, q 6 h for 10 days), metoclopramide (0.2 mg/kg IV q 8 h for 15 days), and cisapride (PO 2.5 mg q 8 h for 15 days). A soft, bland low-fat diet consisting of turkey with some baby rice cereal given 3-4 times a day was recommended, and the

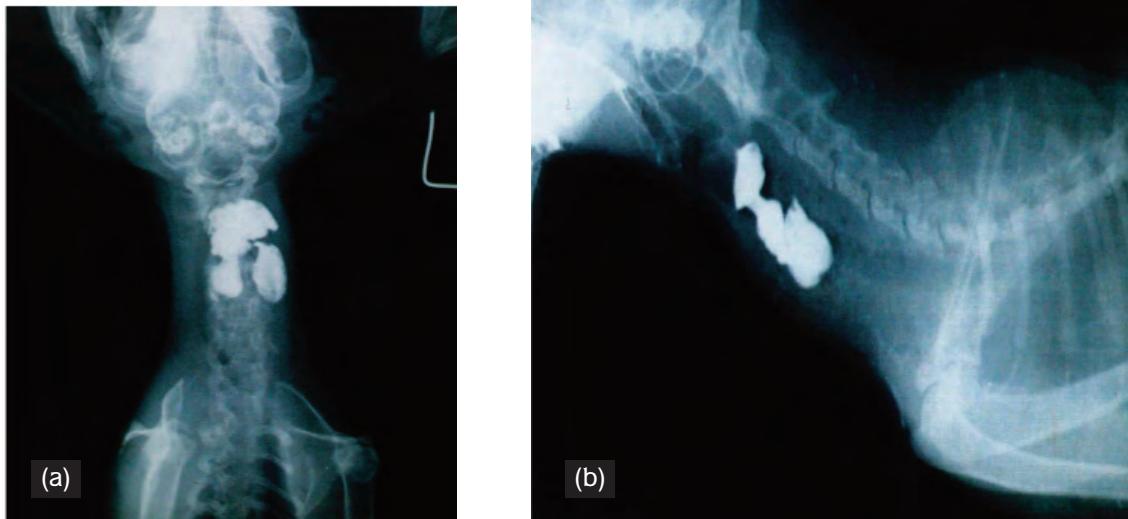


Figure. An esophageal diverticulum filled with barium contrast mixed with canned food in a 7-year-old cat. Note the food-filled mass located cranial to the esophagus in the lateral (a) and dorsoventral (b) view. Films were taken at time 0.

patient was fed while helped to stand upright on its hind legs, with ample liquid. The clinical signs resolved within the first week of initiating the recommended therapy. The owner was advised to change the diet gradually to the Hill's a/d diet over the course of the next 2 months, and no recurrence was observed during the following 3-month observation period. A barium contrast esophagram was repeated and the diverticulum was reduced in size. The cat was discharged and the owner was advised to bring the cat for follow-up. The cat was not followed-up at the clinic, but recovery was confirmed by a phone call follow-up with the owner.

Large diverticula often require surgical excision; however, medical management may be sufficient in cases

of small diverticula (6). Clinical improvement in the present case was obtained with medical management of esophagitis and gastroesophageal reflux, as the owner declined surgical manipulation.

In summary, esophageal diverticula may be associated with prolonged nasogastric tube feeding. Veterinary clinicians should bear in mind that esophageal diverticula may be a cause of post-prandial regurgitation. Contrast esophagrams can be diagnostic and endoscopic examination can be useful in establishing the diagnosis. Medical therapy should be an alternative in cases in which surgical excision cannot be performed. In the presented case medical therapy resulted in recovery; however, large diverticula may require surgical treatment.

References

1. Strombeck, D.R., Guilford, W.G.: Esophageal Diverticula: Diseases of Swallowing. Esophageal motility disorders. *Small Animal Gastroenterology*. Stonegate Publishing, California, 1990; 157.
2. Iwasaki, M., de Alvarenga, J., de Martin, B.W.: Esophageal diverticula in a dog. *Mod. Vet. Pract.*, 1977; 58: 606-613.
3. Pearson, H., Gibbs, C., Kelly, D.F.: Oesophageal diverticulum formation in the dog. *J. Small Anim. Pract.*, 1978; 19: 341-355.
4. Hill, F.W., Christie, B.A., Reynolds, W.T., Lavelle, R.B.: An oesophageal diverticulum in a dog. *Aust. Vet. J.*, 1979; 55: 184-187.
5. Pearson, H., Darke, P.G., Gibbs, C., Kelly, D.F., Orr, C.M.: Reflux oesophagitis and stricture formation after anaesthesia: a review of seven cases in dogs and cats. *J. Small Anim. Pract.* 1978; 19: 507-519.
6. Shaw, D.H., Ihle, S.L.: Gastrointestinal disease II. Esophageal disorders. In: Wolters, K. Ed., *Small Animal Internal Medicine*. WB Saunders Co., Philadelphia. 1997; 257-258.
7. Lantz, G.C., Bojrab, M.J., Jones, B.D.: Epiphrenic esophageal diverticulectomy. *J. Am. Anim. Hosp. Assoc.*, 1976; 12: 629-635.
8. Kealy, J.K.: *Diagnostic Radiology of the Dog and Cat*. WB Saunders Co., Philadelphia. 1979; 45-60.
9. Seekri, I.K., Rescorla, F.J., Canal, D.F., Zollinger, T.W., Saywel, R. Jr., Grosfeld, J.L.: Lesser curvature gastrotomy reduces the incidence of postoperative gastroesophageal reflux. *J. Pediatr. Surg.*, 1991; 26: 982-985.
10. Canal, D.F., Vane, D.W., Goto, S., Gardner, G.P., Grosfeld, J.L.: Changes in lower esophageal sphincter pressure (LES) after Stamm gastrotomy. *J. Surg. Res.*, 1987; 42: 570-574.
11. Hillemeier, C., Gryboski, J., McCallum, R., Biancani, P.: Developmental characteristics of the lower esophageal sphincter in the kitten. *Gastroenterology*, 1985; 89: 760-766.
12. Hillemeier, C., McCallum, R., Oertel, R., Gryboski, J.: Effect of bethanechol and metoclopramide on upper gastrointestinal motility in the kitten. *J. Pediatr. Gastroenterol. Nutr.*, 1986; 5: 134-137.
13. Han, E., Broussard, J., Baer, K.E.: Feline esophagitis secondary to gastroesophageal reflux disease: clinical signs and radiographic, endoscopic, and histopathological findings. *J. Am. Anim. Hosp. Assoc.*, 2003; 39: 161-167.
14. Newton, M., Burnham, W.R., Kamm, M.A.: Morbidity, mortality, and risk factors for esophagitis in hospital inpatients. *J. Clin. Gastroenterol.*, 2000; 30: 264-269.
15. Sanders, S., Bartges, J.W.: Management of anorexia. In: *Kirk's Current Veterinary Therapy XIII. Small Animal Practice*. WB Saunders Co., Philadelphia. 1999; 69-74.
16. Willard M.D., Weyrauch E.A.: Esophagitis. In: *Kirk's Current Veterinary Therapy XIII. Small Animal Practice*. WB Saunders Co., Philadelphia. 1999; 607-610.