

1-1-2009

## Identification of different protozoa species from a common buzzard (*Buteo buteo*)

ÖZLEM ÖZMEN

MEHMET HALIGÜR

RAMAZAN ADANIR

Follow this and additional works at: <https://journals.tubitak.gov.tr/veterinary>



Part of the [Animal Sciences Commons](#), and the [Veterinary Medicine Commons](#)

---

### Recommended Citation

ÖZMEN, ÖZLEM; HALIGÜR, MEHMET; and ADANIR, RAMAZAN (2009) "Identification of different protozoa species from a common buzzard (*Buteo buteo*)," *Turkish Journal of Veterinary & Animal Sciences*: Vol. 33: No. 3, Article 14. <https://doi.org/10.3906/vet-0803-29>

Available at: <https://journals.tubitak.gov.tr/veterinary/vol33/iss3/14>

This Article is brought to you for free and open access by TÜBİTAK Academic Journals. It has been accepted for inclusion in Turkish Journal of Veterinary & Animal Sciences by an authorized editor of TÜBİTAK Academic Journals. For more information, please contact [academic.publications@tubitak.gov.tr](mailto:academic.publications@tubitak.gov.tr).

## Identification of different protozoa species from a common buzzard (*Buteo buteo*)

Özlem ÖZMEN<sup>1,\*</sup>, Mehmet HALIGÜR<sup>1</sup>, Ramazan ADANIR<sup>2</sup>

<sup>1</sup>Department of Pathology, Faculty of Veterinary Medicine, Mehmet Akif Ersoy University, 15100 Burdur - TURKEY

<sup>2</sup>Department of Parasitology, Faculty of Veterinary Medicine, Mehmet Akif Ersoy University, 15100 Burdur - TURKEY

Received: 25.03.2008

**Abstract:** An adult, female common buzzard (*Buteo buteo*) with paraplegia due to shooting wound on the sacral region was diagnosed with *Leucocytozoon toddi*, *Haemoproteus elani*, and *Histomonas meleagridis*. This is the first report of simultaneous naturally occurring *Leucocytozoon toddi*, *Haemoproteus elani*, and *Histomonas meleagridis* identification in a buzzard.

Key Words: Common buzzard, *Leucocytozoon toddi*, *Haemoproteus elani*, *Histomonas meleagridis*, pathology

### Bir şahinde çeşitli protozoa türlerinin identifikasyonu

**Özet:** Sakral bölgede ateşli silah yaralanması sonucu felç şekillenmiş bir şahinde (*Buteo buteo*) *Leucocytozoon toddi*, *Haemoproteus elani*, and *Histomonas meleagridis* teşhis edildi. Bu bir şahinde *Leucocytozoon toddi*, *Haemoproteus elani* ve *Histomonas meleagridis*'in beraber identifiye edildiği ilk rapordur.

Anahtar Sözcükler: Şahin, *Leucocytozoon toddi*, *Haemoproteus elani*, *Histomonas meleagridis*, patoloji

### Introduction

*Leucocytozoon* and *Haemoproteus* are the 2 subgroups of avian blood parasites (1-3). The falcon Leucocytozoonosis is caused by *Leucocytozoon toddi* (1,4). *Haemoproteus* is a commonly encountered and easily identified protozoan parasite that infects red blood cells in wild birds of many species. It is generally not associated with obvious clinical signs (2). The gametocytes of the *Haemoproteus elani* slightly enclose the nucleus with their ends and never encircle

it completely (5). While *Leucocytozoon* spp. uses Simuliidae as vector, *Haemoproteus* spp. uses Culicoides. *Histomonas meleagridis* is a pleomorphic flagellated protozoan, transmitted in the eggs of the caecal nematode, *Heterakis gallinarum* (2).

There are a very limited number of studies on blood parasites of avian species (6,7) in Turkey, and there is no report describing the presence of *Leucocytozoon toddi*, *Haemoproteus elani*, and *Histomonas meleagridis* in buzzard.

\* E-mail: ozlemozmen@mehmetakif.edu.tr

### Case history

An adult, female common buzzard (*Buteo buteo*) with paraplegia, inappetence, and dullness was the material of this study. A farmer found it accidentally and brought to our clinic. A big shooting wound due to hunting was observed on the sacral region. At the clinical examination, total paraplegia diagnosed in both legs. One drop blood sample was taken from the wing vein and blood smears prepared. The smears were fixed in methanol for 5 min and stained with Giemsa solution for 45 min and examined under the immersion objective. The prognosis was poor and the buzzard died 2 days after presentation to the faculty and necropsy was performed. Tissue samples were taken from the all visceral organs. Samples were fixed in 10% neutral-buffered formalin and routinely processed and embedded into paraffin for histopathological examination. Tissues were sectioned at 5  $\mu$  and stained with hematoxylin and eosin (HE), Zielh-Neelsen, and Periodic acid Schiff (PAS). Fecal sample was taken for parasitological examination.

### Results and Discussion

In the prepared blood smears, numerous *Leucocytozoon toddi* and *Haemoproteus elani* gametocytes were observed. The buzzard showed no clinical symptoms related to haemoparasites. During the examination of blood smears, roundish and fusiform gametocytes were observed in the red blood cells. Gametocytes in roundish shape was rarer than fusiform in host cell in the blood smear. The parasite's perimeter generally adhered to the host cell nucleus. The parasite's nucleus was elongated, with a clear nucleolus close to the nuclear membrane. According to these characteristics, and host specificity, the parasite was identified as *L. toddi* (Figure 1). *Haemoproteus elani* gametocytes were observed numerous erythrocytes. The gametocytes were partially encircling the erythrocyte nucleus and often occupied over one-half of the erythrocyte cytoplasm. The multiple, refractile, golden-brown pigment particles were observed in the gametocyte (Figure 2).

At necropsy traumatic injury and bleeding were observed on the sacral region. Numerous fractures were seen at sacral bone that attributed the cause of

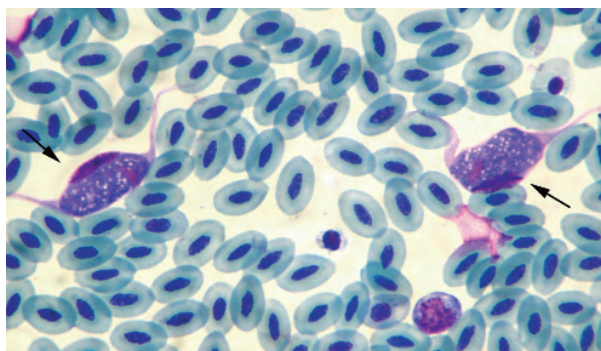


Figure 1. Two gametocytes of *Leucocytozoon toddi* (arrows) in blood smear, common buzzard, Giemsa stain, and immersion oil.

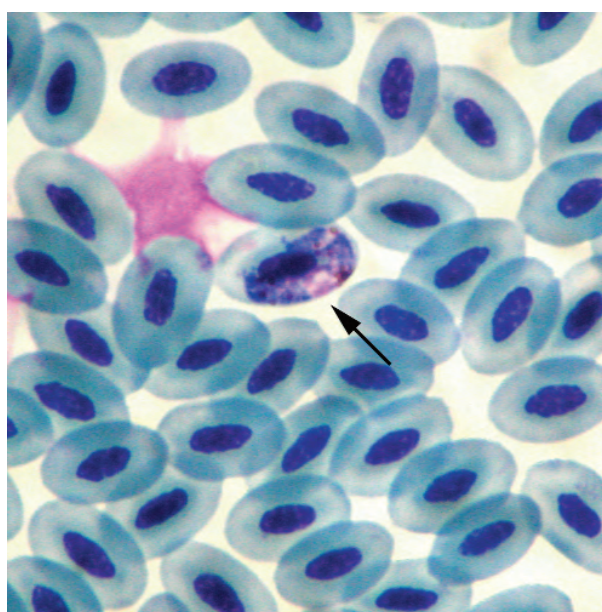


Figure 2. *Haemoproteus elani* gametocyte within an erythrocyte partially surrounds the cell's nucleus, common buzzard, Giemsa stain, and immersion oil.

paraplegia. Blood coagulum was also observed at the abdominal cavity.

At histopathological examination, no developmental stages of *L. toddi* or *H. elani* were seen in any organ. There was no inflammatory reaction around the vessels. Microscopic examination of gut revealed numerous flagellate in the cells of the guts. The flagellates were diagnosed as *Histomonas meleagridis* according to morphological characteristics of the protozoa (Figure 3). On

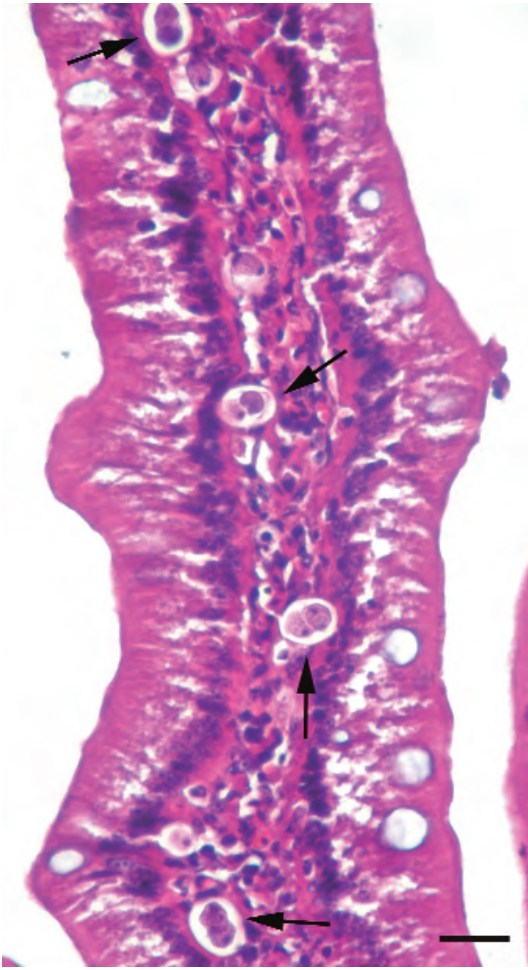


Figure 3. Numerous *Histomonas meleagridis* in the cell of the gut, common buzzard, HE, Bar = 100 µm.

histopathological examination, although numerous necrotic foci and inflammatory reaction were observed in liver, no parasites were observed. Because the Zielh-Neelsen and Periodic acid Schiff (PAS) staining were negative for acid fast bacteria and mycotic agents, liver lesions were attributed to the early *H. meleagridis* reaction.

*Leucocytozoon* and *Haemoproteus* are the most common blood parasites in wild birds. Generally, species of *Haemoproteus* are considered nonpathogenic and a few species of *Leucocytozoon* is

considered pathogenic. Only high parasitemias of apathogenic *Haemoproteus* and *Leucocytozoon* can cause clinical problems if a bird is stressed or immunosuppressed (2,8). In the present study, there were large, elongated, bluish, granular, intracytoplasmic *L. toddi* gametocytes and partially encircling the erythrocyte nucleus *H. elani* gametocytes were observed in the blood smears. Neither clinical nor pathological findings were observed in any organ of the buzzard related to haemoparasites. The number of gametocytes of *L. toddi* was higher than *H. elani* gametocytes.

Haemoprotozoa infection has been suggested to be species-specific; criteria for species designation include host range and gametocyte features, such as staining characteristics, size, nature, and extent of distortion of the host cell and altered shape, and position of the host cell nucleus (2,8,9). Gametocytes of *H. elani* were partially surrounding the nucleus of the erythrocytes. Diagnosis was made through the morphology of gametocytes and host specificity.

Histomoniasis is a flagellated protozoan parasite and common in gallinaceous birds. While in some birds this parasite is considered a major pathogen; in other birds it is considered an incidental finding. Most infections occur following the ingestion of infected embryonated eggs of the cecal worm *Heterakis gallinarum*. The histomonas are released from the larvae and invade the wall of the cecum (2,3,10). To parasitize liver, histomonas need more than 12 days (10). In this study there is no *Heterakis gallinarum* was observed at the fecal examination. *Histomonas meleagridis* only seen in the gut and the possible cause of this was attributed to the early infection.

Blood parasites are transmitted from infected to uninfected birds by a variety of biting flies. Simuliidae (vector of *Leucocytozoon* spp.) and culicoides (vector of *Haemoproteus* spp.) is common throughout Turkey. The prevalence of the blood parasites in wild birds is unknown in Turkey. As conclusion, this is the first report of the presence of *Leucocytozoon toddi*, *Haemoproteus elani*, and *Histomonas meleagridis* in the buzzard.

## References

1. Greiner, E.C., Kocan, A.A.: *Leucocytozoon* (Haemosporida: Leucocytozoidae) of the falconiformes. *Can. J. Zool.*, 1977; 55: 761-770.
2. Greiner, E.C., Ritchie, B.W.: Parasites. In: Ritchie, B.W., Harrison, G.J., Harrison, L.R. Eds., *Avian Medicine: Principles and Application*. Wingers Publishing Inc. Florida, 1994; 1007-1029.
3. Soulsby, E.J.L.: *Helminths, Arthropods and Protozoa of Domesticated Animals*. Bailliere Tindall, London. 1982; 703-705.
4. Schmidt, E.R.: Pathology of cage birds. Major diseases encountered in pet avian practice. In: Roskopf, W.J., Woerpel, R.W., Eds., *Disease of Cage and Aviary Birds*. Williams and Wilkins, Pennsylvania, 1996; 868-869.
5. Valkunas, G.: Systematic index of species. In: *Avian Malaria Parasites and Other Haemosporidia*. CRD Press, Florida, 2005; 243-869.
6. Gıcık, Y., Arslan, M.Ö.: Blood parasites of wild pigeons in Ankara district. *Turk. J. Vet. Anim. Sci.*, 2001; 25: 169-172.
7. Özmen, Ö., Haligür, M., Yukarı, B.A.: A study on the presence of Leucocytozoonosis in wild bird of Burdur district. *Turk. J. Vet. Anim. Sci.*, 2005; 29: 1273-1278.
8. Forrester, D.J., Foster, G.W., Morrison, J.L.: *Leucocytozoon toddi* and *Haemoproteus timunculi* (Protozoa: Haemosporina) in the Chimango Caracara (*Milvago chimango*) in Southern Chile. *Mem. Inst. Oswaldo Cruz.*, 2001; 96: 1023-1024.
9. Remple, J.D.: Intracellular hematozoa of raptors: a review and update. *J. Avian Med. Surg.*, 2004; 18: 75-88.
10. McDougald, L.R.: Protozoa, other protozoan diseases of the intestinal tract. In: Calnek, B.W., Barnes, H.J., Beard, C.W., McDougald, L.R., Saif, Y.M., Eds., *Diseases of Poultry*. Iowa State Press, Iowa, 1997; 890-895.