

1-1-1999

The Accumulation and Histological Effects of TheOrganometallic Fungicide Propineb on The Organsof Fetuses and Female Rats During Pregnancy

KEMAL GÜVEN

ENGİN DEVECİ

DAVİD DE POMERAI

Follow this and additional works at: <https://journals.tubitak.gov.tr/biology>



Part of the [Biology Commons](#)

Recommended Citation

GÜVEN, KEMAL; DEVECİ, ENGİN; and POMERAI, DAVID DE (1999) "The Accumulation and Histological Effects of TheOrganometallic Fungicide Propineb on The Organsof Fetuses and Female Rats During Pregnancy," *Turkish Journal of Biology*. Vol. 23: No. 4, Article 3. Available at: <https://journals.tubitak.gov.tr/biology/vol23/iss4/3>

This Article is brought to you for free and open access by TÜBİTAK Academic Journals. It has been accepted for inclusion in Turkish Journal of Biology by an authorized editor of TÜBİTAK Academic Journals. For more information, please contact academic.publications@tubitak.gov.tr.

The Accumulation and Histological Effects of The Organometallic Fungicide Propineb on The Organs of Fetuses and Female Rats During Pregnancy

Kemal GÜVEN

Dicle University, Science Faculty, Biology Department, 21280, Diyarbakır-TURKEY

Engin DEVECI

Dicle University, Medical Faculty, Histology and Embryology Dept. Diyarbakır-TURKEY

David de POMERAI

Life Science Dept. Nottingham University, Nottingham NG7 2RD, ENGLAND

Received: 16.02.1998

Abstract: Dithiocarbamate propineb is an organometal fungicide, which is widely used for the control of diseases in plants. Female Wistar rats were exposed orally to propineb concentrations of 200 and 400 ppm, from the 6th day of gestation up to birth. At 400 ppm, propineb showed a variety of macroscopic (e.g. ptosis and paralysis) and microscopic symptoms in the organs of both fetuses and female rats. We found that the body weights of both one-day old litters and their propineb-treated mothers were lower than those of the controls. Histological examination of the livers and kidneys of the fetuses and propineb-treated pregnant females showed a variety of histopathological effects. The analysis of Zn concentrations (using Inductively Coupled Plasma-Atomic Emission Spectrometry) in the liver, kidney and heart of pregnant females exposed to organometallic fungicide during pregnancy demonstrated that the metal concentrations in these organs were higher than those of the controls. However, the hepatic, renal and myocardial Zn concentrations were greatly increased in the litters subjected to the fungicide during gestation, indicating that high levels of the trace metal in the organs of fetuses may well be due to fungicide easily passing the placental barrier.

Key Words: Maternal-fetal zinc accumulation, fungicide, propineb, histopathological effects.

Fetüs ve Dişi Ratların Organlarında Organometalik Fungisit Propineb'in Hamilelik Esnasında Birikimi ve Histolojik Etkileri

Özet: Ditiyokarbamat yapısında olan propineb bitkisel hastalıkların kontrolünde yaygın bir şekilde kullanılan bir organometal fungusittir. Hamileliğin 6. gününden doğuma kadar 200 ve 400 ppm'lik propineb konsantrasyonları dişi Wistar ratlara ağız yolu ile verilmiş; 400 ppm'lik konsantrasyonda hem fetüs hem de dişi ratların organlarında bir çok makroskopik (ör. pitosis ve felç) ve mikroskopik septomlara rastlanmıştır. Yapılan çalışmada, fungusit ile muamele edilen anne ve yavrularının vücut ağırlıkları kontrolden daha düşük bulunmuştur. Fetüs ve propineb verilen annenin karaciğer ve böbreklerinde yapılan histolojik inceleme sonucunda çok sayıda histopatolojik etkiye rastlandı. Hamilelik esnasında organometal fungusit verilen hamile dişilerin karaciğer, böbrek ve kalplerindeki Zn konsantrasyon analizi (ICP-AES; Inductively Coupled Plasma-Atomic Emission Spectrometer

kullanarak) bu organlarda metal konsantrasyonlarının kontrole nazaran oldukça yüksek olduğu bulundu. Bununla beraber, hamilelik esnasında fungusite maruz kalan yavruların karaciğer, böbrek ve kalplerindeki Zn konsantrasyonları kontrole nazaran çok büyük oranlarda artmıştır; fetüsün organlarında bulunan bu yüksek metal seviyeleri fungusitin plasental engeli rahatlıkla geçebildiğinin bir göstergesi olabilir.

Anahtar Sözcükler: Maternal-fetal çinko birikimi, fungusit, propineb, histopatolojik etkiler.

Introduction

The increasing use of pesticides all over the world makes it necessary to reveal the toxic risk in populations of non-target organisms (Hassal, 1990). Among these, Maneb, Zineb, Ziram, Mancozeb and Propineb are organometallic dithiocarbamate fungicides. It has previously been reported that dithiocarbamates form metabolites called isothiocyanates which may disrupt protein synthesis and metabolism, by inactivating -SH groups in amino acids, proteins and enzymes (Ware, 1983; Lukens, 1971). Ethylenethiourea, also one of the metabolites of ethylenebisdithiocarbamate fungicides, has been reported to be carcinogenic, teratogenic and mutagenic in experimental animals (Teramoto et al., 1975; Larsson et al., 1976).

Few studies have been carried out on the toxicity of dithiocarbamates containing heavy metals. Mancozeb (Mn- and Zn-containing dithiocarbamate) and Maneb (Mn-containing dithiocarbamate), two commonly used fungicides, have been shown to induce tumors in mouse skin and rats (Subramoniam et al., 1991). Mancozeb is found to cause an increase in glutathione transferase activity in the liver of new-born, weanling and adult rats (Trivedi et al., 1993). Vachkova-Petrova et al. (1991) expose Wistar rats of both sexes subchronically to propineb (Zn dithiocarbamate), and found a high lethality with a characteristic clinical picture: interruption of weight gain, behavioral changes, leucopenia mainly involving neutrophil leukocytes, and characteristic biochemical changes in the liver, brain, myocardium etc. Hasegawa et al. (1993) showed that propineb causes cancer in the thyroid, kidney and urinary bladder of rats. Moreover, agricultural exposure to the organomanganese fungicide manebe is said to induce an extra-pyramidal syndrome resembling Parkinsonism (Meco et al., 1994). Soleo et al. (1996) suggest that ethylene-bis-dithiocarbamates rather than Mn may be primarily responsible for the cytotoxicity of organomanganese fungicides on neuronal systems.

Few studies have been carried out on the mechanisms of organometallic fungicide action or on the fate of fungicides in target organisms. However, many studies have been reported on the effects of heavy metals alone in a variety of organisms (Kendrick et al., 1992). Exposure to most metals results in metal accumulation in certain tissues and organs of the exposed organisms. It is also known that metals may cause extensive damage to the organs in which they accumulate. Zinc (Zn) concentration varies widely in different tissues, but Zn is known to accumulate in two particular organs, namely the liver and kidney, where they may cause biochemical and histopathological changes (Goyer, 1986; Wlostowski, 1992). Zn is known to be essential for prenatal growth and differentiation, and its deficiency causes fetal growth retardation (Sowa and Steibert, 1985). An investigation showed that development of the heart, kidney and liver

were all retarded in zinc-deprived mice (Bertholf, 1988). Zn also affects lipid peroxidation in biological membranes (Prasad, 1979). Zn and other metals may also affect many key biological systems such as oxidative phosphorylation, membrane permeability and protein synthesis. Increases in trace metal levels in cells may result in chelation with biological components, particularly with enzymes, again causing cellular damage (Lukens, 1971; Ware, 1983).

The aim of this study was to evaluate the histopathological effects of the organometallic fungicide propineb and to determine trace metal levels in different organs of the fetus and female rats treated with organometallic fungicide during pregnancy.

Materials and Methods

Animals and Treatment: 20 female Wistar albino rats of initial body weight of 200-215 gr. were used. Females were mated with non-exposed males; the criterion used to identify mated females was the presence of spermatozoa in the vagina (day 0 of gestation). All animals were individually housed in stainless steel cages at room temperature. The animals had free access to standard laboratory rat food pellets and tap water. The pregnant females (day 6 of gestation) received propineb (obtained from Bayer) concentrations of 200 and 400 ppm in distilled water days a week, administered orally. Acute oral LD50 for male rats has been found to be 8500 mg/kg (Worthing, 1983). The controls received only distilled water.

Sample Preparation and Assay of Metal Concentrations: Following exposure, the organ samples were taken under ether anesthesia from both litters and mothers. Standardized samples containing the following numbers of organs: one liver, four kidneys and four hearts for litters, and one liver, one kidney (right) and one heart for mothers were pooled routinely. Before weighing, all organs were rinsed with saline solution. The samples were weighed and dried at 105°C for 48 hours. Concentrated sulphuric acid and nitric acid were added to all samples and evaporated to dryness on a hot plate. The residues were dissolved and diluted to 15 ml with 1% HNO₃. The chemicals used were all of analytical grade. Deionized water was used for all preparations. The samples were analyzed for zinc using a Jobin Yvon Model 24 Inductively Coupled Plasma-Atomic Emission Spectrometer (ICP-AES, at a wavelength of 330.25 nm; this instrument gave a lower detection limit of 230 ppb for Zn). All data are presented as concentrations per unit wet weight of the samples. The significance of differences between appropriate pairs of data sets was assessed by the ANOVA test.

Histological examination: The livers and kidneys of the litters and mothers were examined for histopathological changes. The samples were placed in 10% formaldehyde and dehydrated in 70-100% ethanol series. They were then placed in paraffin baths at 58°C for paraffin inclusion. Sections of 4-6 µm were prepared from paraffin blocks using a rotary microtome. These sections were then stained with Hematoxylin-Eosin (H-E) and photographed using an Olympus BH2 photomicroscope.

	Body Weights (gr)*		
	Control	200 ppm Propineb	400 ppm Propineb
Mothers	206.25±7.50	192.75±6.60	181.25±6.50
Litters	7.27±0.328	6.44±0.355	6.44±0.128

Table 1. Body weights of both one-day-old litters and their propineb-treated mothers following two weeks of exposure during pregnancy.

*Each entry shows the mean weight of at least 5 animals.

Results and Discussion

We initially observed that fungicide treated females had a low implantation rate when they were administered with the toxicant at the first day of gestation. Therefore, the mated rats in this study were treated with the fungicide from gestation day 6 onwards. In fact, many studies have been reported regarding the effects of fungicides on pregnancy loss and birth defects (Cummings et al., 1990; Johnson et al., 1990; Noda et al., 1991; Garry et al., 1996; Tas et al., 1996; Jeffay et al., 1996). Perreault et al. (1992) used a hamster animal model to identify early pregnancy loss due to acute fungicide exposure to the female during the perifertilization interval, showing that fungicide exposure results in very early pregnancy loss. These fungicides are also found to affect reproduction in many organisms (Cummings et al., 1990; Eroschenko et al., 1995; Marchal-Segault and Lauge, 1997; Kackar et al., 1997). Some fungicides are also reported to cause teratogenesis (Beck, 1993; Price et al., 1996; Srivastava and Raizada, 1996); thus Branch et al. (1996) found alterations in axial skeleton development in pesticide-treated mouse fetuses, while Tanaka et al. (1995) described limb deformities in rat fetuses exposed to piperonyl butoxide during pregnancy.

In this study, we found that the body weights of both one-day-old litters and their propineb-treated mothers were lower than those of the controls (see Table 1). Vachkova-Petrova et al. (1991) also found that subchronic exposure to propineb results in interruption of weight gain in Wistar rats of both sexes. Propineb was found to cause diarrhoea in the pregnant female rats, which is a well-known clinical picture for acute Zn overload (Goyer, 1986), and this may well be one reason for the observed weight loss in female rats.

Although it has been reported that in 2 year feeding trials no ill effect was caused in rats receiving 50 mg/kg diet (Worthing, 1983), the pregnant rats exposed to 400 ppm propineb for about two weeks had some macroscopic and microscopic effects. Ptosis was also observed at the end of pregnancy following exposure to 400 ppm propineb. Another interesting macroscopic observation at this concentration was that the fungicide caused paralysis of the extremities of pregnant females, and they rarely got through pregnancy. However, no such effects were observed with their born litters. Acute exposure to the organophosphate pesticide chlorpyrifos on gestation day 12 was found to cause changes in the maternal brain but lesser changes in the fetal brain (Chanda and Pope, 1996).

Histological examination of the liver of pregnant females exposed to 400 ppm propineb showed a dilation of the wall of the vena centralis situated in the centre of the liver lobule, as

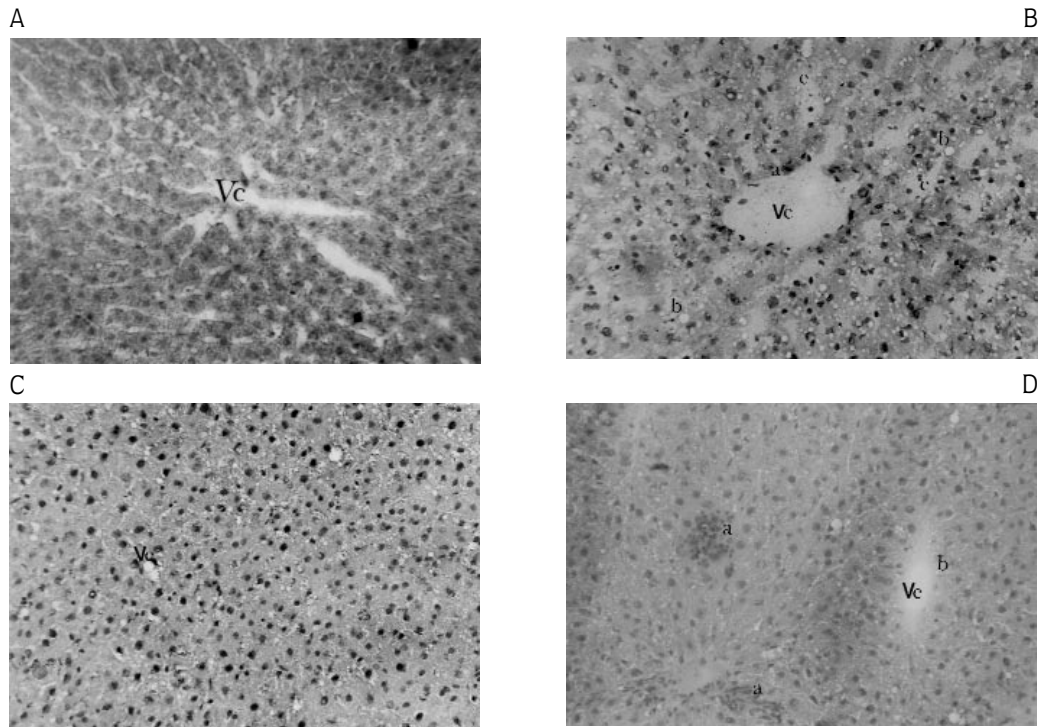


Figure 1. Histopathological effects of 400 ppm propineb on the livers of pregnant rats and of their one-day-old litters. (A) Control mother (H.E. Original magnification x 82). (B) Propineb-treated mother (H.E. Orig. magnific. x 82); a. Dilation at the wall of vena centralis, b. Vacuoles and hyalinisation in hepatocytes, c. Dilation of sinusoids between hepatocytes. (C) Control litter (H.E. Orig. magnific. x 82). (D) Propineb-receiving litter (H.E. Orig. magnific. x 82); a. Infiltration of the clustered inflammation cells, b. Dilation at the lumene of vena centralis. Vc. Vena centralis.

well as irregularity and degeneration in hepatocytes around the vein (Figure 1B). Moreover, an increase in the number of vacuoles and hyalinization were observed in hepatocytes. Figure 1b also shows a very clear dilation of the sinusoids between the hepatocytes. Similar effects were observed for the livers of one-day-old rat litters from propineb-treated mothers, except that an infiltration of clustered cells indicating inflammation was additionally observed (Figure 1D).

Figure 2 shows sections of the kidneys of the propineb-treated mothers and their one-day-old litters. Clear evidence of edema, cell degeneration, ripping of vein walls and dense hemorrhagia were all observed in the mothers. Also, hemorrhagia and free-floating erythrocytes between collector channels can be seen, as well as irregularities in the structure of tubules (Figure 2B). Histological examination of the kidney of one-day-old litters showed a clear edema in tubules around the glomeruli, an increase in vacuoles and hyalinization in cell cytoplasm, and hyperplasia in some cells of tubules (Figure 2D).

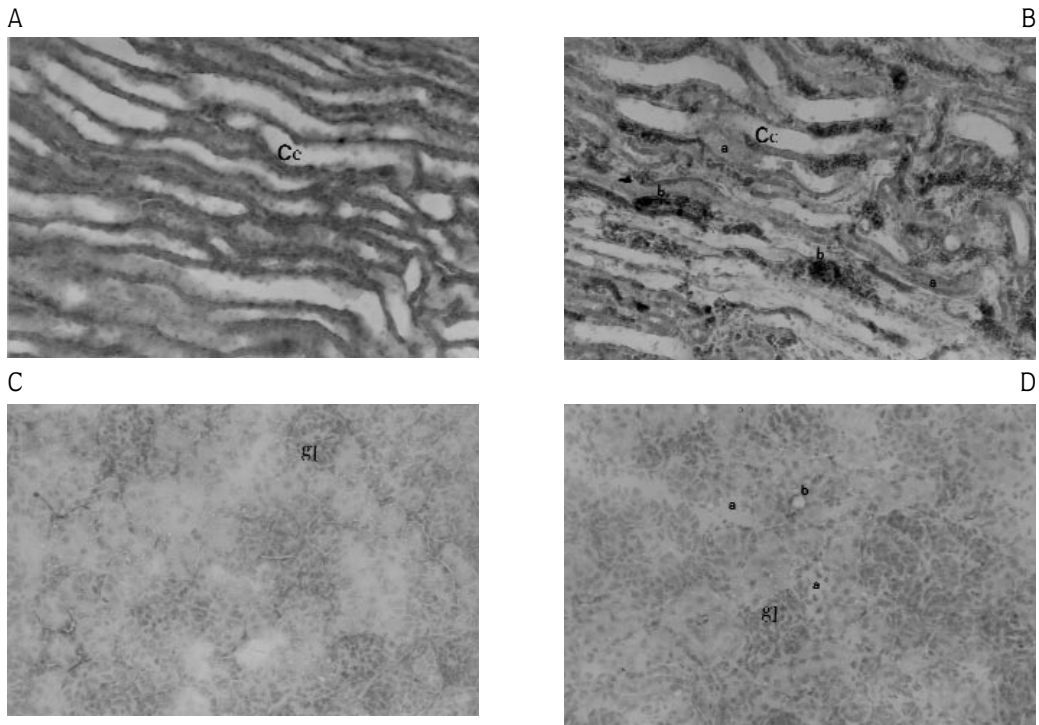


Figure 2. Histopathological effects of 400 ppm propineb on the kidneys of pregnant female rats and of their one-day-old litters, following exposure for the last two weeks of pregnancy. (A) Control mother (H.E. Original magnification x 100), Cc. Collector channel. (B) Propineb-treated mother (H.E. Orig. magnific. x 100); a. Edema in collector channels, b. Dense hemorrhagia at collector channels, Cc. Collector channel. (C) Control litter (H.E. Orig. magnific. x 82), gl. Glomerulus (D) Propineb-receiving litter (H.E. Orig. magnific. x 82); a. Edema at tubulus, b. Vacuoles and hyalinization between tubule cells, gl. Glomerulus.

As shown in Figure 3, we also analysed the accumulation of Zn in the organs of both litters and mothers exposed to propineb during pregnancy to examine the fate and accumulation of the trace metal. Zn concentrations in the liver, kidney and heart of fungicide-treated pregnant females were found to be significantly.

Significantly higher than those of the controls ($P < 0.002-0.05$). Differences in hepatic, renal and myocardial Zn concentrations were also very significant ($P < 0.001$) when comparing control with fungicide treated litters. High levels of zinc in these fetal organs suggest that the fungicide easily passes across the placental barrier. Studies on Beluga whales showed that they bioaccumulate organochlorines from their environment. Moreover, fetuses had about 10% higher concentrations than the mother, implying that transplacental transfer of organochlorines and lactation may lower contaminant concentrations in females while increasing levels in the

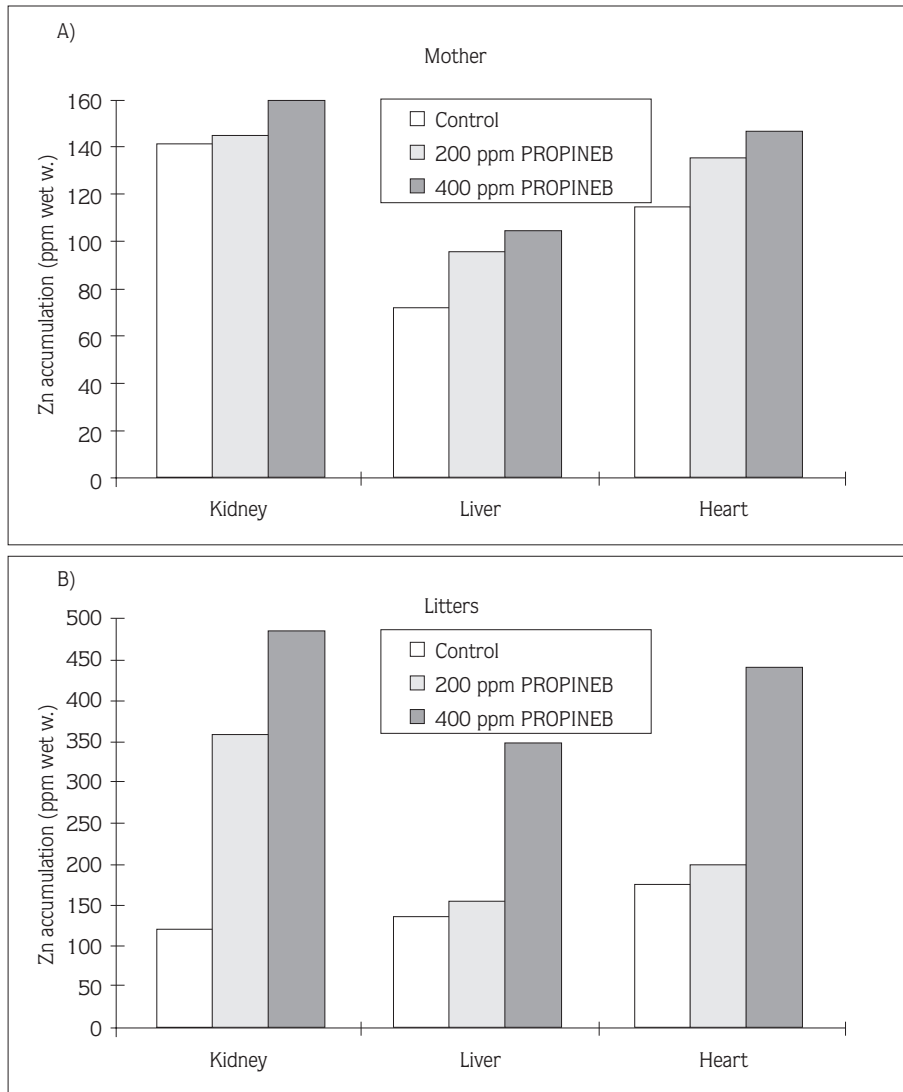


Figure 3. The accumulation of zinc in the organs of propineb-treated pregnant rats and of their one-day-old litters. Metal determinations were performed by ICP-AES (as described in Materials and Methods) in the livers, kidneys and hearts of female Wistar rats (a) and one-day-old litters (b), exposed to 200 and 400 ppm propineb during pregnancy. Data sets for the kidneys of controls are significantly different from those of propineb-treated female rats ($P < 0.05$), but very significant for livers ($P < 0.002$) and hearts ($P < 0.001$) of control and fungicide-treated females; data sets for all organs of propineb-treated litters are significantly higher than control values ($P < 0.001$). Each data point represents at least four determinations in separate experiments.

offspring (Wade et al., 1997). Exposure of pregnant rodents to heavy metals such as cadmium in late gestation has been shown to cause fetal death and placental necrosis. Fetal accumulation of metal was found to be higher due to the placental permeability to the toxicant (Lewin and Miller, 1981).

It is interesting to note that a high degree of fatty change occurred in most organs of the females administered with 400 ppm propineb. Zn is known to affect lipid peroxidation in biological membranes (Prasad, 1979). Some pesticides are already known to disrupt lipid metabolism (Timbrell, 1991). Abu el Zahad et al. (1991) have indicated a link between serum cholesterol levels and the metabolism of certain metals.

Comparisons between propineb-treated animals and those treated with zinc alone (at concentrations sufficient to cause a similar overall Zn accumulation pattern) will be needed to determine how far the toxicity of this fungicide can be attributed to its metal component. Since organometallic compounds enter cells much more readily than the inorganic metal ion (shown e.g. for Sn^{++} and tributyltin by Guven et al., 1994), at least part of their toxicity may remit from a rapid rise in intracellular metal concentrations. However, the metabolic fate of such compounds (metal release, excretion etc) and the toxicity of their organic moieties also requires further study.

References

1. Hassal, K.A. (1990). *The Biochemistry and Use of Pesticides: Structure, metabolism, mode of action and uses in crop protection*. VCH Publishers Inc., Weinheim and New York, p.263-361.
2. Ware, G.W. (1983). *Pesticides: Theory and Application*. W.H. Freeman and Company, p.293.
3. Lukens, R.J. (1971). *Chemistry of fungicidal action*. Springer-Verlag, New York and Berlin, p.125.
4. Teramoto, S., Kaneda, M. and Shirasu, Y. (1975). Teratogenicity of ethylenethiourea in rats. Relationship of dosage and time of administration to types of malformation. *Teratology*, 215-216.
5. Larsson, K.S., Arnander, C., Cekanova, E. and Kjellberg, M. (1976). Studies of teratogenic effects of the dithiocarbamates maneb, mancozeb and propineb. *Teratology*, 14: 171-184.
6. Subramoniam, A., Agrawal, D., Srivastava, S.P. and Seth, P.K. (1991). Influence of mancozeb on mitogenically responsive lipids in rat cerebrum and liver. *Indian J. Exp. Biol.* 29: 943-5.
7. Trivedi, N., Kakkar, R., Srivastava, M.K., Mithal, A. and Raizada, R.B. (1993). Effect of oral administration of fungicide-mancozeb on thyroid gland of rat. *Indian J. Exp. Biol.* 31: 564-6.
8. Vachkova-Petrova, R., Vassileva, L., Antov, G., Choumkov, N., Dontchev, N., Stavreva, M., Tyagounenko, E., Dineva, S., Halkova, J., Ivanova, T. and Dontchev, N. (1991). *J. Toxicol. Clin. Exp.* 11: 407-16.
9. Hasegawa, R., Cabral, R., Hoshiya, T., Hakoi, K., Ogiso, T., Boonyaphiphat, P., Shirai, T., and Ito, N. (1993). Carcinogenic potential of some pesticides in a medium-term multi-organ bioassay in rats. *Int. J. Cancer*. 54: 489-93.
10. Meco, G., Bonifati, V., Vanacore, N. and Fabrizio, E. (1994). Parkinsonism after chronic exposure to the fungicide maneb (manganese ethylene-bis-dithiocarbamate). *Scand. J. Work. Environ. Health*. 20: 301-305.
11. Soleo, L., Defazio, G., Scarcelli, R., Zefferino, R., Livrea, P. and Foa, V. (1996). Toxicity of fungicides containing ethylene-bis-dithiocarbamate in serumless dissociated mesencephalic-striatal primary coculture. *Arch. Toxicol.* 70: 678-82.

12. Kendrick, M.J., May, M.T., Plishka, M.J. and Robinson, K.D. (1992). *Metals in biological systems*. Ellis Horwood, New York and London, pp. 179.
13. Goyer, R.A. (1986). Toxic effects of metals (in Casarett and Doull's *Toxicology, The basic science of poisons* edited by Mary O. Amdur, John Doull and Curtis D. Klaassen), Pergamon Press, pp. 623-680.
14. Wlostowski, T. (1992). On metallothionein, cadmium, copper and zinc relationships in the liver and kidney of adult rats. *Comp. Biochem. Physiol.* 103C: 35-41.
15. Sowa, B. and Steibert, E. (1985). Effect of oral cadmium administration to female rats during pregnancy on zinc, copper, and iron content in placenta, foetal liver, kidney, intestine, and brain. *Arch. Toxicol.* 56: 256-262.
16. Bertholf, R.L. (1988). Zinc. (In *Handbook on toxicity of inorganic compounds*, edited by Seiler, H.G. and Sigel, H) Marcel Dekker, Inc. New York and Basel, pp. 787-800.
17. Prasad, A.S. (1979). Clinical, biochemical and pharmacological role of zinc. *Ann. Rev. Pharmacol. Toxicol.* 20: 393-426.
18. Worthing, C.R. (1983). *The Pesticide Manual*. British Crop Protection Council. p. 10180.
19. Cummings, A.M., Harris, S.T. and Rehnberg, G.L. (1990). Effects of methyl benzimidazolecarbamate during early pregnancy in the rat. *Fundam. Appl. Toxicol.* 15: 528-35.
20. Johnson, D.C., Sen, M., Ogo, H., Dey, S.K. (1990). Initiation of embryo implantation and maintenance of early pregnancy in the rat by chlordecone (Kepone)? *Proc. Soc. Exp. Biol. Med.* 195: 44-50.
21. Noda, T., Morita, S., Yamano, T., Shimizu, M. and Yamada, A. (1991). Effects of triphenyltin acetate on pregnancy in rats by oral administration. *Toxicol. Lett.* 56: 207-12.
22. Garry, V.F., Schreinemachers, D., Harkins, M.E. and Griffith, J. (1996). Pesticide applicators, biocides, and birth defects in rural Minnesota. *Environ. Health Perspect.* 104: 394-9.
23. Tas, S., Lauwerys, R. and Lison, D. (1996). Occupational hazards for the male reproductive system. *Crit. Rev. Toxicol.* 26: 261-307.
24. Jeffay, S.C., Libbus, B.L., Barbee, R.R. and Perreault, S.D. (1996). Acute exposure of female hamsters to carbendazim (MBC) during meiosis results in aneuploid oocytes with subsequent arrest of embryonic cleavage and implantation. *Reprod. Toxicol.* 10: 183-9.
25. Perreault, S.D., Jeffay, S., Poss, P. and Laskey, J.W. (1992). Use of the fungicide carbendazim as a model compound to determine the impact of acute chemical exposure during oocyte maturation and fertilization on pregnancy outcome in the hamster. *Toxicol. Appl. Pharmacol.* 114: 225-31.
26. Eroschenko, V.P., Abuel-Atta, A.A. and Grober, M.S. (1995). Neonatal exposures to technical methoxychlor alters ovaries in adult mice. *Reprod. Toxicol.* 9: 379-87.
27. Marchal-Segault, D. and Lauge, G. (1997). Ovarian activity of *Drosophila melanogaster* Meigen (Diptera), during a chronic intoxication with four fungicides: anatomical and cytological study. *J. Environ. Sci. Health B.* 32: 411-28.
28. Kackar, R., Srivastava, M.K. and Raizada, R.B. (1997). Induction of gonadal toxicity to male rats after chronic exposure to mancozeb. *Ind. Health.* 35: 104-11.
29. Beck, S.L. (1993). Additional endpoints and overview of a mouse skeletal variant assay for detecting exposure to teratogenesis. *Teratology.* 47: 147-157.
30. Price, C.J., Marr, M.C., Myers, C.B., Seely, J.C., Heindel, J.J. and Schwetz, B.A. (1996). The developmental toxicity of boric acid in rabbits. *Toxicol. Appl. Pharmacol.* 34: 176-87.
31. Srivastava, M.K. and Raizada, R.B. (1996). Developmental effect of technical dimethoate in rats: maternal and fetal toxicity evaluation. *Indian J. Exp. Biol.* 34: 329-33.
32. Branch, S., Rogers, J.M., Brownie, C.F. and Chernoff, N. (1996). Supernumerary lumbar rib: manifestation of basic alteration in embryonic development of ribs. *J. Appl. Toxicol.* 16: 115-9.

The Accumulation and Histological Effects of The Organometallic Fungicide Propineb on The Organs of Fetuses and Female Rats During Pregnancy

33. Tanaka, T., Fujitani, T., Takahashi, O., Oishi, S. and Yoneyama, M. (1995). Developmental toxicity study of piperonyl butoxide in CD rats. *Toxicol. Ind. Health*. 11: 175-84.
34. Chanda, S.M. and Pope, C.N. (1996). Neurochemical and neurobehavioral effects of repeated gestational exposure to chlorpyrifos in maternal and developing rats. *Pharmacol. Biochem. Behav.* 53: 771-6.
35. Wade, T.L., Chambers, L., Gardinall, P.R., Sericano, J.L., Jackson, T.J., Tarpley, R.J. and Suydam, R. (1997). Toxaphene, PCB, DDT, and Chlordane Analyses of Beluga whale blubber. *Chemosphere*, 34: 1351-7.
36. Lewin, A.A. and Miller, R.K. (1981). Fetal toxicity of cadmium in the rat: decreased utero-placental blood flow. *Toxicol. Appl. Pharm.* 58: 297-306.
37. Timbrell, J.A. (1991). *Principles of Biochemical Toxicology*. Taylor and Francis, London and Washington DC, p. 415.
38. Abu el Zahab, H.S., Abdel Aal, W.E., Awadallah, R., Mikhail, T.M. and Zakaria, K (1991). The correlation between serum cholesterol and some trace elements in serum, liver and heart of rats fed with high cholesterol diet. *Nahrung*, 35: 827-34.
39. Guven, K., Duce J.A. and Pomeria, D.I. (1994). Evaluation of a stress-inducible transgenic nematode strain for rapid aquatic toxicity testing. *Aquatic Toxic.* 29: 119-137.