

1-1-2009

Determination of diastolic dysfunction by conventional and Doppler tissue echocardiography in dogs

MURAT KİBAR

MATO MARKOVIC

URSULA S. KOLM

JOHANN THALHAMMER

Follow this and additional works at: <https://journals.tubitak.gov.tr/veterinary>



Part of the [Animal Sciences Commons](#), and the [Veterinary Medicine Commons](#)

Recommended Citation

KİBAR, MURAT; MARKOVIC, MATO; KOLM, URSULA S.; and THALHAMMER, JOHANN (2009)
"Determination of diastolic dysfunction by conventional and Doppler tissue echocardiography in dogs,"
Turkish Journal of Veterinary & Animal Sciences: Vol. 33: No. 6, Article 8. <https://doi.org/10.3906/vet-0808-25>

Available at: <https://journals.tubitak.gov.tr/veterinary/vol33/iss6/8>

This Article is brought to you for free and open access by TÜBİTAK Academic Journals. It has been accepted for inclusion in Turkish Journal of Veterinary & Animal Sciences by an authorized editor of TÜBİTAK Academic Journals. For more information, please contact academic.publications@tubitak.gov.tr.

Determination of diastolic dysfunction by conventional and Doppler tissue echocardiography in dogs*

Murat KİBAR^{1,**}, Mato MARKOVIC², Ursula S. KOLM², Johann THALHAMMER²

¹Department of Surgery, Faculty of Veterinary Medicine, Erciyes University, Kayseri - TURKEY

²Medical Clinic for Small Animals and Infectious Diseases, University of Veterinary Medicine Vienna,
Veterinärplatz 1, A-1210 Vienna - AUSTRIA

Received: 15.08.2008

Abstract: The aim of this study was to explore the feasibility and the diagnostic value of conventional Doppler parameters of transmitral inflows and Doppler tissue echocardiography parameters of septal annulus motion for the assessment of diastolic dysfunction in dogs with cardiac failure. The LV diastolic mitral flow patterns were divided into normal diastolic flow pattern (group 1), delayed relaxation pattern (group 2), pseudonormal flow pattern (group 3), and restrictive pattern (group 4). In our study population, 17 patients had normal mitral inflow variables (E/A ratio > 1 and $Dt < 109$ ms). The other 7 patients were classified as having abnormal mitral inflow pattern ($E' > 8$ cm/s, $E'/A' > 1$). In conclusion, the combination of Doppler tissue echocardiography of the mitral septal annulus and mitral inflow patterns by conventional Doppler indices provides better estimates of diastolic dysfunction in dogs.

Key words: Diastolic dysfunction, Doppler echocardiography, dog

Köpeklerde diyastolik disfonksiyonun konvansiyonel ve doku Doppler ekokardiyografi tekniği ile belirlenmesi

Özet: Bu çalışmanın amacı, kalp yetmezliği bulunan köpeklerde septal mitral kapağın doku Doppler ekokardiyografi parametrelerinin ve mitral kapak düzeyindeki kan akımı konvansiyonel Doppler parametrelerinin kullanılabilirliği ve tanıdaki değerinin araştırılmasıdır. Sol ventrikül diyastolik akım örnekleri, normal diyastolik mitral akım örneği (grup 1), gecikmiş relaksasyon örneği (grup 2), yanlış-normal akım örneği (grup 3) ve sınırlanmış akım örneği (grup 4) şeklinde bölümlendirildi. Çalışmamızdaki olgulardan 17 hastada normal mitral akım örneği (E/A oranı > 1 and $Dt < 109$ ms) vardı. Diğer 7 hasta ise anormal mitral akım örneği olarak ($E' > 8$ cm/s, $E'/A' > 1$) sınıflandırıldı. Sonuç olarak, mitral septal kapağın doku Doppler ekokardiyografik muayenesi ile mitral kan akımının konvansiyonel Doppler verilerinin birlikte kullanılması ile köpeklerde diyastolik disfonksiyonun yüksek güvenilirlikte değerlendirileceği kanısına varıldı.

Anahtar sözcükler: Diyastolik disfonksiyon, Doppler ekokardiyografi, köpek

* This study was supported by the Scientific and Technological Research Council of Turkey, TÜBİTAK.

** E-mail: muratkibar@erciyes.edu.tr

Introduction

Diastolic dysfunction is common in cardiac disease and contributes to the signs and symptoms of heart failure (1-3). Left ventricular diastolic dysfunction usually precedes systolic dysfunction, and abnormal relaxation is observed at its earliest stage (4-6). Doppler echocardiography has become the non-invasive technique of choice for evaluating diastolic function (4,7,8). Analysis of the mitral inflow velocity curve has provided useful information for determination of filling pressures and prediction of prognosis in selected patients. However, mitral flow is dependent on multiple interrelated factors, including the rate and extent of ventricular relaxation, suction, atrial and ventricular compliance, mitral valve inertance, heart rate, and left atrial pressure (1,3). Among the many Doppler indices used to describe diastolic dysfunction, the ratio of the peak early to the peak atrial mitral inflow velocities (E/A ratio), the deceleration time of the peak early inflow (D_e), and isovolumic relaxation time (IVRT) have been the most widely used and are recommended in the latest guidelines for diagnosing diastolic dysfunction (2,7-12). In the setting of an increase in left ventricle (LV) and left atrial filling pressures, the transmitral pressure gradient rises. As a consequence, pseudonormalisation (PN) of the mitral inflow may mask diastolic dysfunction (8,10).

Doppler tissue echocardiography (DTE), a new application recently developed for clinical use, has made possible the acquisition of myocardial wall and mitral annular velocities online during examination (13,14). Early diastolic annular velocity measured using DTE has already been reported to be a preload independent index for evaluating left ventricular

diastolic function. However, the usefulness of these measurements for the identification of PN of mitral inflow has not been well described (9,13,15-18).

Doppler echocardiographic variables of left ventricular (LV) filling and DTE variables of mitral annular motion can predict a determination and differentiation of diastolic dysfunction in dogs with cardiac failure. The aim of this study was to explore the feasibility and the diagnostic value of conventional Doppler parameters of transmitral inflows and DTE parameters of septal annulus motion for the assessment of diastolic dysfunction in dogs with cardiac failure.

Materials and methods

Thirty-one consecutive patients (age 4.0-14.5 years; mean (SD) age, 10.25 (3) years; body weight 2.7-30.0 kg; mean (SD) weight, 8.65 (5.6) kg; 17 male, 14 female) with normal and diastolic dysfunction were studied prospectively. Imaging was done in the right and left lateral recumbency positions using Via 5 (USA) with a multifrequency transducer (4.0-7.5 MHz) equipped with Doppler tissue imaging software. For each patient, an ECG was simultaneously recorded. The M-mode and 2-D echocardiographic examinations were performed using standard views and techniques according to the guidelines of the American Society of Echocardiography (19). Mitral inflow and DTE signals were recorded in all patients. The peak Doppler velocities, early (E) and late diastolic flow (A), the deceleration time (D_e), and the E/A ratio were measured (Figure 1). The LV diastolic mitral flow

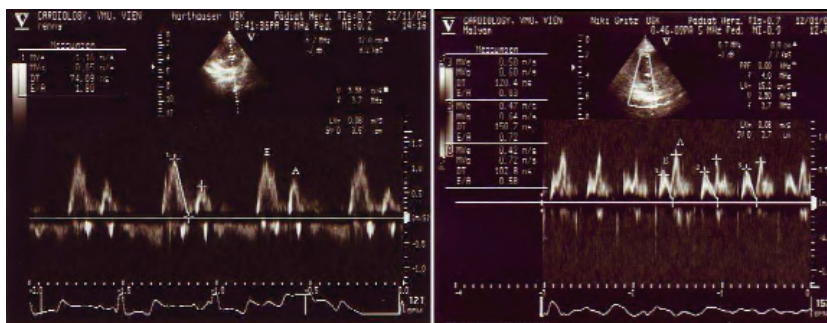


Figure 1. Normal mitral inflow pattern (a) and delayed relaxation pattern (b) in dogs. Note the magnitude of the late diastolic filling velocity (A) than early diastolic filling velocity (E) in delayed relaxation.

pattern was divided into normal diastolic flow pattern (group 1), delayed relaxation pattern (group 2), pseudonormal flow pattern (group 3), and restrictive pattern (group 4, Figure 2) as previously described (19).

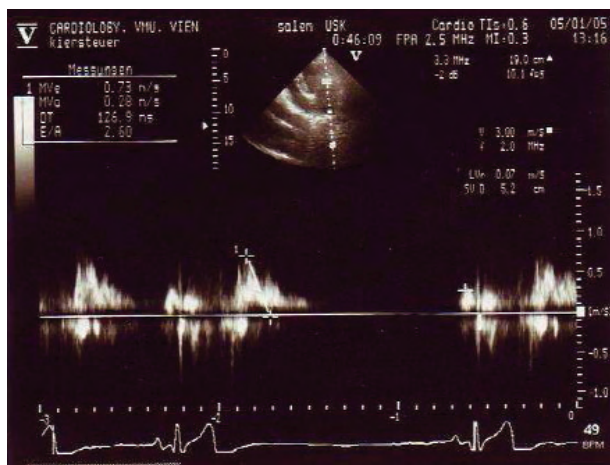


Figure 2. Restrictive flow pattern in dogs. Note the magnitude of the early diastolic filling velocity (E) than late diastolic filling velocity (A) in restrictive pattern ($E/A > 2$).

DTE of the mitral annulus was also obtained from the apical 4-chamber view. Analysis was performed for early diastolic velocity (E'), late diastolic velocity (A'), E'/A' ratio, and E'/E ratio (Figure 3).

Data are expressed as the mean value \pm standard deviation (SD). Group data were compared using the

unpaired Student's t test or analysis of variance (ANOVA) with Duncan's test, where appropriate. Receiver operating characteristic (ROC) curve analysis was performed to test the predictive discrimination of patients with or without PN. A difference was considered significant at $P < 0.05$.

Results

Seventeen patients (55%) had mitral valve insufficiency (MVI)-degree III, 7 (22.5%) had MVI-degree II, and 7 (22.5%) had MVI-degree I. Nine patients (29%) had tricuspidal valve insufficiency (TVI)-degree II, 16 (52%) had TVI-degree I, and 6 (19%) had no TVI. Clinical data and the values of echocardiographic measurements are given in Table 1. Patients with normal inflow, patients with delayed relaxation, patients with PN, and patients with restrictive pattern did not differ significantly with respect to age, heart rate, or body weight.

Doppler-derived variables and variables derived from DTE analysis of mitral septal annulus motion are given in Table 2.

All 31 study subjects underwent Doppler echocardiographic examination of mitral inflow and DTI of mitral annulus. In our study population, 17 patients had normal mitral inflow variables (E/A ratio > 1 and $D_t < 109$ ms). Of these 17 patients, 10 had an $E' < 8$ cm/s, $E'/A' < 1$, and were accordingly classified as having a pseudonormal mitral inflow pattern. The other 7 patients were classified as having a normal mitral inflow pattern ($E' > 8$ cm/s, $E'/A' > 1$). Early

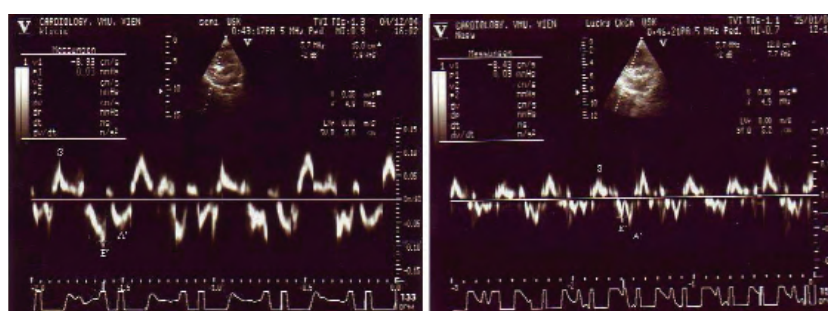


Figure 3. Septal mitral annular velocities measured using Doppler tissue echocardiography (DTE) in dogs with normal (a) and pseudonormal flow (PN, b). Note the reduction of the early diastolic velocity of the annulus (E') in PN group. E' , early diastolic velocity of mitral annulus; A' , late diastolic velocity of mitral annulus.

Table 1. Analysis of clinical data and the values of echocardiographic measurements for each group.

	Group 1	Group 2	Group 3	Group 4
Number	8	7	10	6
Sex (M/F)	5/3	1/6	7/3	3/3
Age (years) (range)	11.40 ± 2.33 (7.0-14.5)	10.85 ± 2.34 (7.0-14.5)	9.73 ± 3.07 (6.0-14.5)	10.24 ± 2.92 (4.0-13.5)
Heart Rate (bpm) (range)	137 ± 29 (98-180)	120 ± 21 (96-155)	147 ± 28 (80-180)	145 ± 24 (115-185)
BW (kg) (range)	7.37 ± 3.17 (2.7-12.0)	10.48 ± 6.80 (4.3-23.1)	6.32 ± 2.14 (3.8-10.0)	12.11 ± 9.13 (5.5-30.0)
LA/Ao ratio	1.80 ± 0.33a (1.50-2.30)	1.24 ± 0.31b (0.85-1.86)	1.80 ± 0.21a (1.51-2.15)	2.17 ± 0.24a (1.89-2.61)
FS (%)	46 ± 6 (36-54)	36 ± 6 (29-45)	45 ± 7 (36-57)	36 ± 15 (12-47)
LVDd (mm)	34.89 ± 7.89a (25.94-46.75)	30.25 ± 5.99a (21.56-38.45)	35.14 ± 5.35a (28.12-45.42)	49.80 ± 11.29b (35.89-68.48)

All values were expressed as mean ± SD. HR: heart rate, bpm: beats per minute, BW: body weight, LA/Ao ratio: a ratio of left atrial and aortic diameter, FS: fractional shortening, LVDd: left ventricular diastolic diameter. Group I: dogs with normal mitral inflow, Group II: dogs with delayed relaxation, Group III: dogs with pseudonormal mitral inflow, and Group IV: dogs with restrictive pattern.

^{a,b} Difference is statistically significant in groups with different superscripts in the same row (P < 0.05).

diastolic annular velocity (E') was lower in group 3 (PN) than in group 1. Septal mitral annular velocities between groups are shown in Table 2. Eight patients had delayed relaxation (E/A ratio < 1, D_t > 109 ms, and E' < 8 cm/s). Additionally, 6 patients had a restrictive pattern in our study (E/A > 2 and E' < 8 cm/s). All subjects with PN had moderate (n = 3) and severe (n = 7) mitral valve insufficiency. In the PN group, a significant reduction in E'/A' (0.71 ± 0.10, P < 0.01) and a significant increase in A' (10.35 ± 3.60 cm/s, P < 0.01) and E/E' (14.32 ± 3.50, P < 0.05) were detected. E' velocity was lower in group 1 than in group 3 (9.02 ± 2.90 cm/s vs. 7.46 ± 2.17 cm/s, P = ns). Using ROC curve analysis, A' yielded an area under the curve of 0.944 ± 0.06 (±standard error of mean [SEM]) for the separation of patients with PN versus without PN (P = 0.002). When the combination of A' > 7.6 cm/s and E'/A' < 1 was used as a cut point, PN could be identified with a sensitivity of 90% and a specificity of 88%.

Discussion

Diastolic dysfunction has been established as a component of heart failure that can predict adverse outcomes (2,20-22). It is questionable to assume that all patients with symptoms of heart failure and normal systolic function have diastolic heart failure (2). The non-invasive assessment of LV diastolic function by pulsed Doppler can be an important clinical tool in humans and dogs (9,22-26). Transmitral parameters have been shown to be useful in patients with LV diastolic dysfunction (1). However, E and E/A derived from the pulsed Doppler of mitral inflow have the potential to show pseudonormalisation of LV diastolic dysfunction (7,22). In such conditions, although left ventricular diastolic pressure may be raised, left atrial pressure is expected to be markedly high, resulting in enhanced early diastolic filling velocity. Similarly, "pseudonormalisation" of transmitral flow velocity pattern observed in poor left ventricular function may be due to increased left atrial pressure (1,15,17).

Table 2. Analysis of Doppler-derived variables and variables derived from DTE analysis of mitral septal annulus motion for each group.

	Group 1	Group 2	Group 3	Group 4
E (cm/s)	1.00 ± 0.26a (0.70-1.40)	0.55 ± 0.15b (0.36-0.81)	1.03 ± 0.13a (0.85-1.32)	1.30 ± 0.25a (1.01-1.65)
A (cm/s)	0.72 ± 0.10 (0.59-0.88)	0.64 ± 0.14 (0.52-0.82)	0.74 ± 0.13 (0.63-1.06)	0.61 ± 0.12 (0.48-0.84)
E/A ratio	1.39 ± 0.33ac (1.13-1.95)	0.84 ± 0.11b (0.67-0.99)	1.44 ± 0.24a (1.04-1.75)	2.12 ± 0.26c (1.76-2.52)
Dt (ms)	89.94 ± 17.29a (51.45-110.60)	110.51 ± 40.22ab (69.43-172.80)	85.66 ± 23.84a (61.36-124.70)	140.22 ± 42.37a (106.10-223.40)
E' (cm/s)	9.02 ± 2.90a (6.11-15.25)	5.16 ± 1.14b (3.16-7.0)	7.46 ± 2.17ab (4.73-12.35)	7.56 ± 1.92ab (4.35-10.36)
A' (cm/s)	5.92 ± 1.62a (3.83-9.0)	6.71 ± 2.50a (4.0-12.0)	10.35 ± 3.60b (7.30-20.0)	5.69 ± 2.39a (3.13-10.13)
E'/A' ratio	1.50 ± 0.49a (1.11-2.35)	0.80 ± 0.28b (0.55-1.40)	0.71 ± 0.10b (0.54-0.84)	1.38 ± 0.24a (1.02-1.77)
E/E' ratio	11.10 ± 1.54a (8.90-13.28)	10.58 ± 2.46a (7.20-14.41)	14.32 ± 3.50ab (7.60-20.14)	18.12 ± 5.64b (13.35-28.0)

All values were expressed as mean ± SD. E: the peak early diastolic velocity of LV inflow, A: the peak late diastolic velocity of LV inflow, E/A ratio: a ratio of E to A, Dt: deceleration time, E': the peak early diastolic velocity of septal mitral annulus, A': the peak late diastolic velocity of septal mitral annulus, E'/A' ratio: a ratio of E' to A', E/E' ratio: a ratio of E to E'. Group I: dogs with normal mitral inflow, Group II: dogs with delayed relaxation, Group III: dogs with pseudonormal mitral inflow, and Group IV: dogs with restrictive pattern.

^{a,b,c} Difference is statistically significant in groups with different superscripts in the same row ($P < 0.05$).

The present study confirms that E and E/A ratio significantly differ in group 2. Healthy ventricles that maintain early diastolic suction forces may also manifest a relatively increased E and high E/A ratio. In this study, we determined E wave velocity reduction and $E/A < 1$ in dogs with delayed relaxation.

DTE has been proposed as a new technique for the measurement of the velocity of annular motions and the assessment of cardiac function during diastole, whereas the traditional pulsed Doppler is used for the determination of various laminar blood flow velocities (1,18). As observed in our study, the measurement of the velocity of septal annulus motions was possible using DTE in dogs with

diastolic dysfunction. With systolic contraction, there is long-axis shortening of the LV manifest by mitral annular descent toward a relatively fixed apex. In patients in sinus rhythm, the annulus ascends in 2 phases. Pulsed-wave DTE provides the velocity profile of these movements. These velocities may not be dependent on pressure gradients as is blood flow (1,16). In our study, we investigated variables derived from DTE (E', A', E'/A', E/E') of septal mitral annulus in dogs with diastolic dysfunction. E' velocity of group 1, group 3, and group 4 were not significantly different, and the values of group 1 differed significantly from those of group 2. However, E' velocity was higher than 8 cm/s in the normal group and less than 8 cm/s in the PN group.

Combining transmitral flow velocity with annular velocity (E/E') has been proposed as a tool for assessing LV filling pressures that combines the influence of transmitral driving pressure and myocardial relaxation (1,15,17). In the present study, this combined variable was the best single Doppler predictor of elevated filling pressures. In small animal medicine, it has been demonstrated that, for the lateral mitral annulus, E/E' greater than 9.1 indicates a 95% probability that mean left atrial pressure was greater than 20 mmHg (22,27). In contrast, E/E' at a cut-off value of 12 had good sensitivity and specificity for identifying pseudonormal mitral inflow in our study. E/E' , therefore, can be clinically applied to detect PN in dogs with cardiac failure. Patients with $E/E' > 12$ can be classified as having elevated filling pressure. An $E/E' < 8$ suggests normal filling pressure. In the range of E/E' of 8 to 12, other information must be applied such as left atrial size. Prior investigations also point out the importance of considering left atrial size in assessing filling pressures (1).

The motion of the mitral annulus mainly reflects the longitudinal vector of myofibre shortening and lengthening as the cardiac apex is relatively fixed during the cardiac cycle (10,26). Normally, the mitral annulus moves down toward the ventricle during

systole and it moves up toward the atrium in early diastole and atrial systole, a pattern that was also observed in our study. The main objective of our investigation was to focus on diastolic septal annular motion as a marker of LV relaxation and a tool for the identification of PN. According to $E/A > 1$ and $E'/A' < 1$, 10 subjects were classified as having PN. These subjects had a preserved systolic LV function, but symptoms of heart failure. In the PN group, both late diastolic annular velocity (A') and the E'/A' ratio were significantly reduced, compared to the normal group. Conventional Doppler-derived echocardiographic parameters (E , A , E/A ratio, Dt) did not discriminate between the normal and PN groups. Using the combination of $A' > 7.6$ cm/s and $E/E' > 12.34$ as a cut point (derived from ROC curve analysis), a pseudonormal mitral inflow was detected with a sensitivity of 83% and specificity of 79%.

In conclusion, the combination of Doppler tissue echocardiography of the mitral septal annulus and mitral inflow patterns by conventional Doppler indices provides better estimates of diastolic dysfunction in dogs. Doppler tissue echocardiography appears to be a useful parameter for assessing diastolic dysfunction in dogs with a pseudonormal mitral inflow pattern and elevated filling pressures.

References

1. Ommen, S.R., Nishimura, R.A., Appleton, C.P., Miller, F.A., Oh, J.K., Redfield, M.M., Tajik, A.J.: Clinical utility of Doppler echocardiography and tissue Doppler imaging in the estimation of left ventricular filling pressures: A comparative simultaneous Doppler-catheterization study. *Circulation*, 2000; 102: 1788-1794.
2. Schirmer, H., Lunde, P., Rasmussen, K.: Mitral flow derived Doppler indices of left ventricular diastolic function in a general population; the Tromso study. *Eur. Heart J.*, 2000; 21: 1376-1386.
3. Nishimura, R.A., Tajik, A.J.: Evaluation of diastolic filling of left ventricle in health and disease: Doppler echocardiography is the clinician's Rosetta Stone. *J. Am. Coll. Cardiol.*, 1997; 30: 8-18.
4. Yalçın, F., Kaftan, A., Müderrisoğlu, H., Korkmaz, M.E., Flachskampf, F., Garcia, M., Thomas, J.D.: Is Doppler tissue velocity during early left ventricular filling preload independent? *Heart*, 2002; 87: 336-339.
5. Grossman, W.: Diastolic dysfunction and congestive heart failure. *Circulation*, 1990; 81 (Suppl. 2): 1-7.
6. Ishida, Y., Meisner, J.S., Tsujioka, K., Gallo, J.I., Yoran, C., Frater, R.W., Yellin, E.L.: Left ventricular filling dynamics: influence of left ventricular relaxation and left atrial pressure. *Circulation*, 1986; 74: 187-196.
7. Nishimura, R.A., Abel, M.D., Hatle, L.K., Tajik, A.J.: Assessment of diastolic function of the heart: background and current applications of Doppler echocardiography. Part II. Clinical studies. *Mayo Clin. Proc.*, 1989; 64: 181-204.
8. Thomas, J.D., Weyman, A.E.: Echocardiographic Doppler evaluation of left ventricular diastolic function. *Physics and physiology*. *Circulation*, 1991; 84: 977-990.
9. Appleton, C.P., Hatle, L.K., Popp, R.L.: Relation of transmitral flow velocity patterns to left ventricular diastolic function: new insights from a combined hemodynamic and Doppler echocardiographic study. *J. Am. Coll. Cardiol.*, 1988; 12: 426-440.
10. Bruch, C., Schmermund, A., Bartel, T., Schaar, J., Erbel, R.: Tissue Doppler imaging: a new technique for assessment of pseudonormalization of the mitral inflow pattern. *Echocardiography*, 2000; 17: 539-546.

11. Choong, C.Y., Abascal, V.M., Thomas, J.D., Guerrero, J.L., McGlew, S., Weyman, A.E.: Combined influence of ventricular loading and relaxation on the transmitral flow velocity profile in dogs measured by Doppler echocardiography. *Circulation*, 1988; 78: 672-683.
12. Appleton, C.P., Galloway, J.M., Gonzalez, M.S., Gaballa, M., Basnight, M.A.: Estimation of left ventricular filling pressures using two-dimensional and Doppler echocardiography in adult patients with cardiac disease. Additional value of analyzing left atrial size, left atrial ejection fraction and the difference in duration of pulmonary venous and mitral flow velocity at atrial contraction. *J. Am. Coll. Cardiol.*, 1993; 22: 1972-1982.
13. Matsumura, Y., Elliott, P.M., Virdee, M.S., Sorajja, P., Doi, Y., McKenna, W.J.: Left ventricular diastolic function assessed using Doppler tissue imaging in patients with hypertrophic cardiomyopathy: relation to symptoms and exercise capacity. *Heart*, 2002; 87: 247-251.
14. Bruch, C., Marin, D., Kuntz, S., Schmermund, A., Bartel, T., Schaar, J., Erbel, R.: Analysis of mitral annulus excursion with tissue Doppler echocardiography (tissue Doppler echocardiography = TDE). Noninvasive assessment of left ventricular, diastolic dysfunction. *Z. Kardiol.*, 1999; 88: 353-362. (article in German with an abstract in English)
15. Nagueh, S.F., Lakkis, N.M., Middleton, K.J., Spencer, W.H.3rd., Zoghbi, W.A., Quiñones, M.A.: Doppler estimation of left ventricular filling pressures in patients with hypertrophic cardiomyopathy. *Circulation*, 1999; 99: 254-261.
16. Sohn, D.W., Chai, I.H., Lee, D.J., Kim, H.C., Kim, H.S., Oh, B.H., Lee, M.M., Park, Y.B., Choi, Y.S., Seo, J.D., Lee, Y.W.: Assessment of mitral annulus velocity by Doppler tissue imaging in the evaluation of left ventricular diastolic function. *J. Am. Coll. Cardiol.*, 1997; 30: 474-480.
17. Nagueh, S.F., Middleton, K.J., Kopelen, H.A., Zoghbi, W.A., Quiñones, M.A.: Doppler tissue imaging: a noninvasive technique for evaluation of left ventricular relaxation and estimation of filling pressures. *J. Am. Coll. Cardiol.*, 1997; 30: 1527-1533.
18. Garcia, M.J., Rodriguez, L., Ares, M., Griffin, B.P., Thomas, J.D., Klein, A.L.: Differentiation of constrictive pericarditis from restrictive cardiomyopathy: assessment of left ventricular diastolic velocities in longitudinal axis by Doppler tissue imaging. *J. Am. Coll. Cardiol.*, 1996; 27: 108-114.
19. Schiller, N.B., Shah, P.M., Crawford, M., DeMaria, A., Devereux, R., Feigenbaum, H., Gutgesell, H., Reichek, N., Sahn, D., Schnittger, I.: Recommendations for quantitation of the left ventricle by two dimensional echocardiography. American Society of Echocardiography Committee on Standards, Subcommittee on Quantitation of Two-Dimensional Echocardiograms. *J. Am. Soc. Echocardiogr.*, 1989; 2: 358-367.
20. Nishimura, R.A., Tajik, A.J.: Quantitative hemodynamics by Doppler echocardiography: a noninvasive alternative to cardiac catheterization. *Prog. Cardiovasc. Dis.*, 1994; 36: 309-342.
21. Xie, G.Y., Berk, M.R., Smith, M.D., Gurley, J.C., DeMaria, A.N.: Prognostic value of Doppler transmitral flow patterns in patients with congestive heart failure. *J. Am. Coll. Cardiol.*, 1994; 24: 132-139.
22. Teshima, K., Asano, K., Sasaki, Y., Kato, Y., Kutara, K., Edamura, K., Hasegawa, A., Tanaka, S.: Assessment of left ventricular function using pulsed tissue Doppler imaging in healthy dogs and dogs with spontaneous mitral regurgitation. *J. Vet. Med. Sci.*, 2005; 67: 1207-1215.
23. Kirberger, R.M., Bland-vanden Berg, P., Darazs, B.: Doppler echocardiography in the normal dog. Part I: Velocity findings and flow patterns. *Vet. Radiol. Ultrasound*, 1991; 33: 370-379.
24. Kirberger, R.M., Bland-vanden Berg, P., Grimbeek, R.J.: Doppler echocardiography in the normal dog. Part II: Factors influencing blood flow velocities and a comparison between left and right heart blood flow. *Vet. Radiol. Ultrasound*, 1991; 33: 380-386.
25. Schober, K.E., Fuentes, V.L.: Effects of age, body weight, and heart rate on transmitral and pulmonary venous flow in clinically normal dogs. *Am. J. Vet. Res.*, 2001; 62: 1447-1454.
26. Schober, K.E.: Doppler echocardiographic assessment of ventricular function-time to move to the right? *J. Vet. Intern. Med.*, 2005; 19: 785-787.
27. Oyama, M.A., Sisson, D.D., Bulmer, B.J., Constable, P.D.: Echocardiographic estimation of mean left atrial pressure in a canine model of acute mitral valve insufficiency. *J. Vet. Intern. Med.*, 2004; 18: 667-672.