

1-1-2010

Successful management of a delayed case of a corneal foreign body in a cow

MUJEEB-UR-REHMAN FAZILI

BASHIR AHMED BUCHOO

HIRANYA KUMAR BHATTACHARYYA

Follow this and additional works at: <https://journals.tubitak.gov.tr/veterinary>



Part of the [Animal Sciences Commons](#), and the [Veterinary Medicine Commons](#)

Recommended Citation

FAZILI, MUJEEB-UR-REHMAN; BUCHOO, BASHIR AHMED; and BHATTACHARYYA, HIRANYA KUMAR (2010) "Successful management of a delayed case of a corneal foreign body in a cow," *Turkish Journal of Veterinary & Animal Sciences*: Vol. 34: No. 3, Article 12. <https://doi.org/10.3906/vet-0804-12>
Available at: <https://journals.tubitak.gov.tr/veterinary/vol34/iss3/12>

This Article is brought to you for free and open access by TÜBİTAK Academic Journals. It has been accepted for inclusion in Turkish Journal of Veterinary & Animal Sciences by an authorized editor of TÜBİTAK Academic Journals. For more information, please contact academic.publications@tubitak.gov.tr.

Successful management of a delayed case of a corneal foreign body in a cow

Mujeeb-ur-Rehman FAZILI*, Bashir Ahmed BUCHOO, Hiranya Kumar BHATTACHARYYA

Teaching Veterinary Clinical Complex, Faculty of Veterinary Sciences and Animal Husbandry, Sheri Kashmir University of Agricultural Sciences and Technology of Kashmir, Shuhama-Alusteng, Srinagar, Jammu and Kashmir State - INDIA

Received: 07.04.2008

Abstract: A crossbred Jersey cow had been suffering from severe pain for 3 days due to a corneal foreign body. Tranquilization using intravenous triflupromazine (20 mg) followed by Peterson nerve block with 2% lidocaine hydrochloride (13 mL) facilitated examination of the eye and removal of a 12-mm-long (7 mm penetrated plus 5 mm protruding out) dry plant awn from the cornea. Corneal opacity was noted around the puncture site. Direct ophthalmoscopy did not reveal any abnormality in the ocular media. Topical gentamycin (3 mg/mL) and systemic gentamycin (5 mg/kg), along with meloxicam (0.2 mg/kg) for 3 days, followed (on the basis of antibiotic sensitivity) by topical chloramphenicol (5%) for 2 weeks healed the site. Complete resolution of the opacity took an additional 15 days.

Key words: Foreign body, cornea, cow, opacity, Peterson block

Introduction

Corneal foreign bodies of plant origin are frequently observed in food animals (1). Due to continuous irritation, animals are subjected to severe pain and discomfort. Self-inflicted damage and that caused by futile attempts by owners to remove the foreign object or treat this extremely delicate organ exacerbate the condition. As this constitutes an ocular emergency, most of the relevant data pertain to cases treated following minimal delay. Herein we present the clinical picture and successful management of a cow that had been suffering from severe pain for 3 days due to a corneal foreign body.

Case history

A 2.5-year-old crossbred Jersey cow in the 7th month of her 1st pregnancy presented with a history of sudden onset of pain in the left eye that began 3 days earlier. The condition was observed after the animal returned from daily grazing in an area with tall grasses. No treatment was provided to the animal during the ensuing period.

Severe epiphora, blepharospasm, and conjunctivitis in the left eye were observable from a distance (Figures 1 and 2). Ocular examination was difficult due to severe enophthalmia, blepharospasm, and continual downward rolling of the eyeball.

Ten minutes after intravenous administration of triflupromazine 0.1 mg/kg (20 mg/mL siquil,

* E-mail: fazili_mr@yahoo.co.in




Figure 1. Blepharospasm and epiphora.

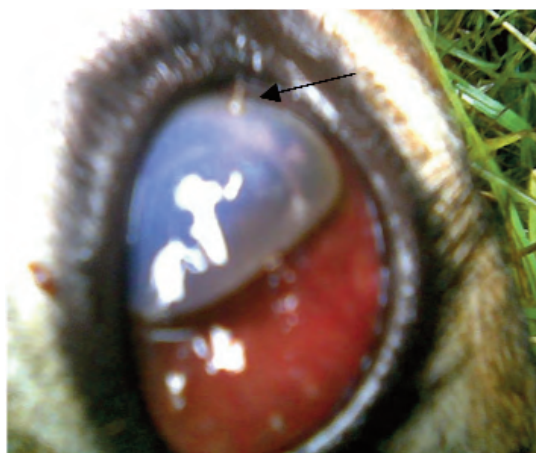


Figure 2. Penetrating foreign body in cornea and conjunctivitis.

Sarabhai), the animal was cast in right lateral recumbency. Peterson nerve block (including the auriculopalpebral nerve) was given using 13 mL of 2% lidocaine hydrochloride (gesicain, Astra Lab). Dry plant material was observed to have penetrated vertically 1 cm from the center in the lower half of the corneal surface of the left eye (Figure 2). The exposed length of the foreign body was 0.5 cm. Using a hemostat close to the corneal surface, the plant material was carefully removed without breaking (Figure 3). After taking a swab from the depression

(0.5 cm in diameter caused by the foreign body, Figure 3) and the area around it, direct ophthalmoscopic examination was performed to visualize any abnormality in the ocular media. The eyeball was irrigated with normal saline. Saline irrigation was repeated every 15 min for the next 4 h. Postoperatively, intravenous meloxicam (0.2 mg/kg, melonex, Intas) once daily and intramuscular gentamycin (5 mg/kg, gentamycin, Wockhardt) twice daily were prescribed for 3 consecutive days. Then 3-4 gentamycin (garamycin, 3 mg/mL, Fulford) and atropine (astro, 1%, (Intas) eye drops were instilled every 6 h for the next 3 days. On the basis of an antibiotic sensitivity report the eye drops were changed to chloramphenicol (5% chloromycetin, Parke-Davis) for 2 more weeks.

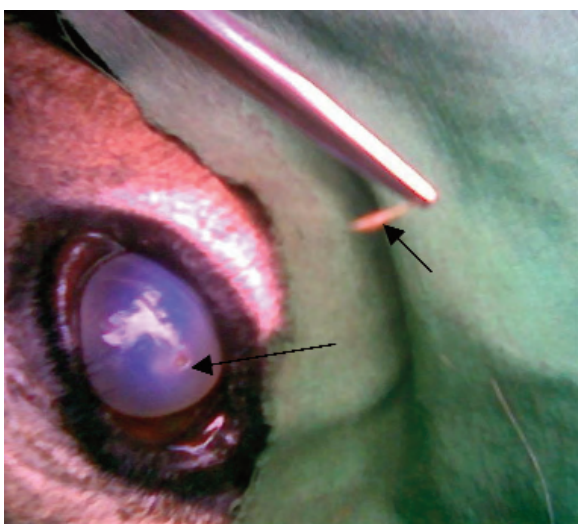


Figure 3. Pulled out foreign body, depression at the site of foreign body penetration.

Results and discussion

Motor paralysis of the eyelids, along with analgesia and stasis of the eyeball resulted after 5 min of Peterson nerve block. The withdrawn plant foreign body measured 1.2 cm in length and 0.5 cm in diameter (Figure 4). The surface of the material was smooth, and 3 small thickened areas gave it a beaded appearance. A circular zone of corneal opacity (1 cm in diameter) was also present around the foreign body (Figure 3). Due to corneal opacity and edema, the portion of the plant material inside the anterior chamber could not be visualized. Only subtle changes were noted within the anterior chamber. Additionally,



Figure 4. Foreign body 1.2 cm in length and 0.5 cm in diameter.

direct ophthalmoscopic examination did not reveal any appreciable change in the ocular media. Resolution of the symptoms and regaining of sight were reported by the owner after 2 weeks. Clinical examination 3 weeks postoperatively confirmed these findings; however, a 0.25-cm circular scar was still visible at the site of the foreign body penetration.

The eye is an extremely delicate organ with an ample sensory nerve supply. This is especially evident in the cornea, in which a network of sensory nerves is located at a very superficial level, as reported by Williams et al. (2). Rebhun (3) reported that corneal foreign bodies consisting of plant material might be embedded in the cornea to variable depths following exposure to strong winds, blowers, or fans, which can cause feed to become embedded in the eyes, or following accidental trauma due to plant materials. Foreign bodies are an obvious potential cause of irritation, leading to signs of ocular pain, conjunctival injection, and lid swelling. Often, the pain associated with a corneal foreign body precludes detailed examination.

Tranquilization with triflupromazine calmed the young nervous animal we treated. Motor paralysis of the eyelids, along with stasis and bulging of the eyeball, was sufficient to fully examine the corneal surface. Blocking of the auriculopalpebral nerve alone greatly facilitates examination of the painful bovine

eye, but retrobulbar muscle spasm may result in considerable enophthalmos, which again complicates examination. Peterson block ameliorates this problem, as reported by Lavach (4). According to Pearce et al. (5), retrobulbar nerve block is considered more reliable than Peterson nerve block, but is associated with a greater risk of complications.

Following establishment of anesthesia in the present case, the plant material lodged in the cornea was easily located. Only subtle changes were noted in the anterior chamber. Corneal opacity was observed around the site of the foreign body penetration. This might have been due to the long delay in treatment. Presence of a foreign body in the cornea beyond 24 h provokes an inflammatory infiltrate and graded degradation of the surrounding stroma, as reported by Williams et al. (2).

The foreign body in the present case consisted of a single piece of dry grass awn that was completely removed without a break or bend. According to an earlier report by Williams et al. (2), plant material can be difficult to remove in one piece and if it remains embedded in the stroma for an extended time the chances of disintegration increase.

At the time the foreign material was removed in the present case leakage of the aqueous humor did not occur and the puncture site sealed instantly; however, the surface appeared depressed at this spot. Although the material could not be visualized inside the cornea before removal, the vertical direction of the exposed portion, the length of the embedded portion being more than 3 times the normal thickness (up to 2 mm) of the cornea, as defined by Gelatt (6), and the stiffness of the dry plant material that was noted after its removal indicated complete penetration of the cornea. The unexpected absence of leakage of aqueous from the site of the foreign body entry could have been due to local changes (including swelling of the cornea) induced by the presence of the foreign material for an extended period. Relaxation of the ocular muscles due to effective Peterson block may also have been responsible for the temporary decrease in intraocular pressure. Delay in the return of complete tone in these muscles was perhaps sufficient for the seal to become firm.

Foreign body penetration into the anterior chamber has a guarded prognosis because of the high incidence of secondary endophthalmitis, particularly if the perforation was caused by plant material, as reported by Irby (1). Intensive topical and systemic antibiotics are thus critical. In the present case use of culture and sensitivity of the cornea prevented the development of infection.

In every corneal condition that presents with apparent pain, a mydriatic cycloplegic agent should be used, as reported by Williams et al. (2). The use of topical atropine and a preferred COX-2 inhibitor (Meloxicam) parenterally in the present case made the animal more comfortable and she therefore did not resist repeated topical treatments.

References

1. Irby, N.L.: Surgical diseases of the eye in farm animals. In: Fubini, S.L., Ducharme, N.G., Eds., *Farm Animal Surgery*. Saunders, New York, 2004; 429-468.
2. Williams, D.L., Barrie, K., Evans, T.F.: *Veterinary Ocular Emergency*. 1st edn., Butterworth/Heinemann, New Delhi, 2002; 6, 60-62.
3. Rebhun, W.C.: *Diseases of Dairy Cattle*. 1st edn., Williams and Wilkins, Philadelphia, 1995; 455-457.
4. Lavach, J.D.: *Large Animal Ophthalmology*. 1st edn., vol. 1, The C.V. Mosby Co. Philadelphia. 1990; 320-322.
5. Pearce, S.G., Kerr, C.L., Bouré, L.P., Thompson, K., Dobson, H.: Comparison of the retrobulbar and Peterson nerve block techniques via magnetic resonance imaging in bovine cadavers. *J. Am. Vet. Med. Assoc.*, 2003; 223: 852-855.
6. Gelatt, K.N.: *Veterinary Ophthalmology*. 3rd edn., Lippincott Williams and Wilkins, London, 1999; 46.