

1-1-2010

## Bilateral abscesses of the maxillary carnassial teeth in a female Pekinese

ABUTORAB TABATABAEI NAEINI

ALIREZA RAYAT JAHROMI

SAMIRA MEHRSHAD

Follow this and additional works at: <https://journals.tubitak.gov.tr/veterinary>



Part of the [Animal Sciences Commons](#), and the [Veterinary Medicine Commons](#)

---

### Recommended Citation

NAEINI, ABUTORAB TABATABAEI; JAHROMI, ALIREZA RAYAT; and MEHRSHAD, SAMIRA (2010) "Bilateral abscesses of the maxillary carnassial teeth in a female Pekinese," *Turkish Journal of Veterinary & Animal Sciences*: Vol. 34: No. 5, Article 7. <https://doi.org/10.3906/vet-0903-20>  
Available at: <https://journals.tubitak.gov.tr/veterinary/vol34/iss5/7>

This Article is brought to you for free and open access by TÜBİTAK Academic Journals. It has been accepted for inclusion in Turkish Journal of Veterinary & Animal Sciences by an authorized editor of TÜBİTAK Academic Journals. For more information, please contact [academic.publications@tubitak.gov.tr](mailto:academic.publications@tubitak.gov.tr).

## Bilateral abscesses of the maxillary carnassial teeth in a female Pekinese

Abutorab Tabatabaei NAEINI<sup>1</sup>, Alireza Raayat JAHROMI<sup>1,\*</sup>, Samira MEHRSHAD<sup>2</sup>

<sup>1</sup>Department of Clinical Sciences, School of Veterinary Medicine, Shiraz University, Shiraz - IRAN

<sup>2</sup>Student of Veterinary Medicine, School of Veterinary Medicine, Shiraz University, Shiraz - IRAN

Received: 12.03.2009

**Abstract:** Tooth infections are typically seen in older dogs as a result of poor oral hygiene (periodontal disease) or traumatic tooth fractures (endodontic and periapical disease). An 8-year-old female Pekinese was presented due to bilateral draining tracts located just under its eyes, and a history of healing and recurrence of the lesions after about 3 weeks of systemic antibiotic therapy. Dental radiography revealed bilateral carnassial tooth root abscesses. Both teeth were extracted under general anesthesia. With proper postoperative care the abscesses healed with no further complications.

**Key words:** Carnassial tooth, abscess, dog

### Introduction

The mandibular first molar and the maxillary fourth premolar are also referred to as the carnassial teeth. The maxillary fourth premolar in the dog is a massive 3-rooted tooth with long roots. This tooth, together with the mandibular first molar, is used to break up or crush hard material, such as bones or large pieces of meat. The roots extend from below the gingival margin up into the maxilla, ventro-latero-rostral to the eyes. There are 2 mesial roots (mesiobuccal and mesiopalatal roots) in the front portion of the tooth and 1 distal root in the rear. In the lateral view the crown of the tooth is triangular and has a sharp pointed main cusp. Chewing on very hard materials can cause buccal crown fractures of the maxillary carnassial teeth and lingual crown fractures of the mandibular carnassial teeth (1).

Tooth root abscesses are often deep seated, affecting the area surrounding the tooth root (periapical tissues). A tooth root abscess may be the result of periodontal disease, tooth fracture, or a retained root following tooth extraction (2). Carnassial tooth root abscesses are caused by bacteria that gain access to the root, either through a deep periodontal pocket, via the pulp cavity of a fractured tooth, or by being carried there by the bloodstream. Bacterial infection and the reaction of the host's white blood cells will cause abscess formation and alveolar bone destruction around the root tip. Over time the infection can travel through the bone of the upper jaw and break out either on the oral mucosa over the tooth or on the skin under the eye. Left untreated this opening will occasionally close, but then reopen again as more material accumulates. Dog owners often

\* E-mail: raayat@shirazu.ac.ir

confuse this condition with an eye infection, insect bite, or puncture wound. In dogs that stay outdoors or in those with long hair it may remain unnoticed for a long period of time.

### Case history

An 8-year-old female Pekinese was presented due to bilateral draining tracts located just under its eyes, which had been treated with local anti-inflammatory ointment and systemic antibiotic for about 3 weeks prior to presentation. The lesions sealed temporarily, but they returned once medical treatment was discontinued. Dark swollen spots with small draining wounds were located on the skin just beneath the eyes (Figure 1). It was apparent that the discharge originated from some structure ventral to the eyes and was traveling up under the skin and below the lower eyelids. Clinical examination revealed normal heart rate, respiratory rate, and rectal temperature. The dog's general condition, appetite, CRT (capillary refill time), and hydration status were also normal, with no signs of systemic sepsis. Oral examination revealed that the teeth were not loose or painful on palpation, and no sign of periodontal diseases was observed. Carnassial tooth root abscesses were suspected. Dental radiography was performed to determine the source of the abscesses and the extent of tissue damage. It was confirmed that both maxillary fourth premolar teeth had radiolucent periapical lesions around their roots (Figure 2). The dog was



Figure 2. Bilateral draining tracts are present just beneath the eyes.

premedicated with acepromazine (0.05 mg/kg) intramuscularly, and anesthesia was induced with intravenous ketamine (10 mg/kg) and diazepam (0.05 mg/kg). The dog was intubated, and anesthesia was maintained with halothane and oxygen. After creation of mucoperiosteal flaps around the affected teeth, tooth sectioning, partial alveolectomy, and loosening, the teeth were extracted without leaving of any tooth portions in the jaw. Butorphanol (0.3 mg/kg) was administered intravenously for postoperative pain control, and cefazolin (20 mg/kg PO TID) was continued for 2 weeks postoperatively. The dog was fed only soft food for 1 week following surgery. The abscesses beneath the eyes healed gradually, and the 6-month follow-up examination revealed complete healing with no further complications (Figure 3).

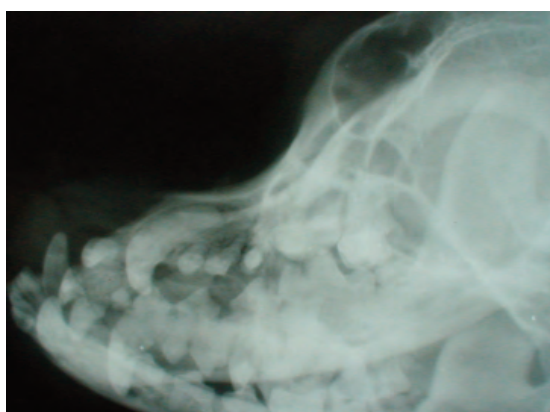


Figure 1. A distinct area of radiolucency with loss of lamina dura is present surrounding the root apices of one of the maxillary fourth premolar teeth, indicating alveolar bone lysis and formation of a tooth root abscess.

### Results and discussion

No surgeon should omit a clinical and radiological dental examination in the investigation of atypical facial, oral, or cranial pain (3). Dental problems often may not manifest themselves in conspicuous ways (4). Chronic weight loss and malnutrition may have various dental origins (5). The clinical signs of abscessed teeth may range from unilateral swelling of the mandible or maxilla on the affected side to draining tracts in the oral mucosa or skin (6). Progression of a carnassial tooth root abscess can cause the bone around it to dissolve, and a draining tract will eventually develop below the eye, as was observed in the present case. A crown fracture with



Figure 3. The dog 6 months following extraction of the maxillary fourth premolar teeth.

pulp exposure allows oral bacteria to migrate from the tooth fracture site into the pulp tissue, and then through the apical foramina of the root apex into the alveolar bone and deeper bony structures. Usually, the abscess breaks through the skin just below the medial canthus of the eye (7). This is often the time that endodontic disease is observed by the owner, as most dogs and cats do not show any outward signs of disease. Endodontic and periapical disease can be treated either by root canal therapy or tooth extraction.

In the present case root canal therapy was advised, but the owner declined for financial reasons. Root canal therapy can be rather expensive, but it does save the tooth. Unfortunately, the involvement of teeth in facial abscesses is often overlooked or ignored. Draining the abscess and use of systemic antibiotics will often resolve the external clinical signs, but the abscess will recur after discontinuation of antibiotics; therefore, the treatment of choice in the present case was to remove the involved teeth.

It should be noted that bilateral carnassial tooth root abscesses in dogs are unusual, which can make

establishing a diagnosis difficult. A thorough medical and dental history is required, and oral, facial, and systemic examinations are warranted. Together with radiographic findings and knowledge of the anatomical structures involved, carnassial tooth root abscess can be suspected. Dental radiographs will lead to a correct diagnosis (8). The most common origin of a facial draining tract is tooth related, and full-mouth dental radiography is necessary to identify which tooth is diseased and to confirm which tooth needs to be treated (3).

Carnassial teeth are difficult to remove. Clinical signs of a tooth root abscess may continue if any root portions remain in the jaw. Multi-rooted teeth should be sectioned into single-rooted crown-root segments, which are then extracted like single-rooted teeth. Sectioning can be achieved using fissure burs in dental handpieces. Accurate positioning of the cuts requires proper knowledge of tooth morphology. Creation of mucoperiosteal flaps and partial removal of alveolar bone will ease the extraction process (9).

The systemic consequences of dental disease are likely to be greater in geriatric patients (4). Similar signs as those observed in the present case, and a history of mild conjunctivitis and mucopurulent discharge from the right eye were previously reported in a 5-year-old dog (8). That dog had had slight blepharitis about 4 years earlier, which had been treated with an antibiotic ophthalmic ointment only. After dental radiography was performed a unilateral carnassial tooth root abscess was confirmed, and tooth extraction corrected the problem. Draining tracts associated with both mandibular first molar teeth and periapical bone lysis were reported in a 6-year-old dog in which open tooth extractions were performed to solve the problem (10).

Severe oral inflammation/infection and oral surgical procedures are associated with a high level of pain. The proper analgesic varies, depending on the anticipated level of discomfort (11,12). Postoperative care includes pain control, soft food for about 2 weeks, and possible use of antibiotics (depending on the character and extent of disease). In the present case no complications were seen 6 months following tooth extraction.

## References

1. Eisner, E.R.: Professional and home dental care of the adult dog and cat. Recent advances in dental health management. In: *Proceedings of the 8th World Veterinary Dental Congress*, Kyoto, Japan. 2003; 8-15.
2. Kealy, J.K., McAllister, H.: *Diagnostic Radiology and Ultrasonography of the dog and cat*. 3<sup>rd</sup> edn., WB Saunders Company, Philadelphia. 2000; 364-365.
3. Hopkins, R.: Some dental problems and the surgeon. *Ann. R. Coll. Surg. Engl.*, 1973; 53: 95-111.
4. Rostami, A., Dehghan, M.M., Masoudifard, M., Memarian, I., Shahi Ferdous, M.M.: The report of periapical abscess in carnassial tooth in an eurasian lynx (*Lynx lynx*). *Wildlife Middle East News*, 2007; 2: ISSN 1990-8237.
5. Fowler, M.E.: *Zoo and Wild Animal Medicine*. WB Saunders Company, Pennsylvania. 1986; 533-547.
6. Wallach, J.D., Boever, W.J.: *Diseases of Exotic Animals. Medical and Surgical Management*. WB Saunders Company, Philadelphia. 1983; 380-382.
7. Bell, A.F.: Dental disease in the dog. *J. Small Anim. Pract.*, 1965; 6: 421-428.
8. Neuman, N.B.: Chronic ocular discharge associated with a carnassial tooth abscess. *Can. Vet. J.*, 1974; 15: 128.
9. Niemiec, B.A.: Extraction techniques. *Top. Companion Anim. Med.*, 2008; 23: 97-105.
10. Stein, K.E., Marretta, S.M., Eurell, J.A.: Dens invaginatus of the mandibular first molars in a dog. *J. Vet. Dent.*, 2005; 22: 21-25.
11. Rochette, J.: Local anesthetic nerve blocks and oral analgesia. In: *Proceedings of the World Small Animal Veterinary Association*, Vancouver, Canada, 2001; 2: 3.
12. Stegmann, G.F.: Regional nerve blocks for oral surgery. In: *Proceedings of the 10th World Veterinary Dental Congress*, Guarujá, SP. 2007; 73-74.